Minimally Invasive Corpectomy for Thoraco-Lumbar Burst Fractures

Adam S. Kanter, MD

12º Congresso de Cirurgia Espinhal
Sao Paolo, SP – March 2012

The Department of Neurological Surgery
at the University of Pittsburgh

Thor ractures

Traditional posterior approach or con

Goals of sur tion and correction deformity when

Anterior inst ce superior arthrodesis and ared to posterior instrumentation f the spinal canal and thus superio

However, tr gnificant morbidity, including pneum lumbar plexus, retrograde ejacu or diaphragmatic hernia.

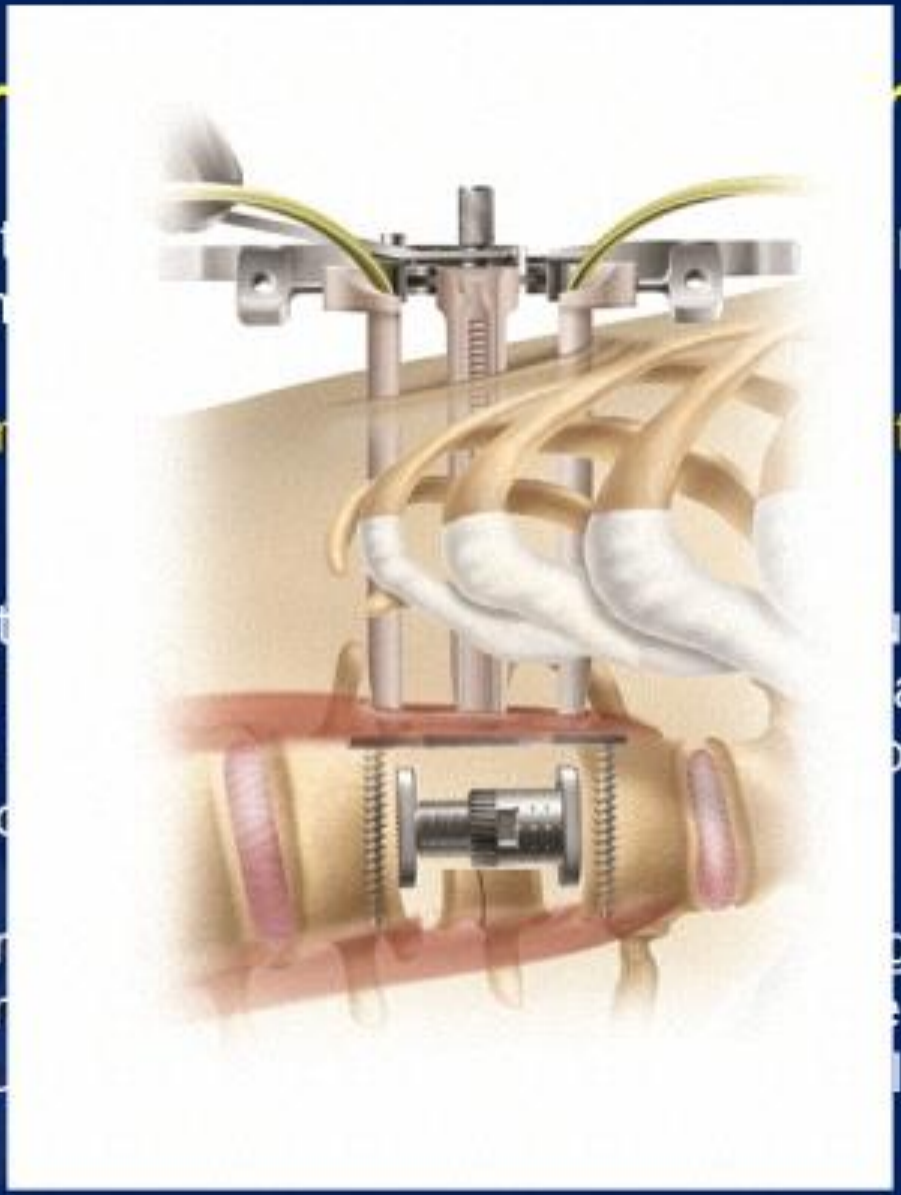

The Department of Neurological Surgery
at the University of Pittsburgh

Targeting Entry

Once positioned, use K-wire to mark skin incision

Mark rib location as well, plan to dissect along top of rib to avoid neurovascular bundle

The Department of Neurological Surgery
at the University of Pittsburgh

Incision



Parallel with ribs

Intrapleural access along top of inferior rib

The Department of Neurological Surgery
at the University of Pittsburgh

Confirm level with fluoro

The Department of Neurological Surgery
at the University of Pittsburgh

*standard retractor insertion

The Department of Neurological Surgery
at the University of Pittsburgh

Vertebrectomy

Perform complete discectomies above and below the fractured vertebrae, then core out the intervening bone

Do not attempt to remove burst fragments within the canal until you have created a vertebral void for them to fall into…

The Department of Neurological Surgery at the University of Pittsburgh

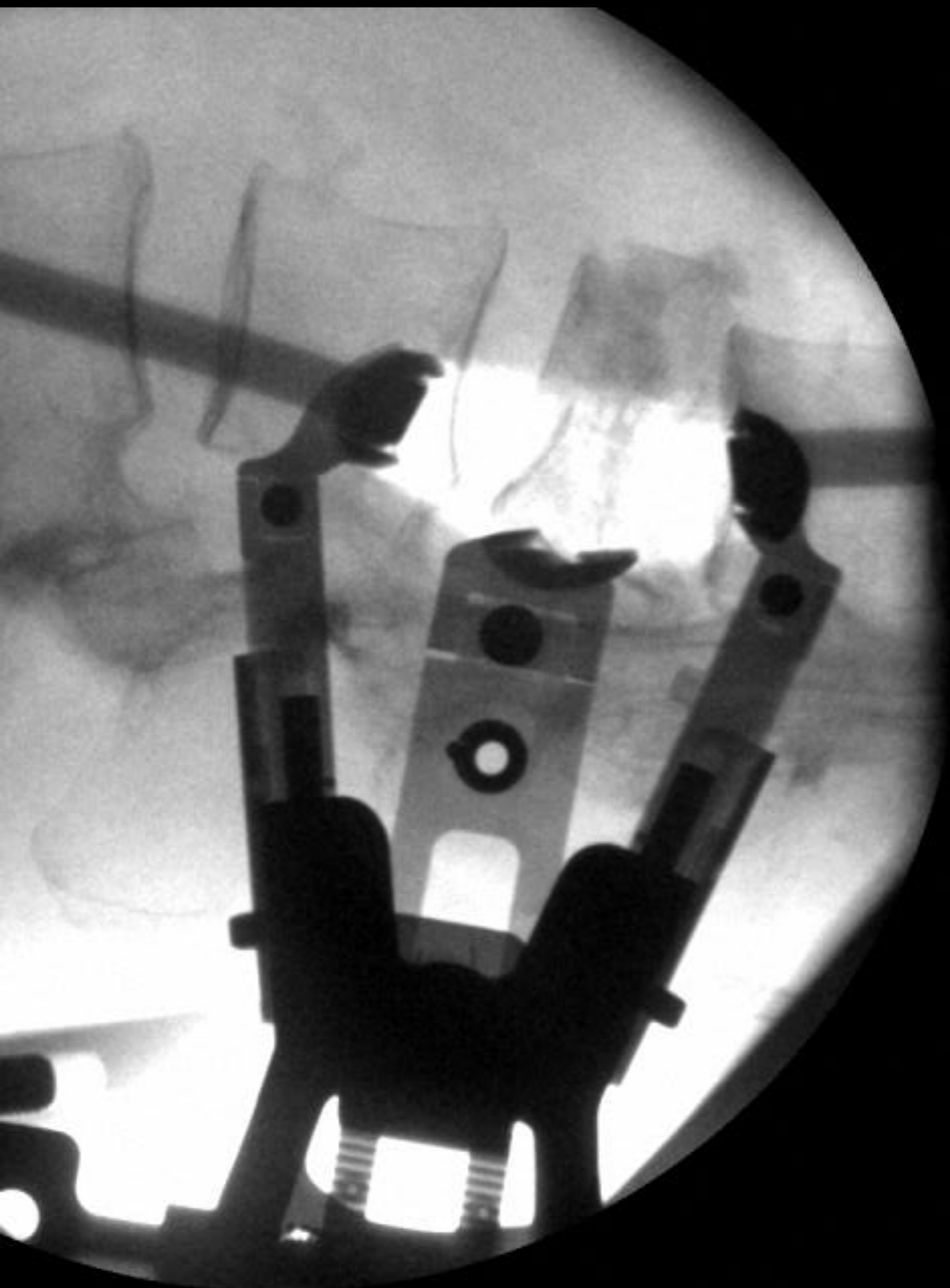

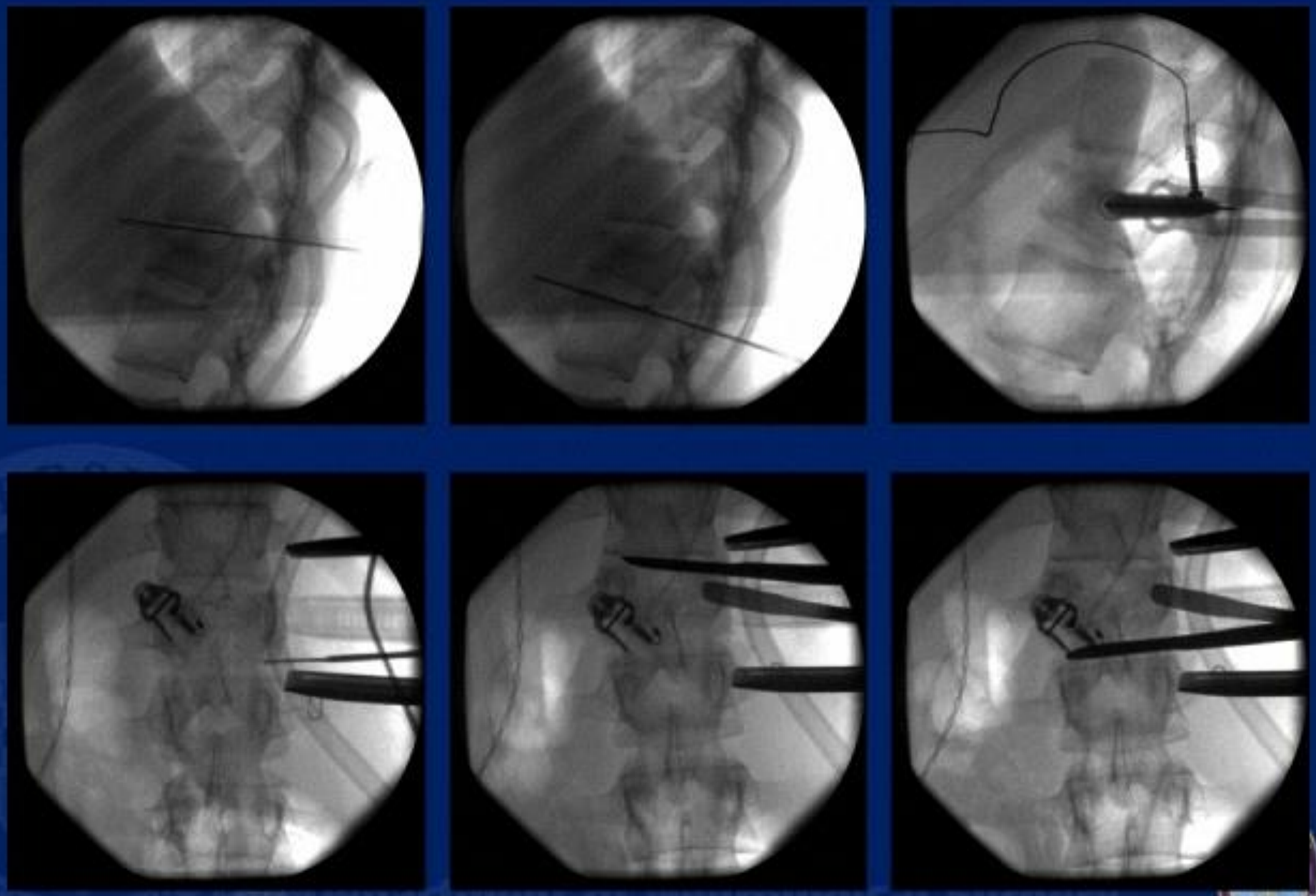

The Department of Neurological Surgery
at the University of Pittsburgh

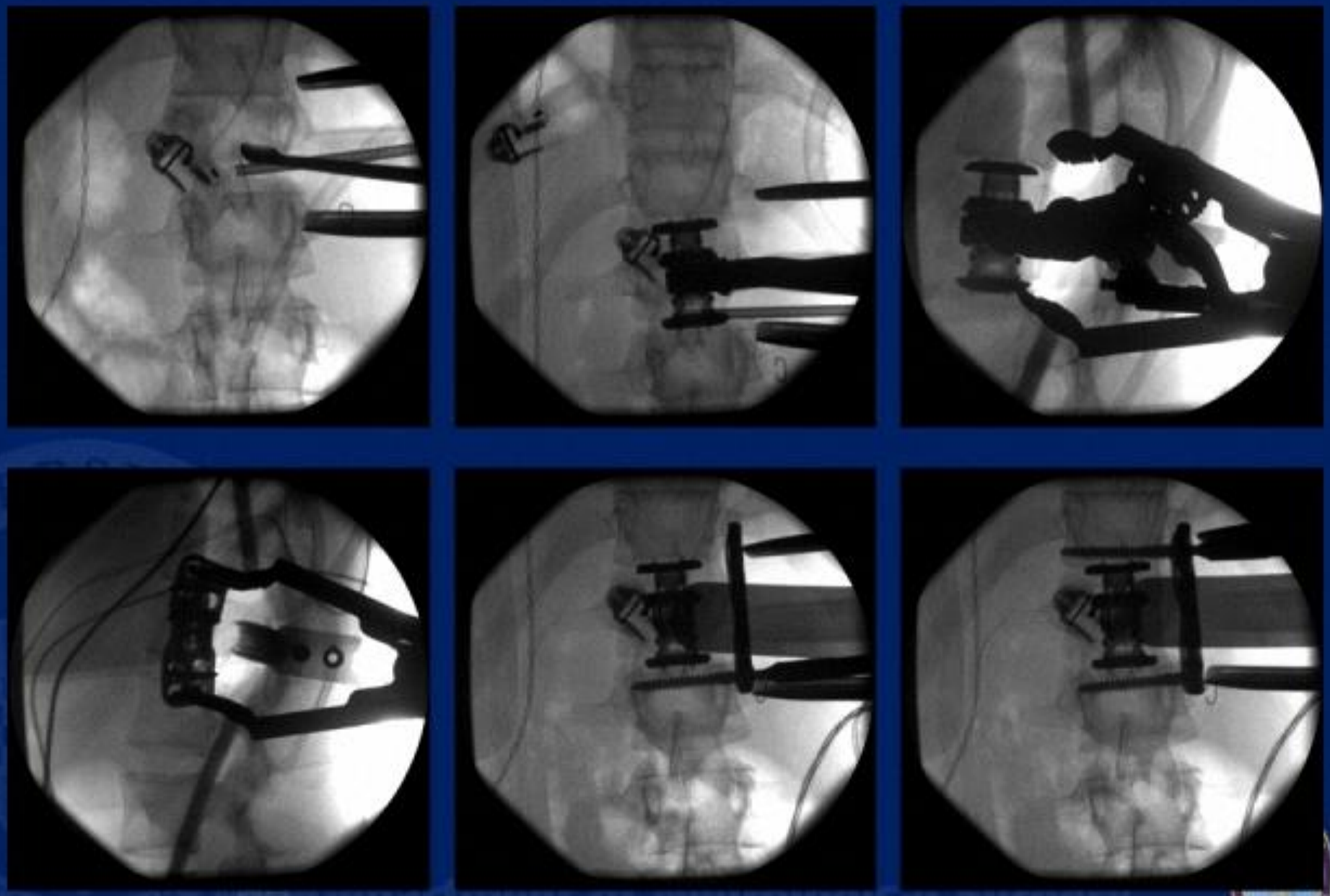

The Department of Neurological Surgery
at the University of Pittsburgh

Cosmesis

The Department of Neurological Surgery
at the University of Pittsburgh

18 month period (2009 – 2010)
MIS corpectomies for T/L burst fractures

- 10 male
- 7 female
- Mean age 53 (range 17-74)

Fracture levels

T12	(5)
L1	(9)
L2	(2)
L3	(1)

Variables of interest

- length of surgery
- estimated blood loss
- length of hospital stay
- disposition
- complications

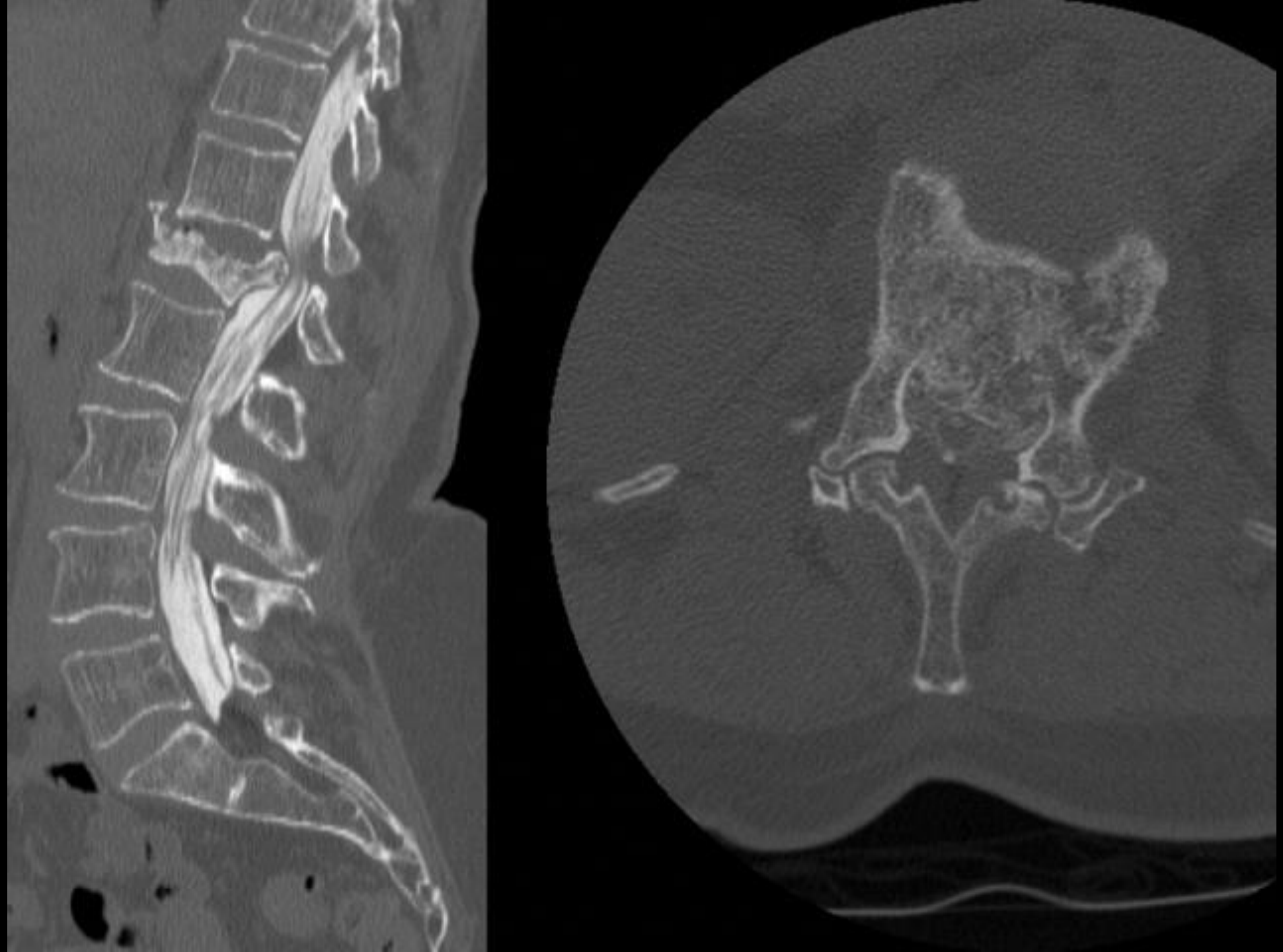

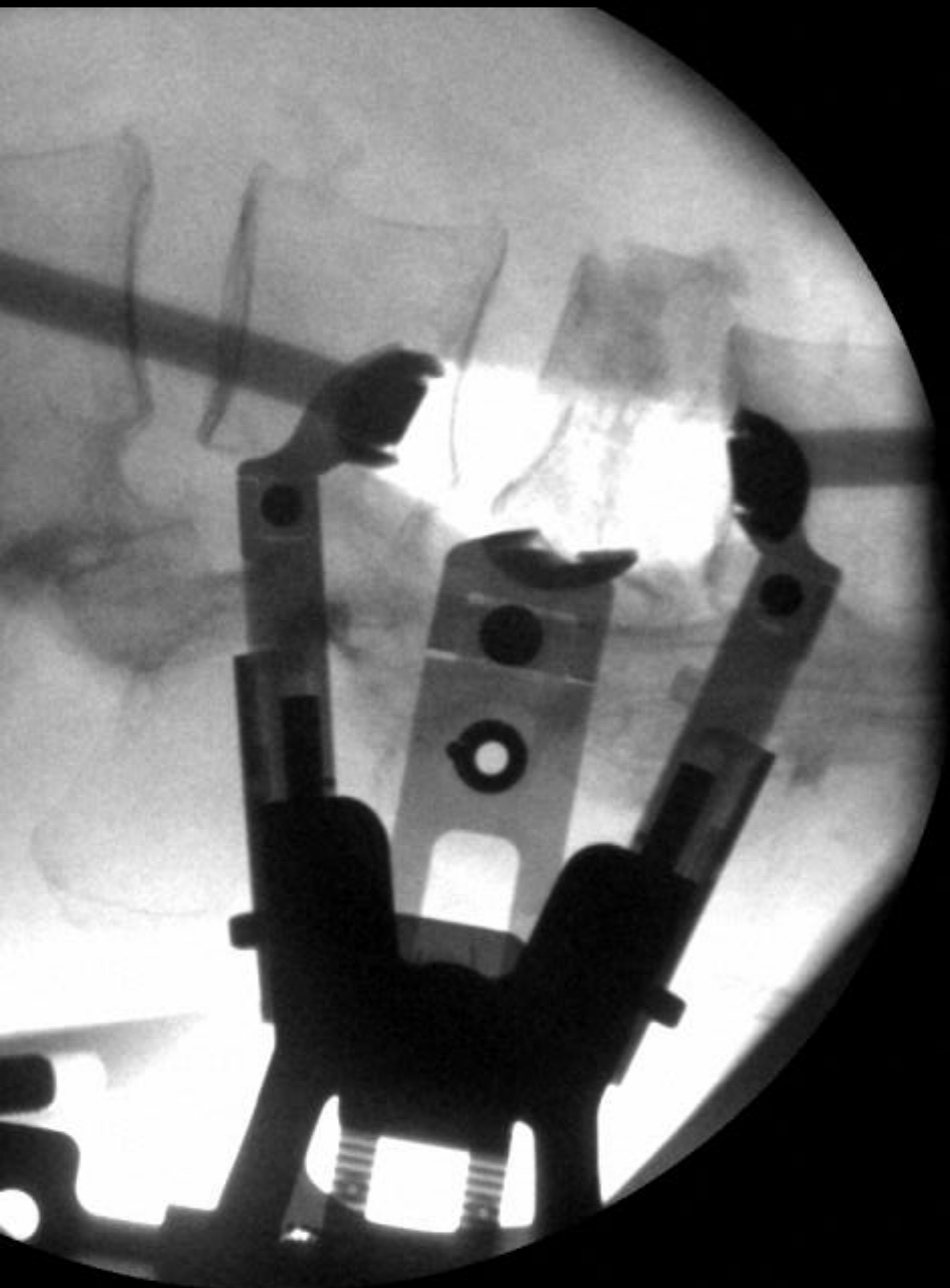



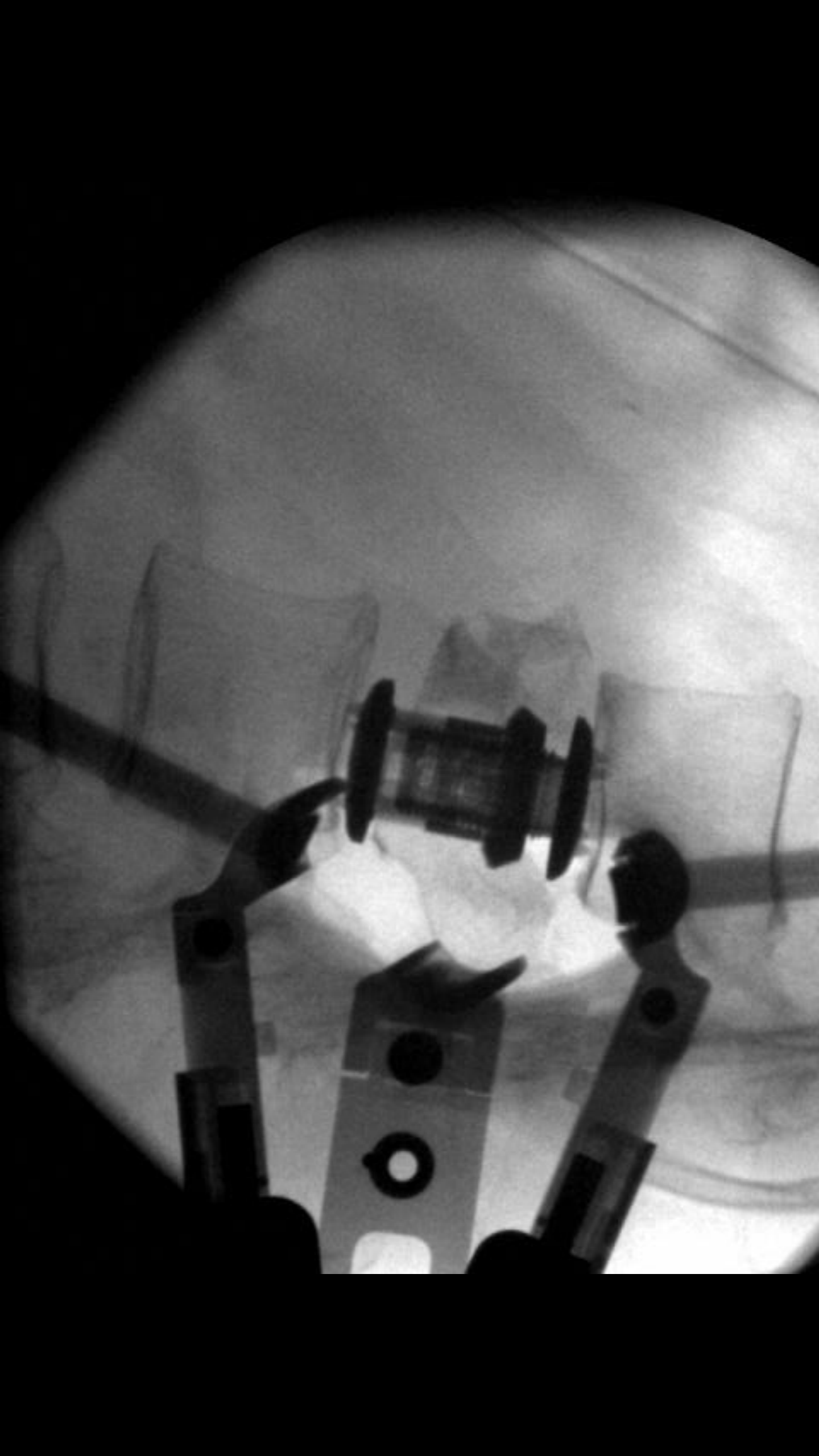

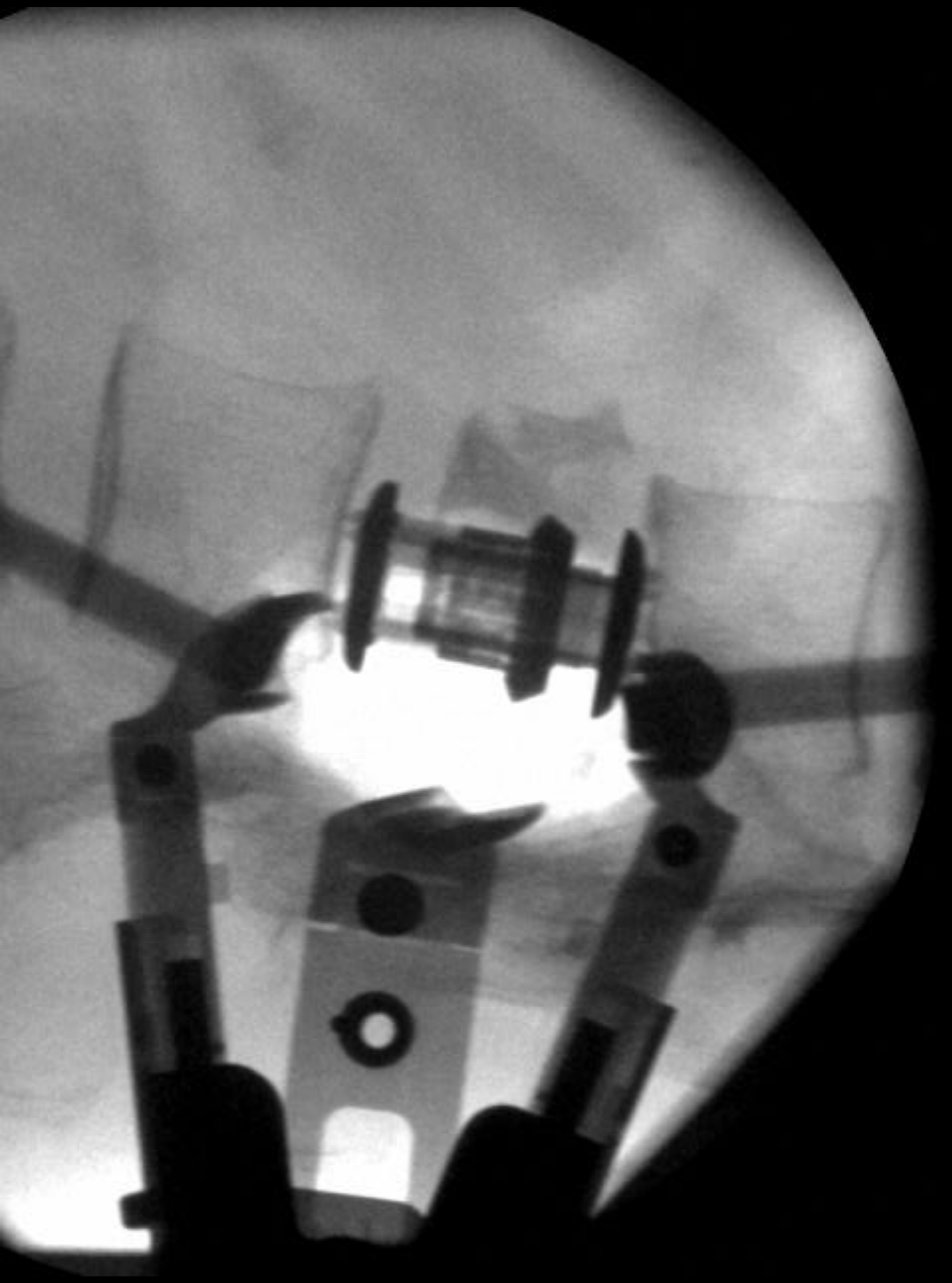

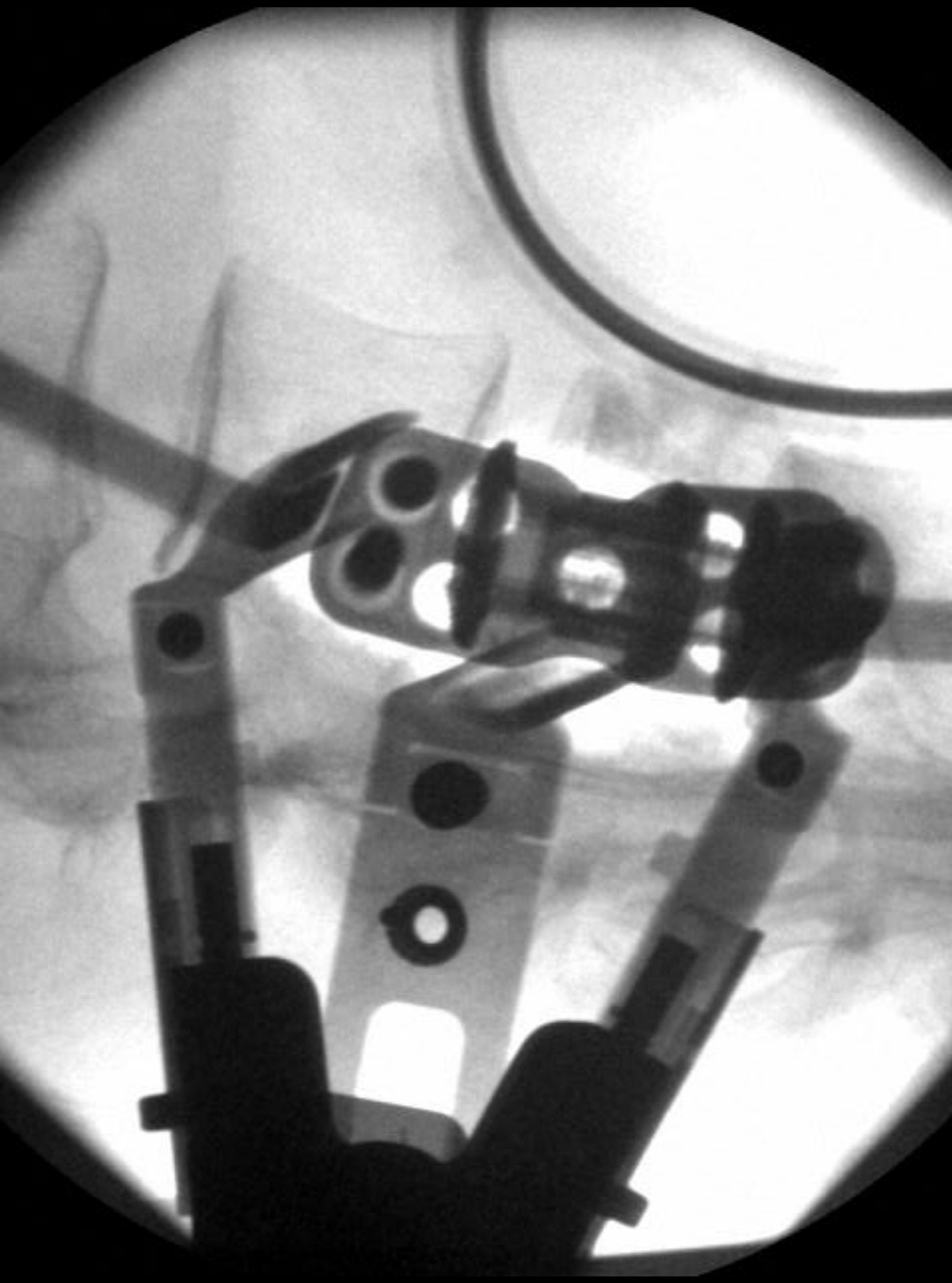

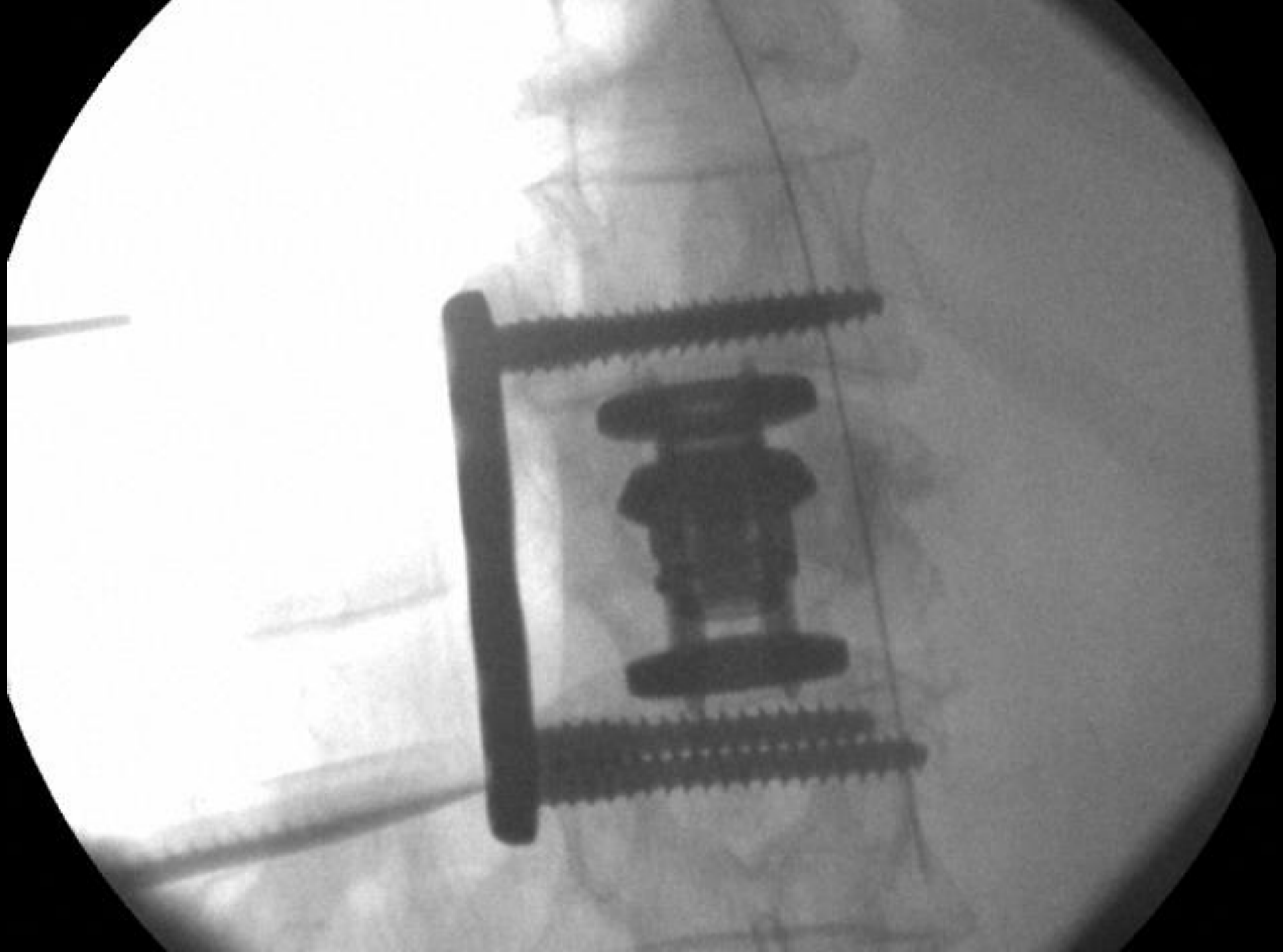

Emergent decompression and short construct fusion

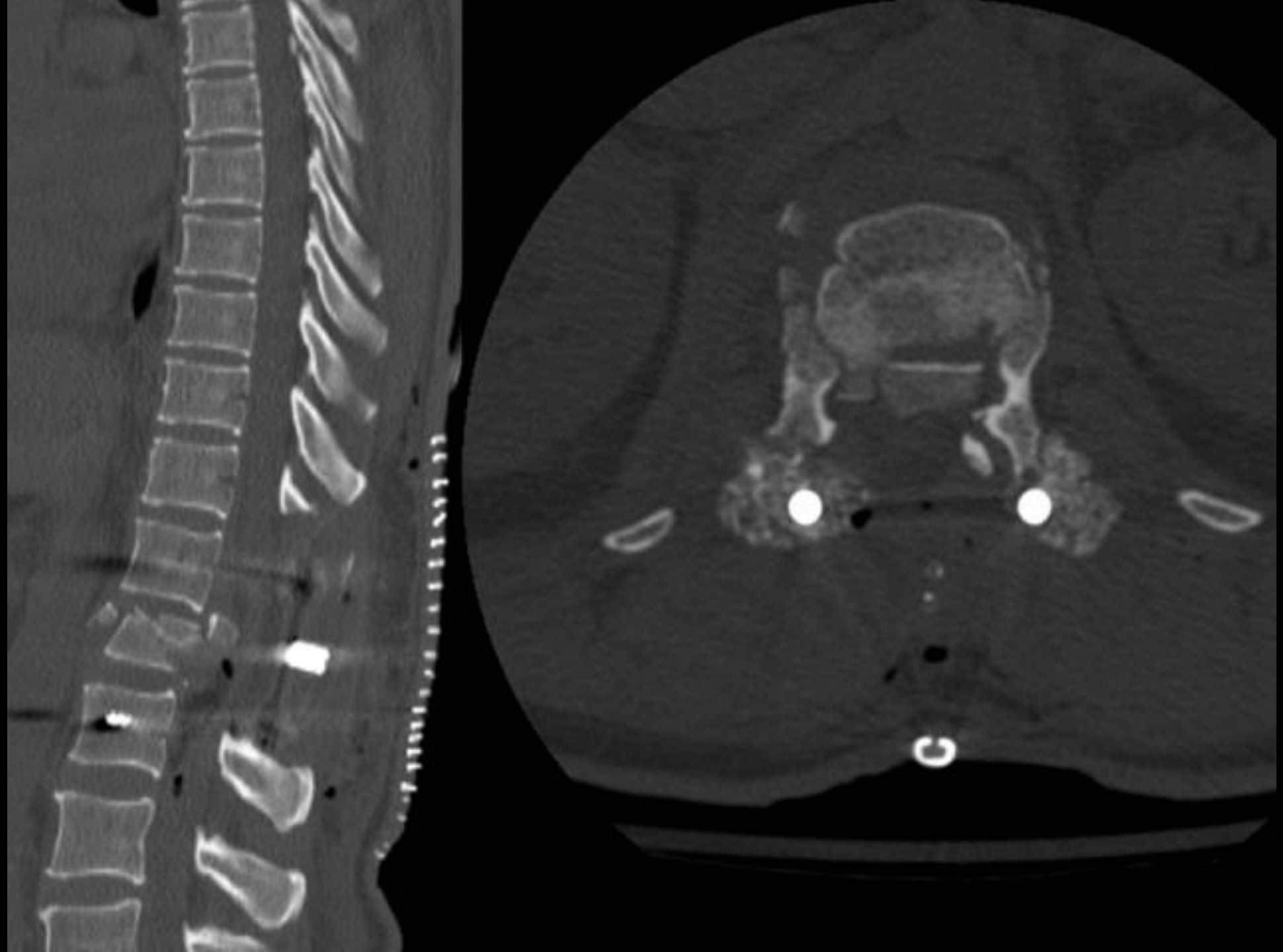

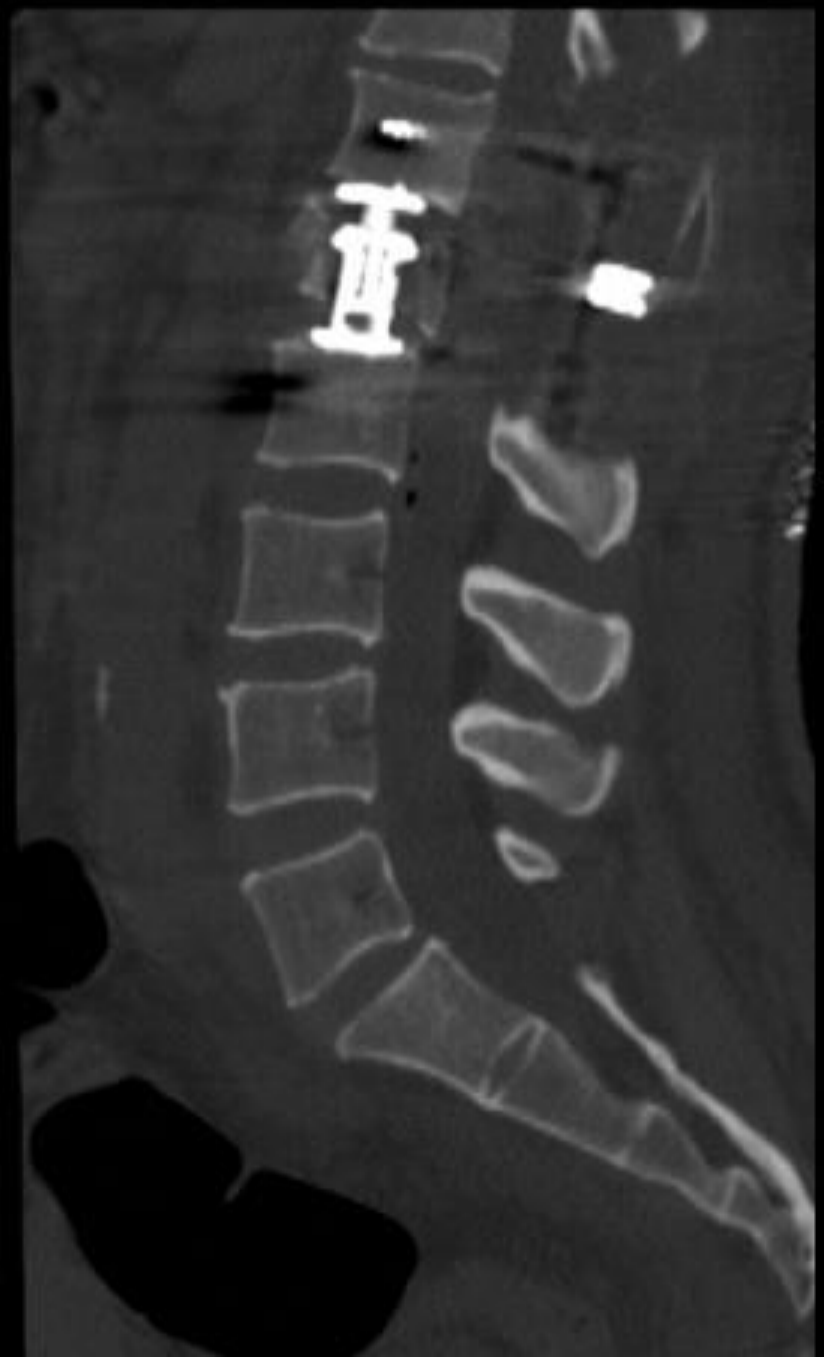

Asia E
Back to work

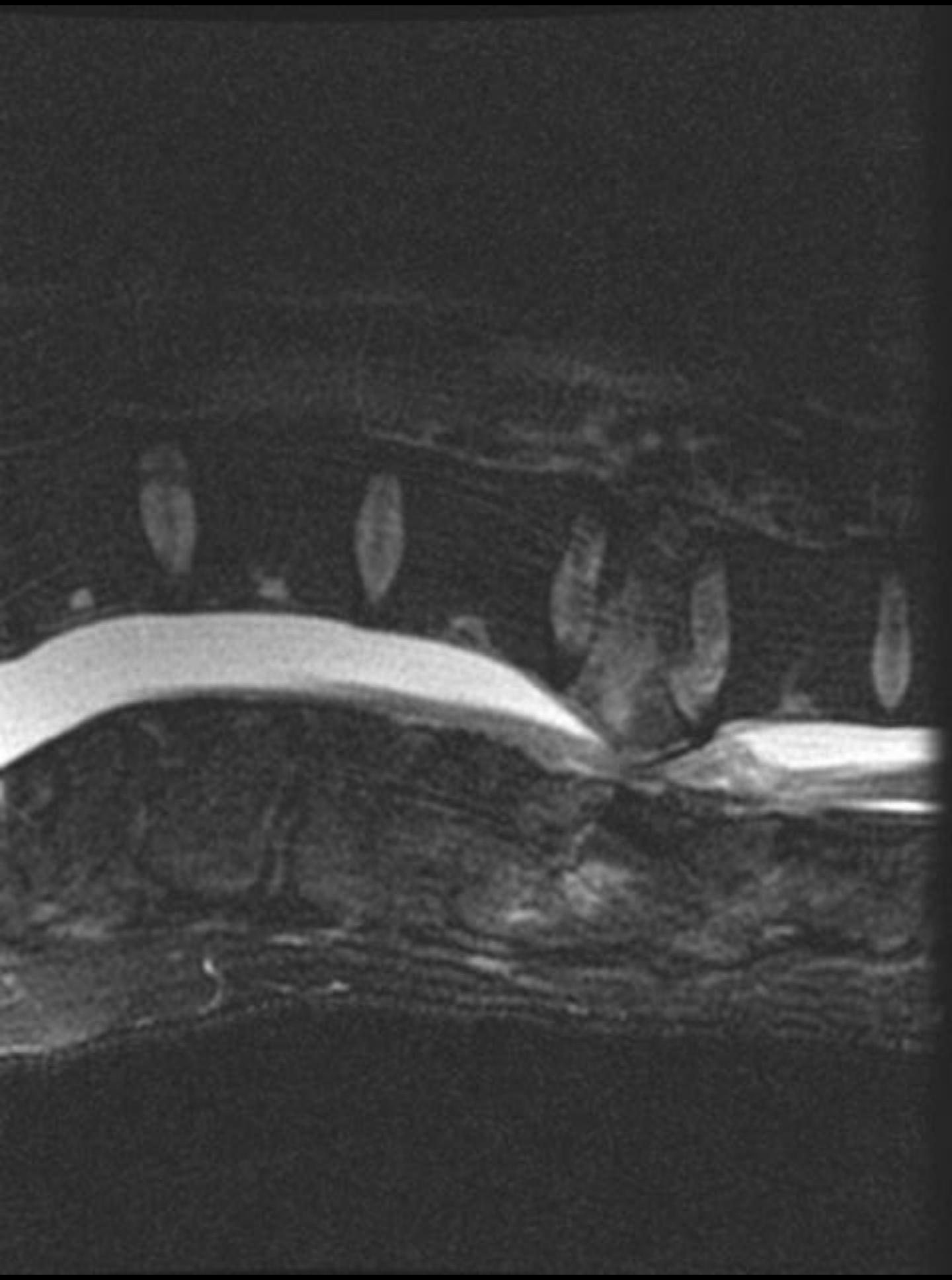

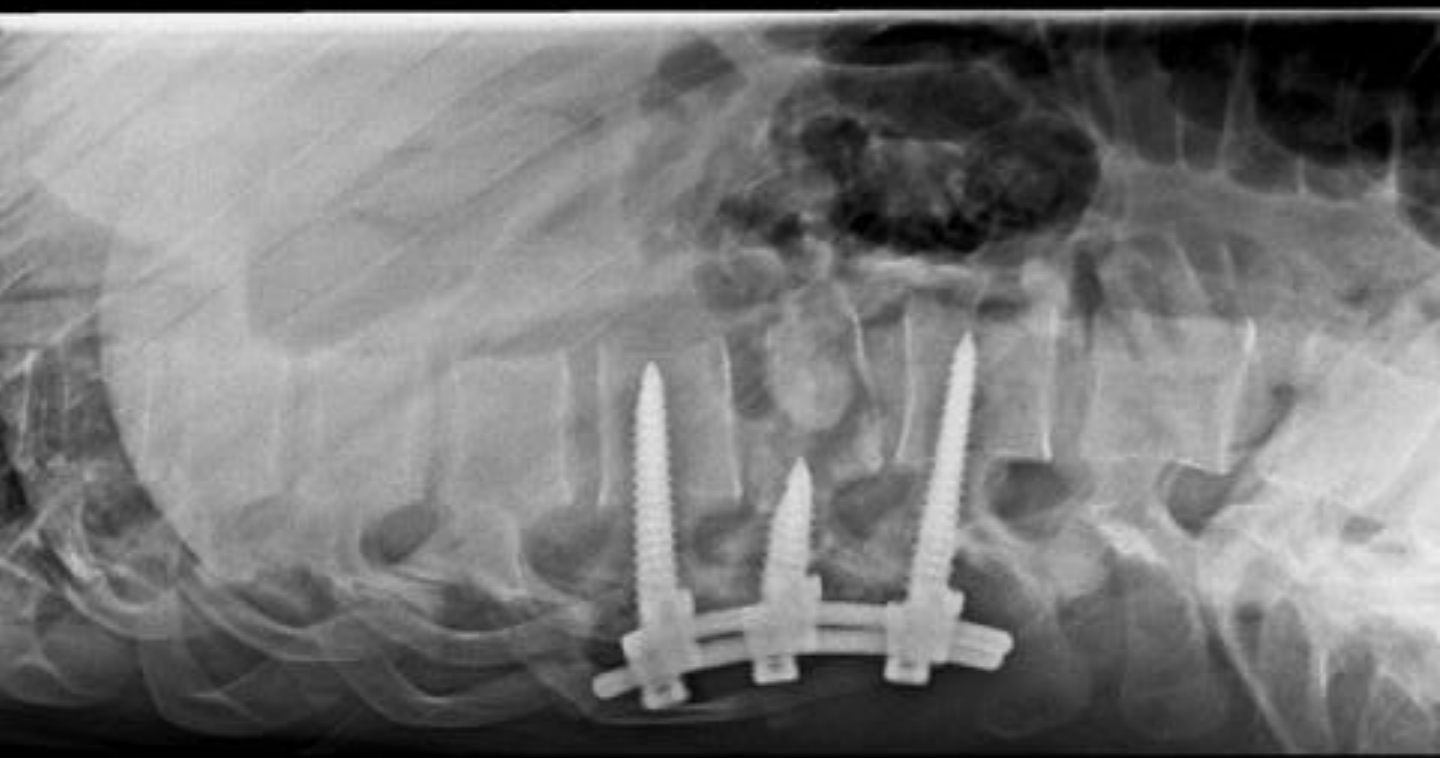

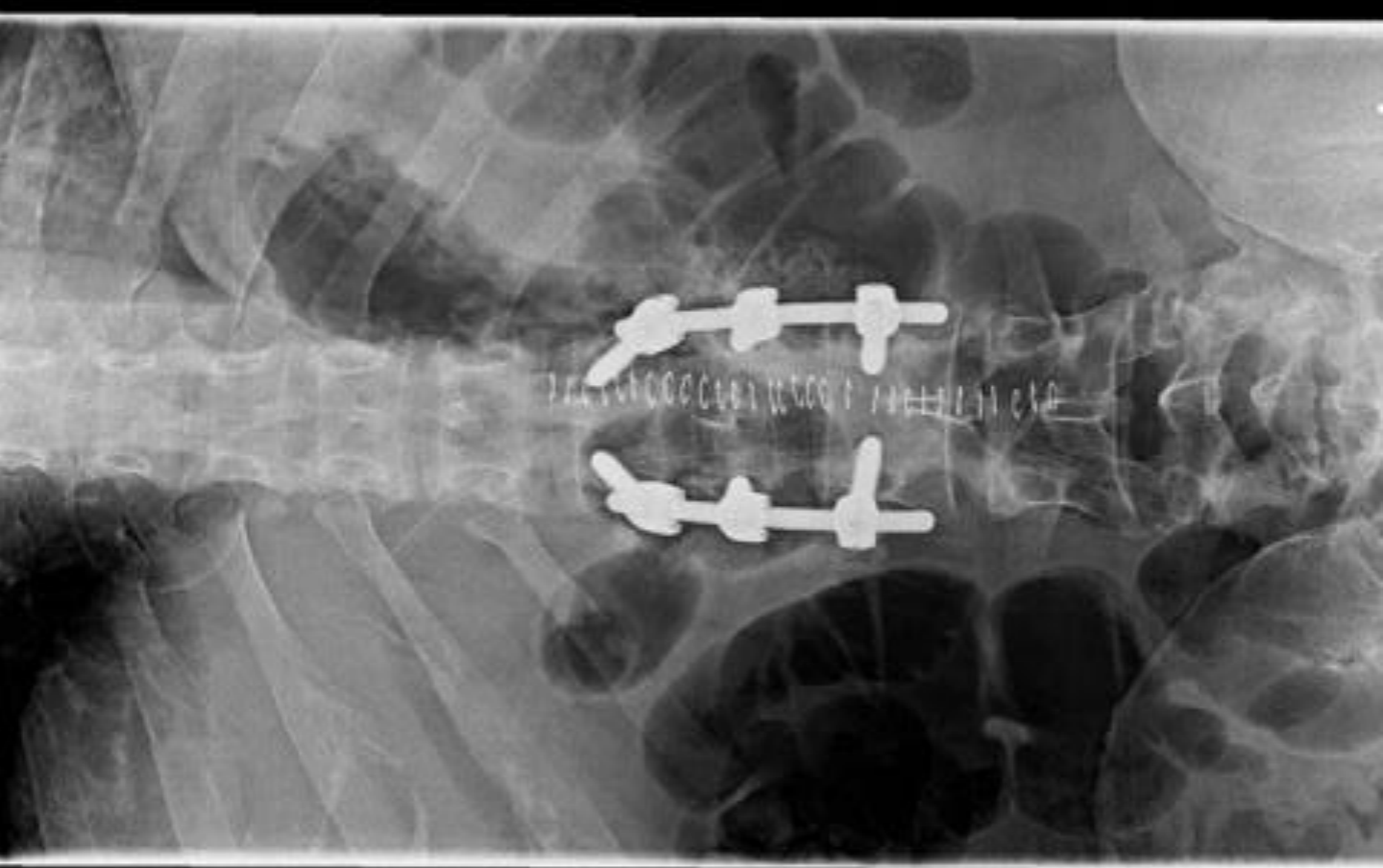

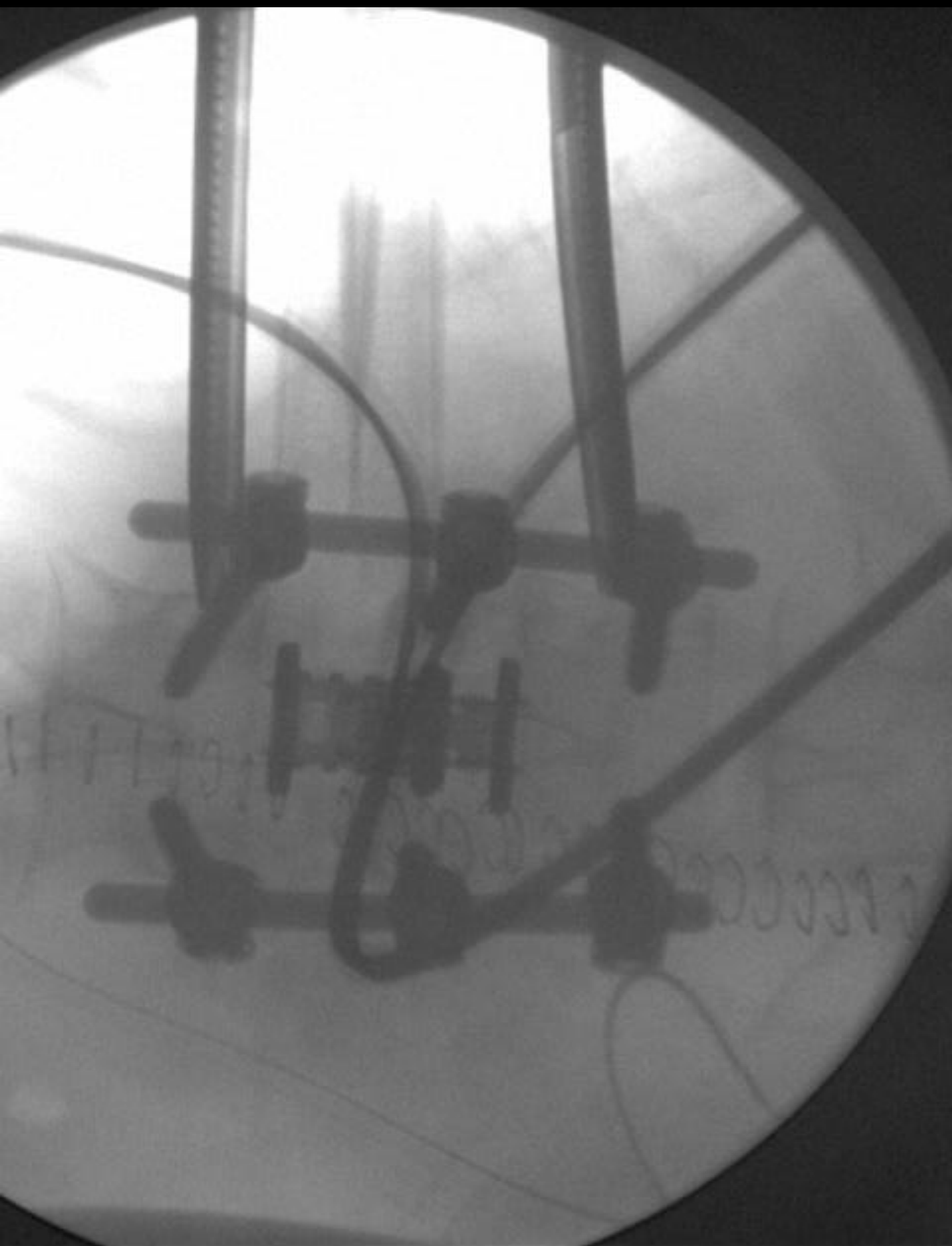

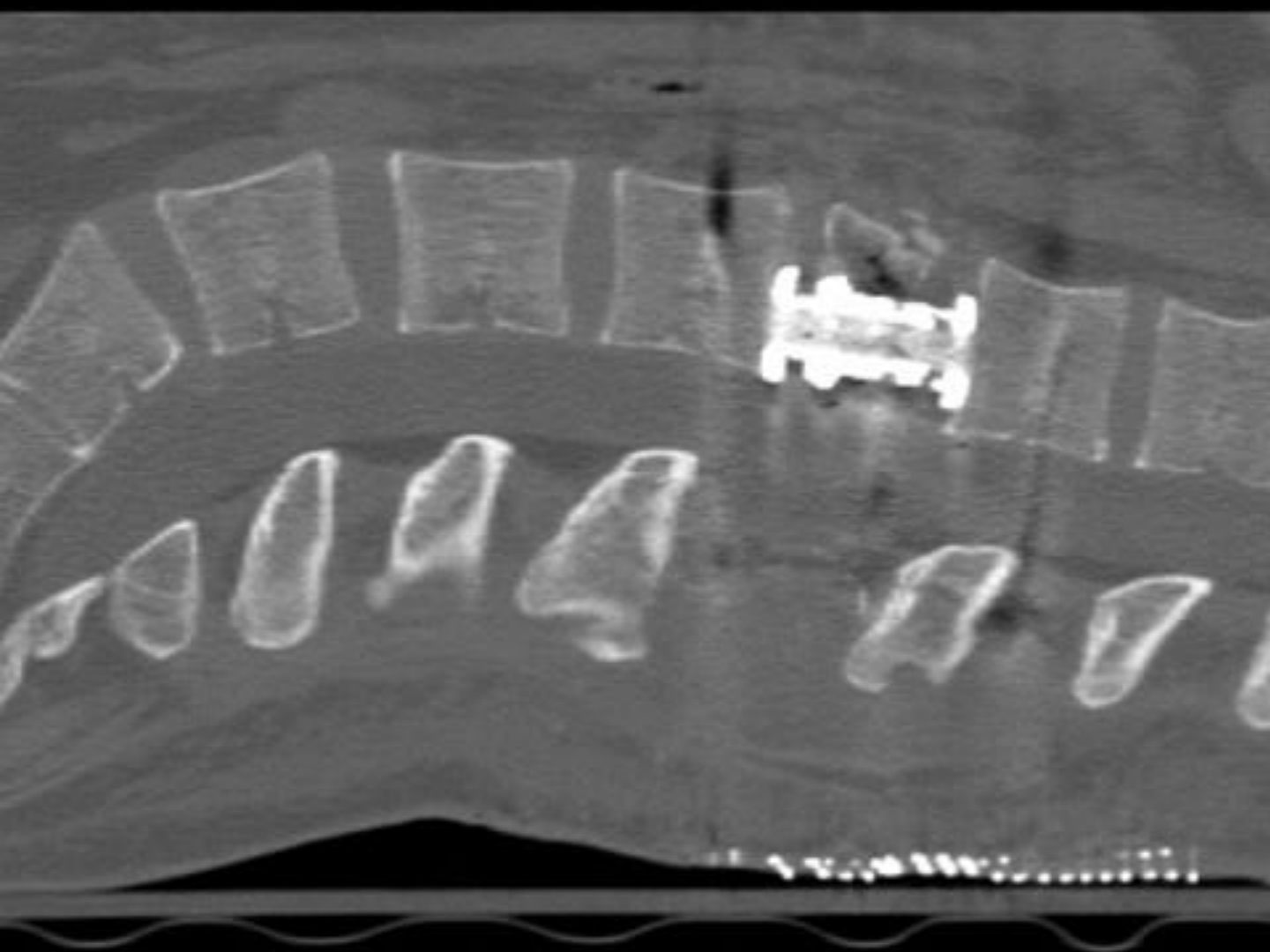

Results

Avg length of surgery	3.6 hrs
Avg blood loss	640 ml (range 220 – 2400ml),
Avg length of stay	4.6 days (range 2-12 days).

Complications

- Atrial fibrillation (1)
- Pleural effusion (1) – required pigtail placement
- Ipsilateral thigh weakness (12) – 100% resolved

Disposition

Rehab	5
Home	12

The Department of Neurological Surgery
at the University of Pittsburgh

Results

- All patients had either stable neurological status or improvement from their pre-operative condition

- Flex/ext & CT at follow-up (avg 12.5 months)
  - No patient had evidence of instability, hardware failure, or kyphosis
  - All patients demonstrated bridging bone

- Standardized clinical outcomes pending…

The Department of Neurological Surgery
at the University of Pittsburgh

Conclusion

The extreme lateral transpsoas approach is a safe and effective minimally invasive treatment option for the management of thoracolumbar burst fractures.

Further follow up and experience will be necessary to evaluate more thoroughly this technique…early results appear promising!

The Department of Neurological Surgery
at the University of Pittsburgh

Thank you!

12º Congresso de Cirurgia Espinhal
Sao Paolo, SP – March 2012

The Department of Neurological Surgery
at the University of Pittsburgh