cirurgiadacolunavertebral.com.br

Curso Pré-Congresso

Trauma Crâniocervical

Ricardo Botelho

Tópicos

- Fraturas do Côndilo Occiptal
- Deslocamento Atlanto-ocipital
- Deslocamento Atlanto-Axial
- Instabilidade Vertical
- Fraturas do Atlas
- Fraturas do Axis
  - Odontóide (Dente)
  - Corpo
- Alternativas de Estabilização

- **Ricardo Botelho**

cirurgiadacolunavertebral.com.br

Tópicos

- Hangmann (Fraturas do "enforcado)
- Roger Schmdt Brock


Traumas fatais
Pacientes intactos

cirurgiadacolunavertebral.com.br

1. Fraturas do Côndilo Occipital

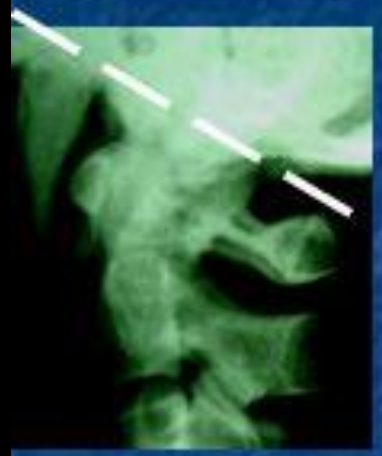

Anderson PA, Montesano PX: Morphology and treatment of occipital condyle fractures. *Spine* 1988;13:731-736.

1. Fraturas do Côndilo Occipital

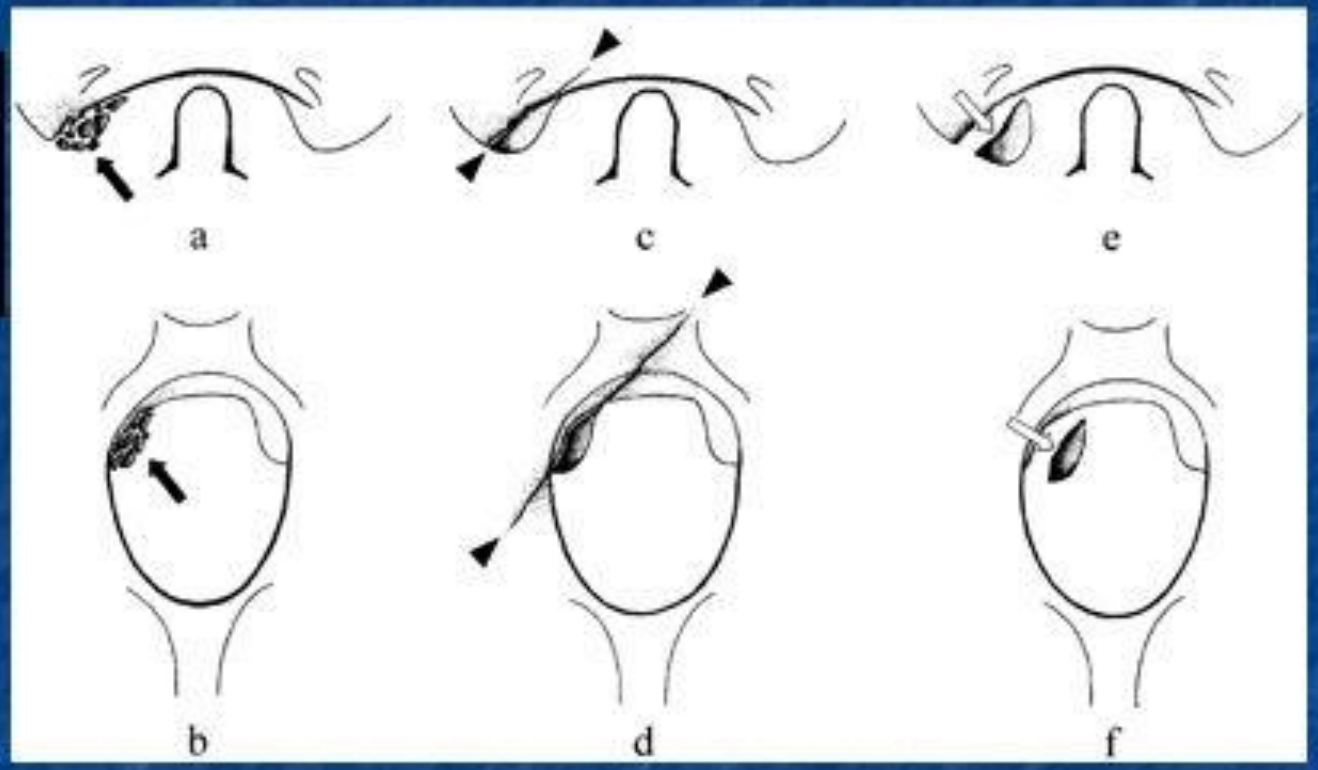

Anderson PA, Montesano PX: Morphology and treatment of occipital condyle fractures. *Spine* 1988;13:731-736.

I

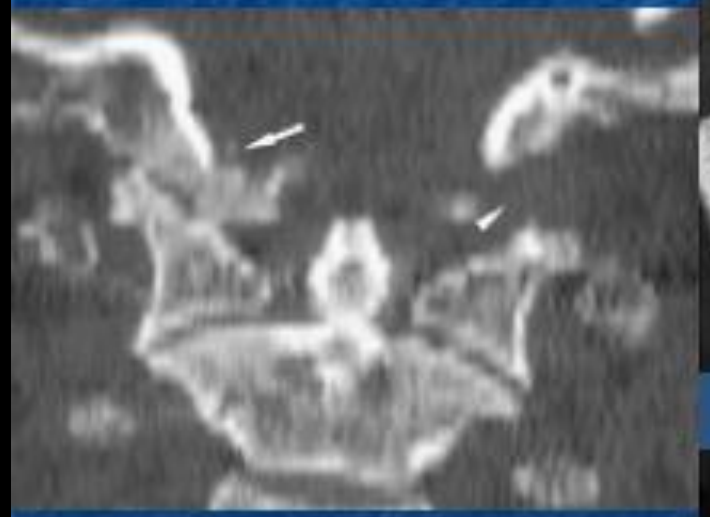

II

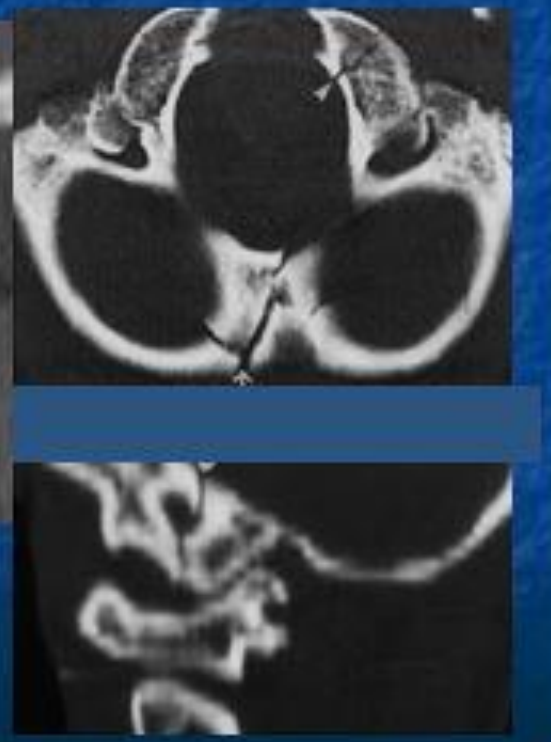

III

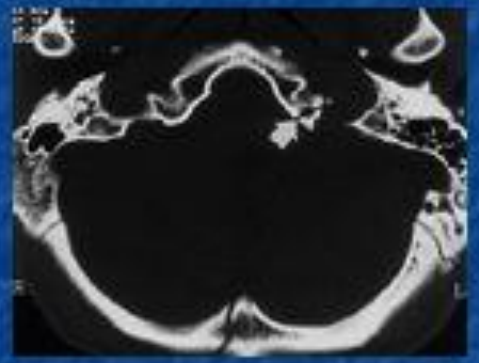

cirurgiadacolunavertebral.com.br

Conduta

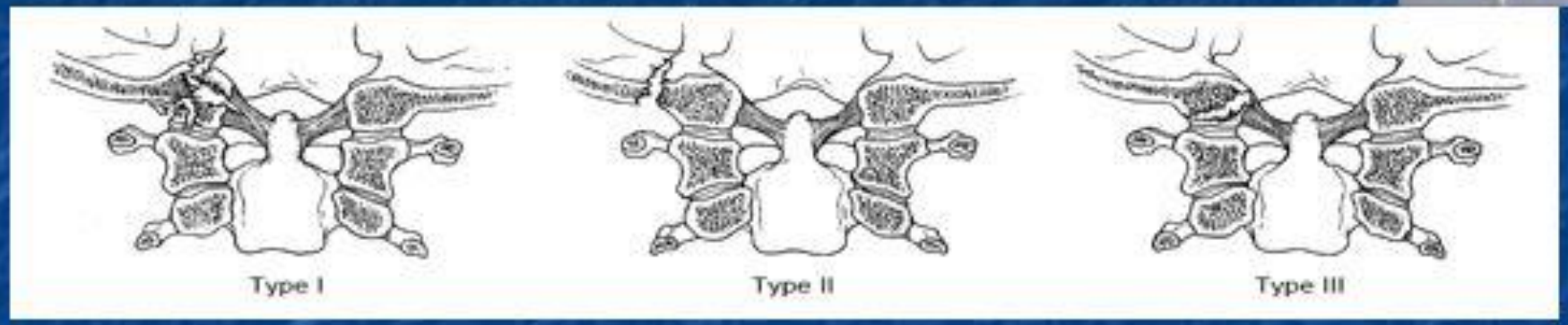

Impactação do Côndilo
Estável

Colar: 6-8 semanas

Fratura do Côndilo e
Rampa Basilar
Estável: colar 6-8 semanas

•*Côndilo separado Crânio
Halo: 6-8 semanas

Avulsão do Ligamento Alar
*Bilateral
30-50% Deslocamento Crânio
Cervical

Deslocamento:
Ausente: colar
Mínimo: Halo 6-8 sem
Qualquer movimentação
Evidente: fusão O-C2

2.Deslocamento Crânio-cervical

- Raro?
- 8 a 19% fatalidades

(Alker AJ. Orthop Cin North AM 1978)

Atlanto-Occipital Dislocation (Craniovertebral Dissociation)

Classification Based on Position of the Occiput in Relation to C1

Type I: Occipital condyles anterior to the atlas; most common
Type II: Condyles longitudinally result of pure distraction
Type III: Occipital condyles posterior to the atlas *


adac

Wholey 1958
10 mm

50%

Powers 1979
R>1

33%

Dublin 1980
13 mm
20 mm

25%

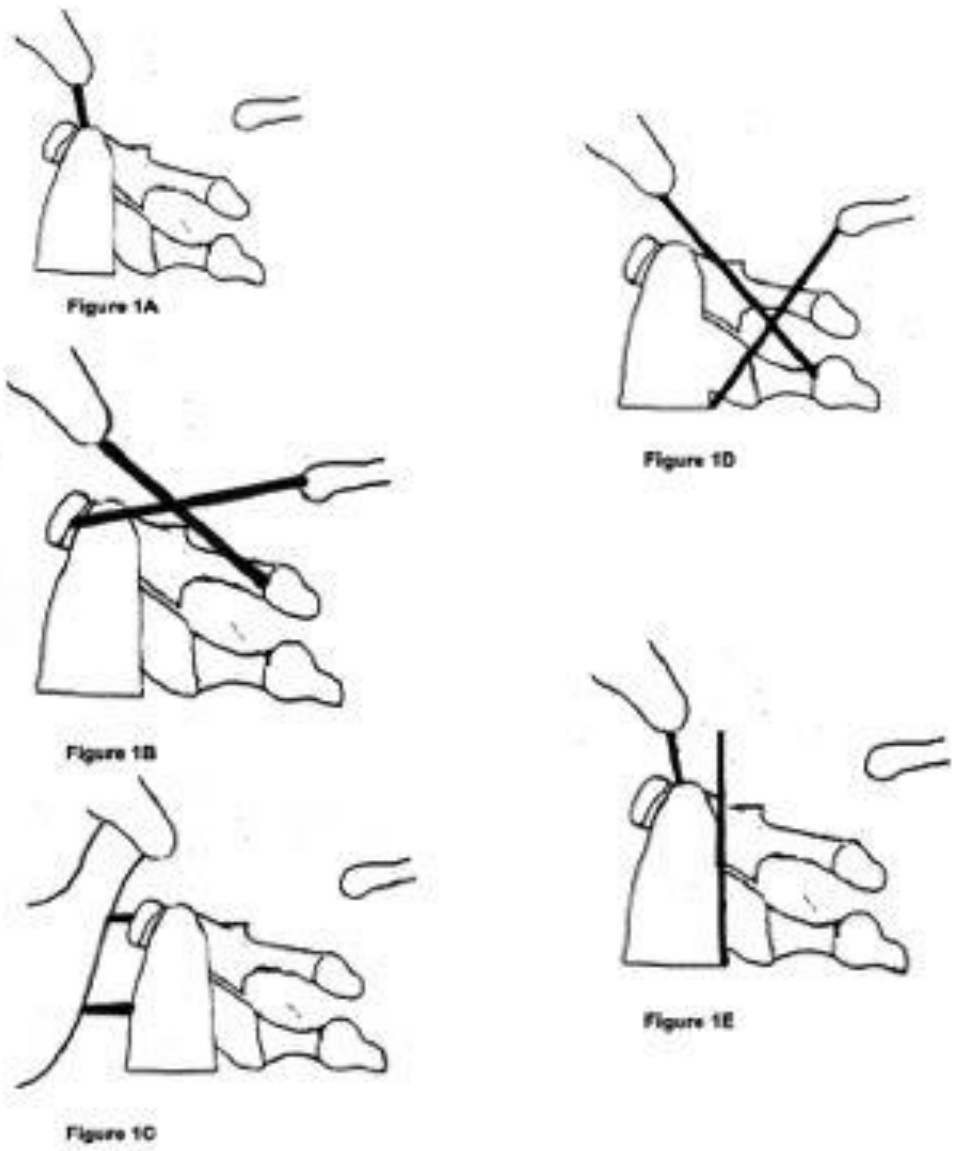

Lee 1987

75%

- RX: 0,57
- TC:0,84
- RM:0,86

Harris 1994
>12mm
<-4mm

100%

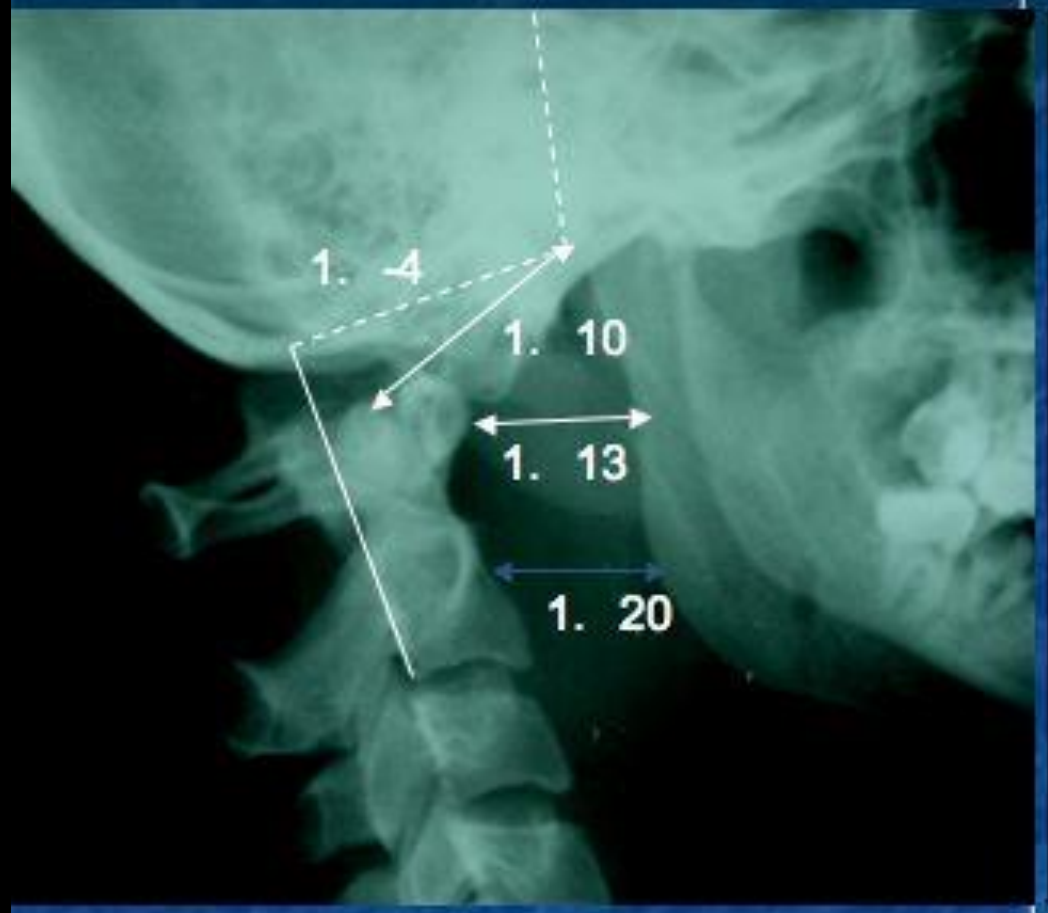

cirurgiadacolunavertebral.com.br

Conduta

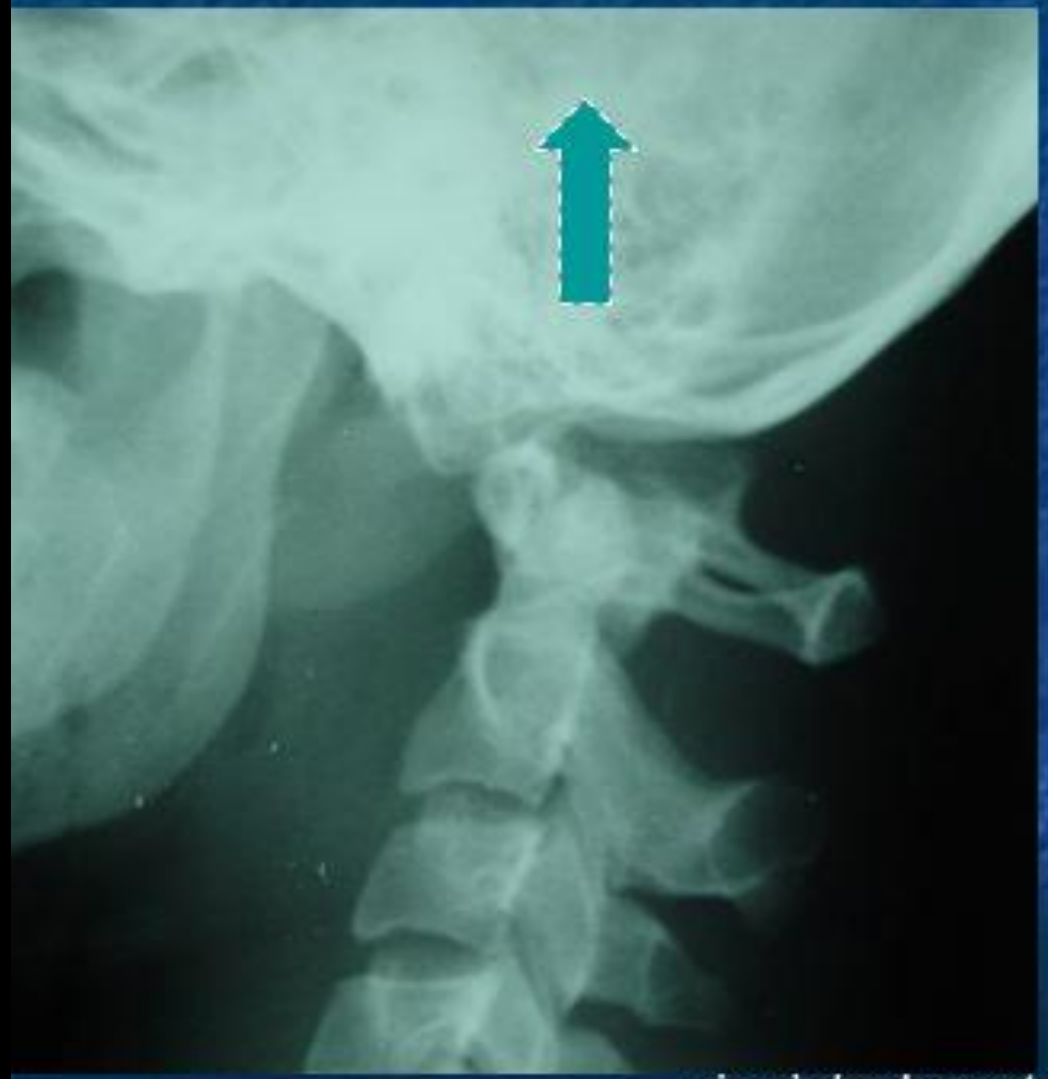

- Todos não tratados pioraram
- Tração piora: 10%
- "Usar com cuidado"

- Imobilização e artrodese: nenhum piorou

cirurgiadacolunavertebral.com.br

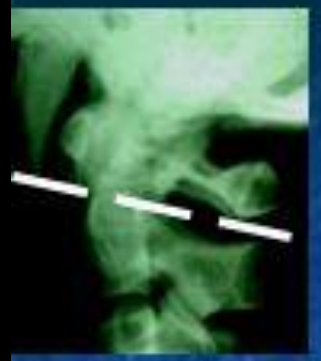

Deslocamento Atlanto-axial Rotatório Anterior

- Gravidade menor que o deslocamento Occipito-atlantal
- Traumas menores ou sem trauma evidente

Subluxação rotatória atlanto-axial

- Tipo 1: pequena rotação sem subluxação associada

Subluxação rotatória atlanto-axial

Tipo 2:

3 a 5 mm de deslocamento com uma massa lateral agindo como um pivô enquanto a outra roda anteriormente

Subluxação rotatória atlanto-axial

- Tipo 3:
  deslocamento de 5mm de ambas as massas laterais



Subluxação rotatória atlanto-axial

- Tipo 4 : rotação + deslocamento posterior

  * o tipo 2 e 3 estão associados com ligamento transverso incompetente e comprometimento neurológico

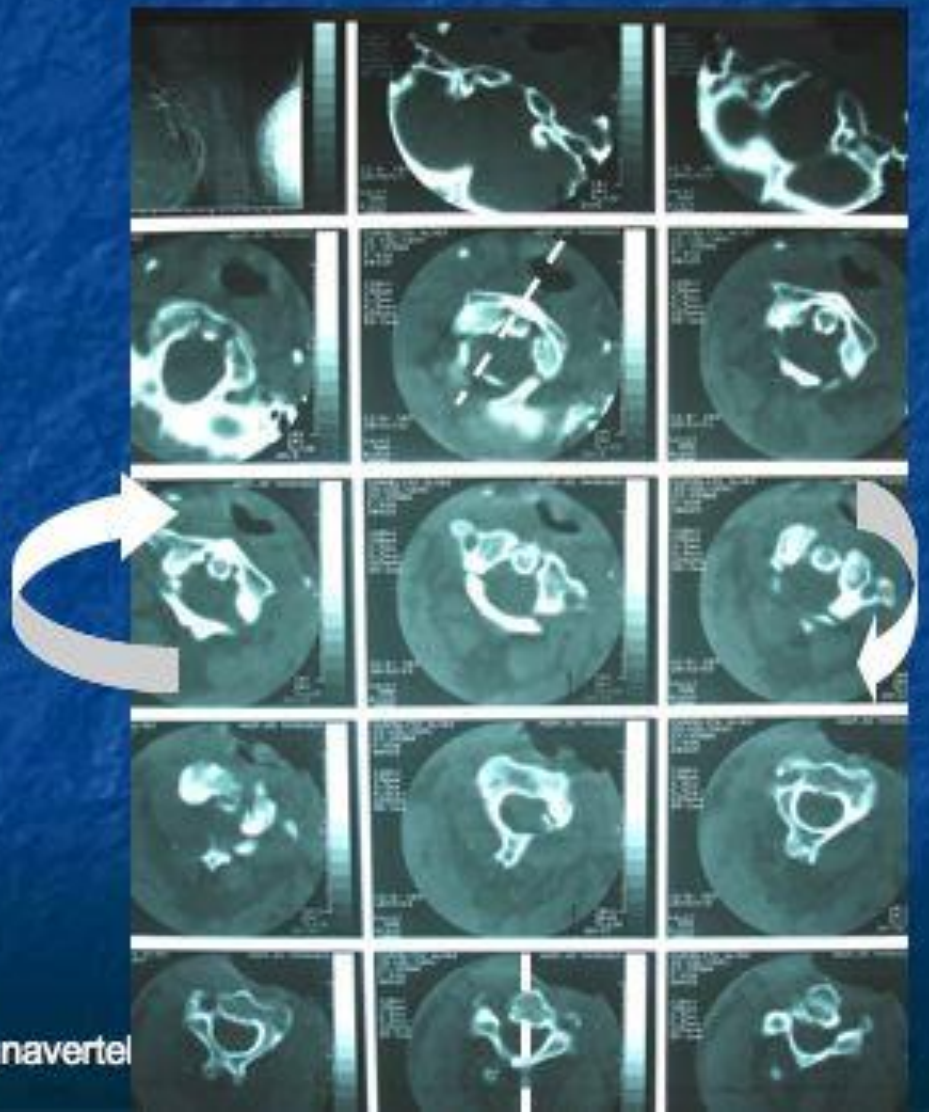

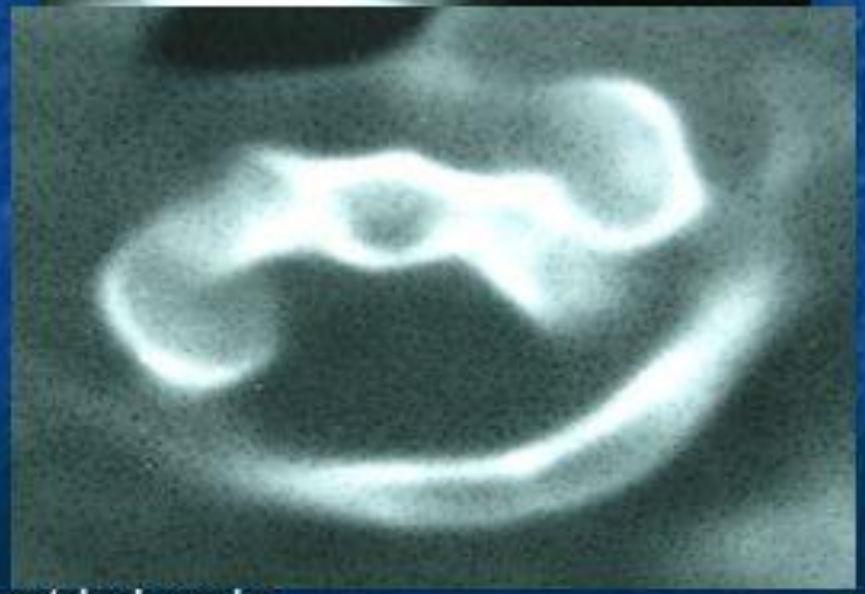

cirurgiadacolunavertebral.com.br

Arq Bras Neurocir 18(2): 109-114, 1999

Subluxação atlanto-axial traumática

Fixação com parafuso transarticular unilateral. Relato de caso

Ricardo Vieira Botelho[1,2,3], José Antônio Ribeiro[2], Emilio Afonso França Fontoura[3]

Serviço de Neurocirurgia do Hospital do Servidor Público do Município de São Paulo

Tratamento:

- Frequentemente não cirúrgico
- Tração (prolongada com uso de relaxantes)

Cirurgia:

1. lesões irredutíveis
2. recorrentes
3. lesões do LTA.

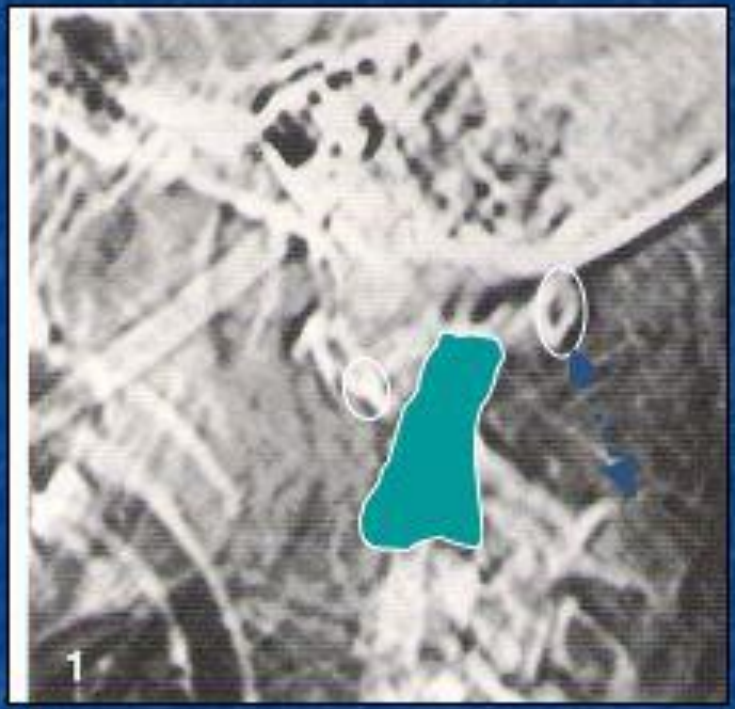
1


2
L

Tração ?

Eur Spine J (2000) 9:430–433

CASE REPORT

Ricardo Vieira Botelho
Adriana Maria de Souza Palma
Carla Maria Balieiro Abgussen
Emilio Afonso França Fontoura

Traumatic vertical atlantoaxial instability: the risk associated with skull traction. Case report and literature review

4.Deslocamento Atlanto-axial "Vertical"

J Neurosurg (Spine 1) 3:273–280, 2004

Vertical atlantoaxial distraction injuries: radiological criteria and clinical implications

L. Fernando Gonzalez, M.D., David Fiorella, M.D., Ph.D., Neil R. Crawford, Ph.D., Robert C. Wallace, M.D., Iman Feiz-Erfan, M.D., Denise Drumm, Ph.D., Stephen M. Papadopoulos, M.D., and Volker K. H. Sonntag, M.D.

Divisions of Neurological Surgery and Neuroradiology, Barrow Neurological Institute, St. Joseph's Hospital and Medical Center, Phoenix; and Scottsdale Healthcare, Scottsdale, Arizona

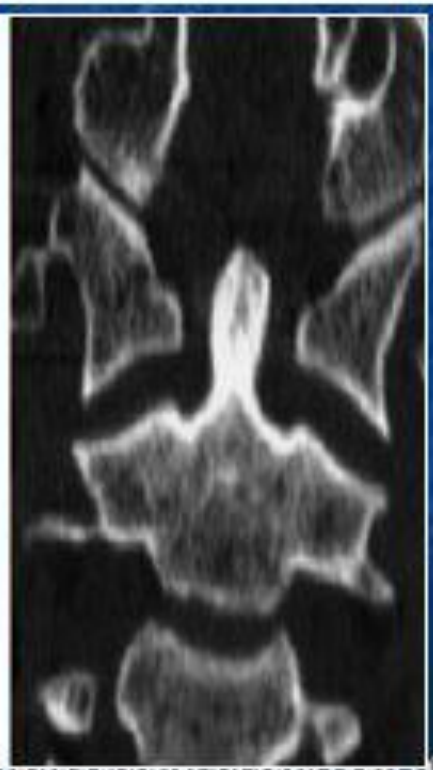

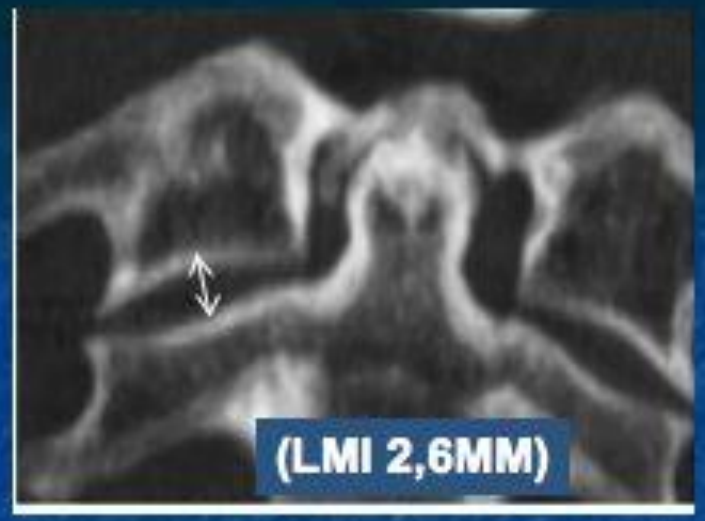

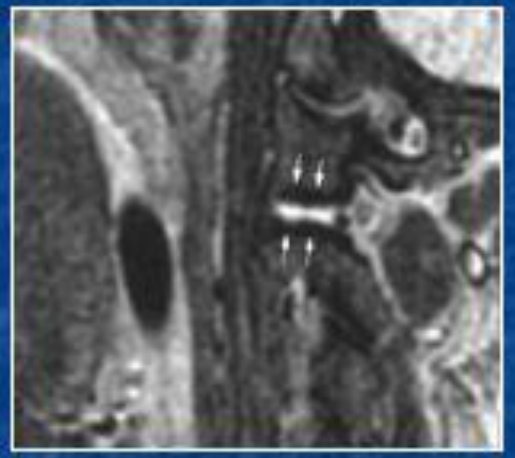

cirurgiadacolunavertebral.com.br

Instabilidade vertical C1-C2

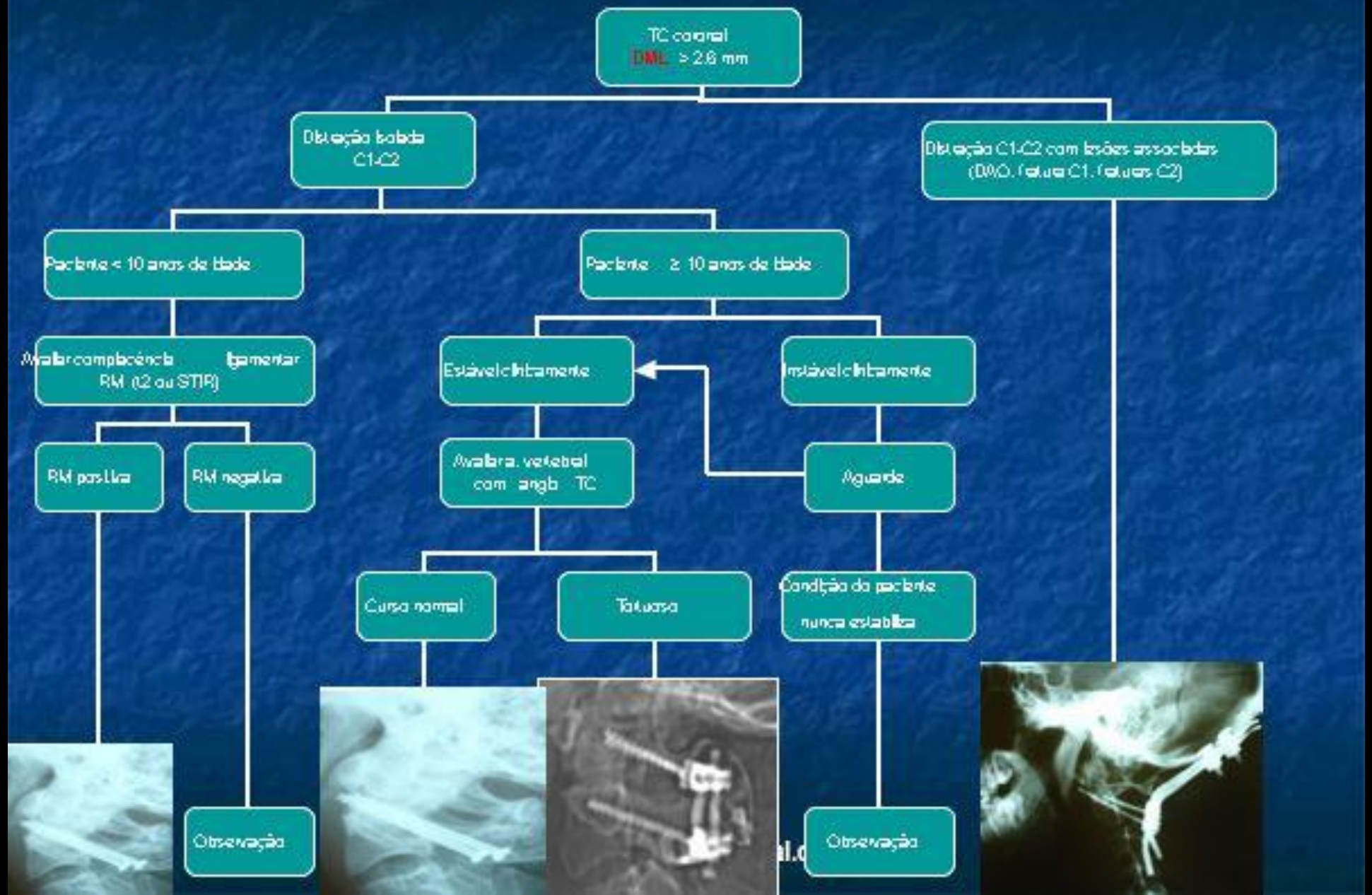

Caso Clínico

- R.C.
- Feminino
- 29 anos
- Trauma axial (vértex)direto (há 1 ano)
- Cervicalgia
- Parestesias subjetivas mmss e mmii.

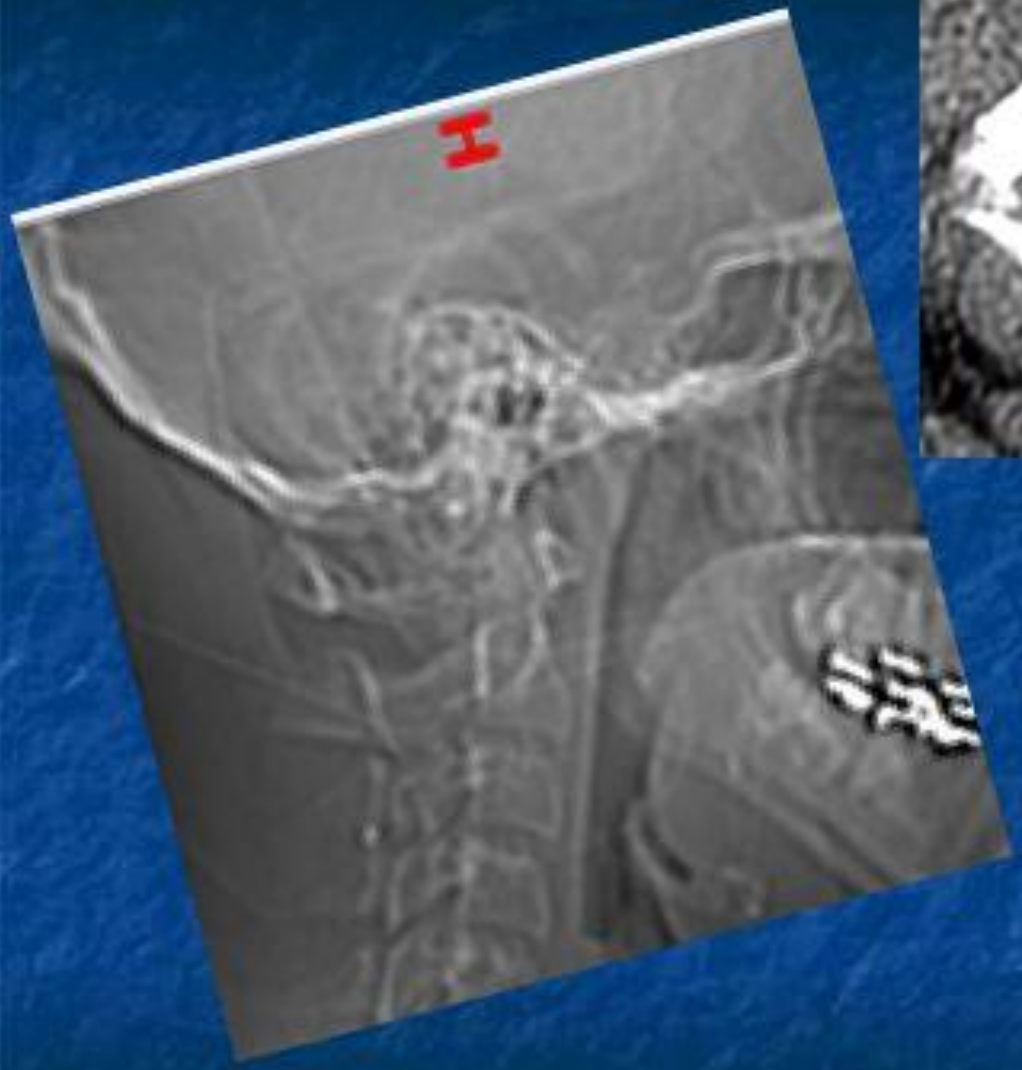

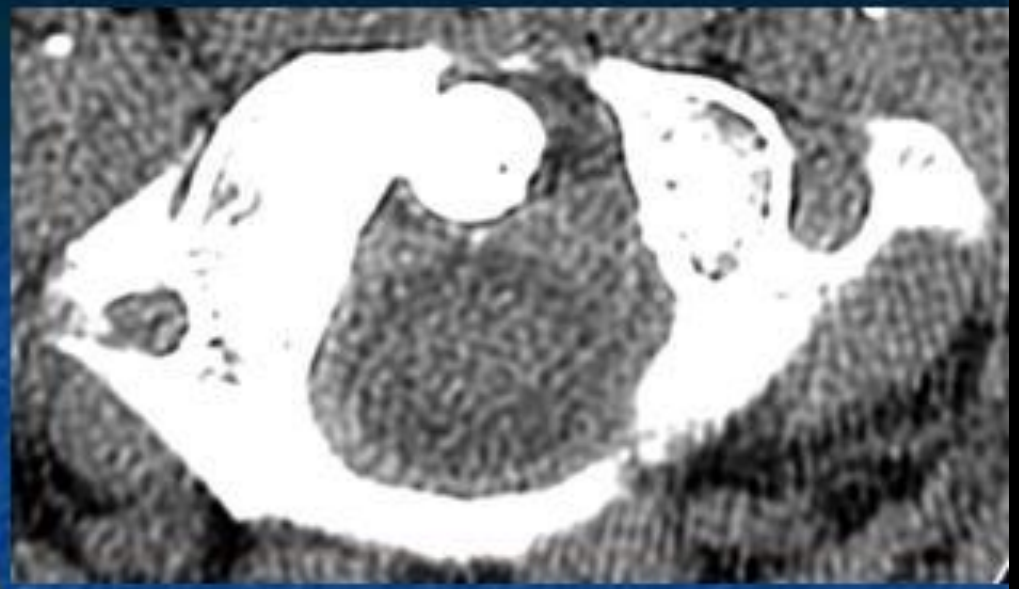

cirurgiadacolunavertebral.com.br

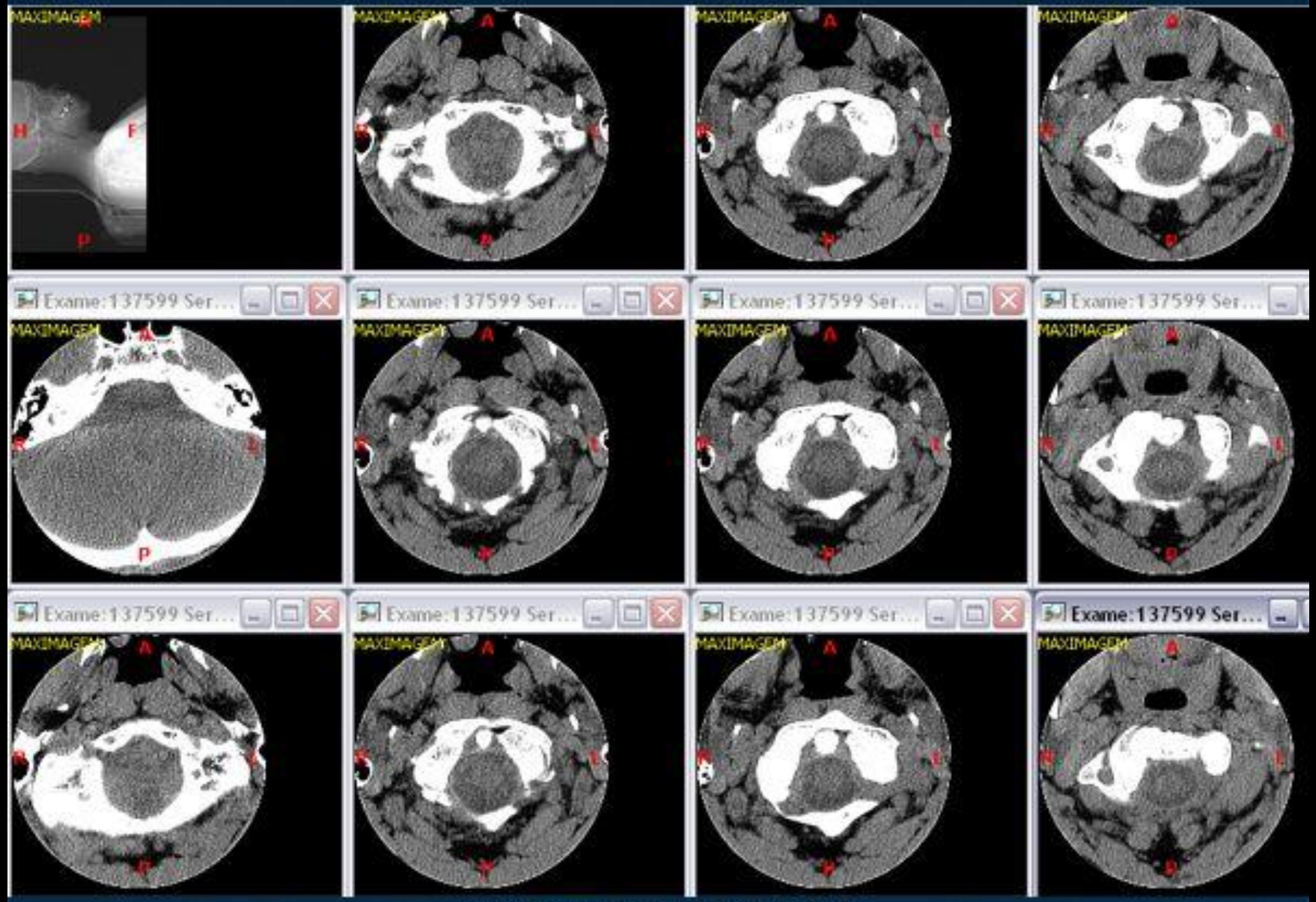

cirurgiadacolunavertebral.com.br


10
12
2
5
Spacing : 3.8

cirurgiadacolunavertebral.com.br

Tipo IV

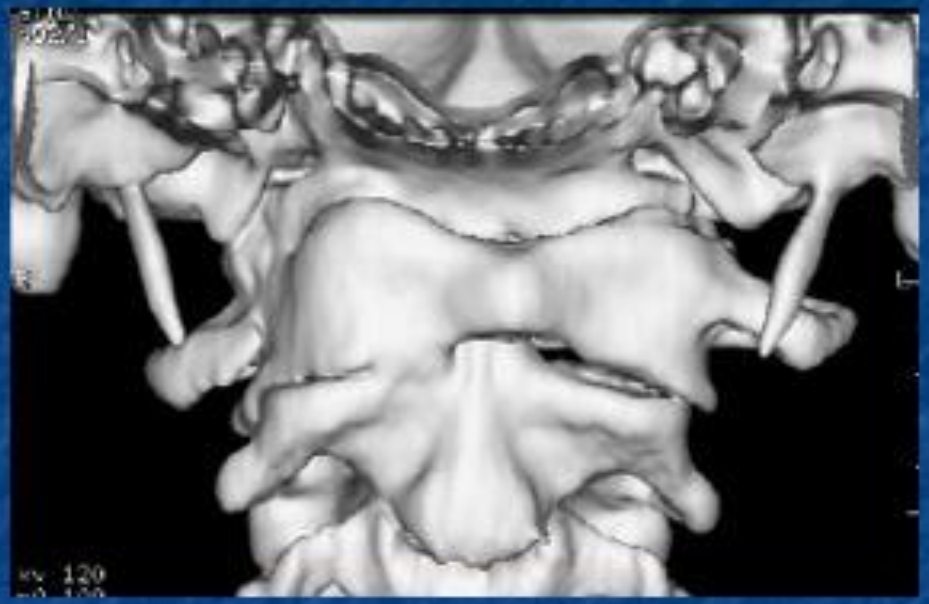

Condutas?

- Observação?
- Tração?
- Tração manual? Gardner? Halo?
- Reduzir e imobilizar?
- Filadelfia?Minerva?Halo?
- Reduzir e artrodesar?
- Cirurgia imediata?

Subluxação Atlantoaxial tipo IV

- Tratamento:
- Frequentemente não cirúrgico
- Tração (prolongada com uso de relaxantes)
- Cirurgia:
  - lesões irredutíveis
  - recorrentes
  - lesões do LTA.

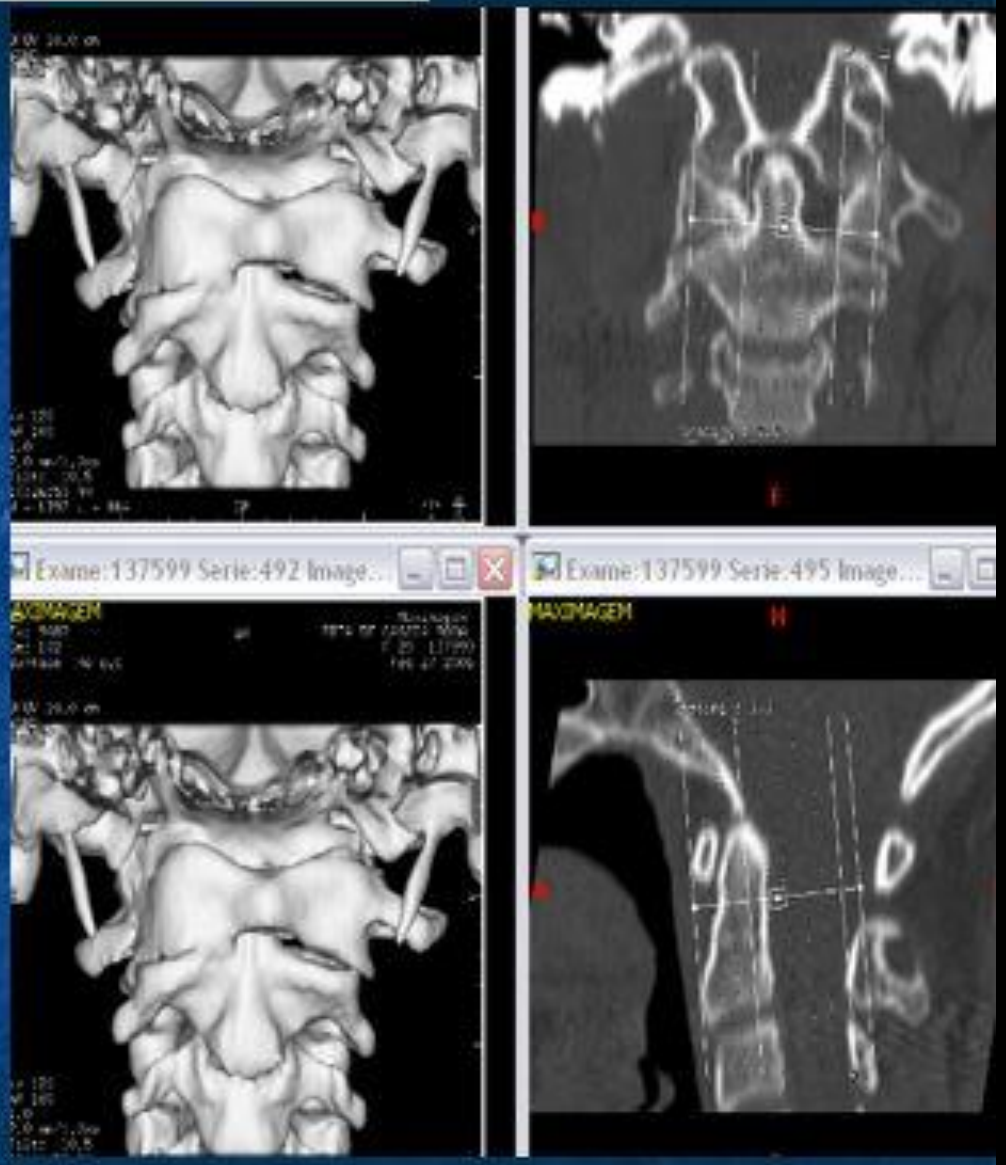

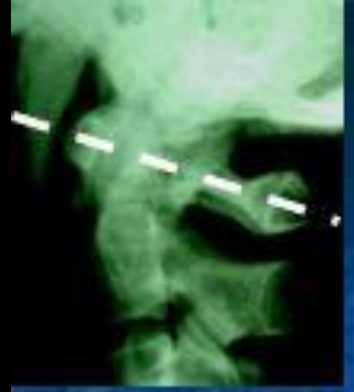

4.Fraturas do Atlas

- Fraturas isoladas do arco anterior ou posterior
- Fraturas do arco anterior e posterior (Explosão)
- Fraturas da massa Lateral
- Fraturas cominutivas
- Fraturas do processo transverso

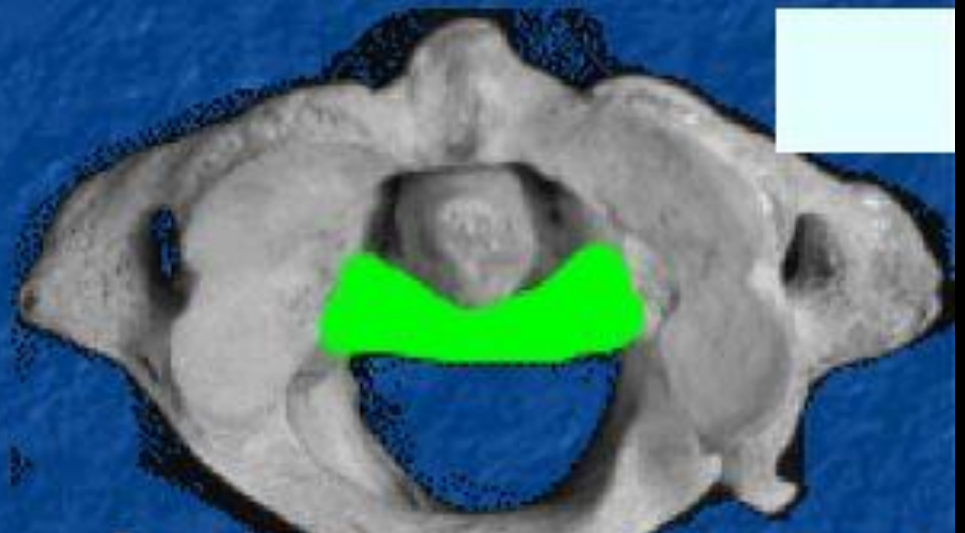

Levine - Atlas fractures 1991

Fractures of the Atlas*†

BY ALAN M. LEVINE, M.D.‡, AND CHARLES C. EDWARDS, M.D.‡, BALTIMORE, MARYLAND

From the Section of Spinal Surgery, Division of Orthopaedic Surgery, University of Maryland, Baltimore

ABSTRACT: Thirty-four patients who had fractures of the atlas (the first cervical vertebra) were reviewed at an average follow-up of 4.5 years. Seventeen patients had bilateral fracture of the posterior arch of the first cervical vertebra. Eight were treated with immobilization in a cervical orthosis, with no long-term problems secondary to the injury. Nine of these patients had additional fractures in the first and second cervical vertebral complex, complicating the management of the fractures of the posterior arch. Two of the nine patients died, and the treatment of the other seven was dependent on the additional fractures.

A second group of six patients had a fracture in the area of the lateral mass, with one fracture just anterior to or within the anterior portion of the lateral mass of the first cervical vertebra and a second fracture posterior to the lateral mass of the first cervical vertebra on the same side; resultant asymmetrical displacement of the lateral masses was seen on the open-mouth roentgenogram that was made for each patient. A third group of eleven patients sustained a Jefferson, or burst, fracture of the first cervical vertebra. These patients had either four fractures (two in the anterior arch and two in the posterior arch) or three fractures (one in the anterior arch and two in the posterior arch). Spreading of the

las may be difficult in an emergency. Fractures of the anterior aspect of the first cervical vertebra may be occult. A retropharyngeal hematoma evident on the lateral roentgenogram of the cervical spine may be the only indicator of anterior fractures[17,23] and of the need for additional roentgenographic studies. An open-mouth roentgengogram is helpful to visualize the displacement of the lateral masses of the first cervical vertebra[22] but does not demonstrate the location of the fractures in the atlas. Since there is a high prevalence of concomitant fractures of the first and second cervical vertebral complex[7,12,14,15], the more obvious fracture of the odontoid process or traumatic spondylolisthesis of the axis may obscure the less obvious fractures of the atlas. The accurate diagnosis of fractures of the first cervical vertebra is therefore dependent on performing additional roentgenographic studies, including two-plane tomography and computer-assisted tomography, although the roles and limitations of those studies for these fractures have not been clearly delineated.

Several types of fractures of the atlas have been defined, ranging from isolated fractures of the posterior arch to Jefferson (burst) fractures[3,10,14,19]. Neurological injury is infrequent, although occasionally a patient has a massive intracranial lesion[1,6]. Because most fractures of the atlas have been described either in case reports or in very small

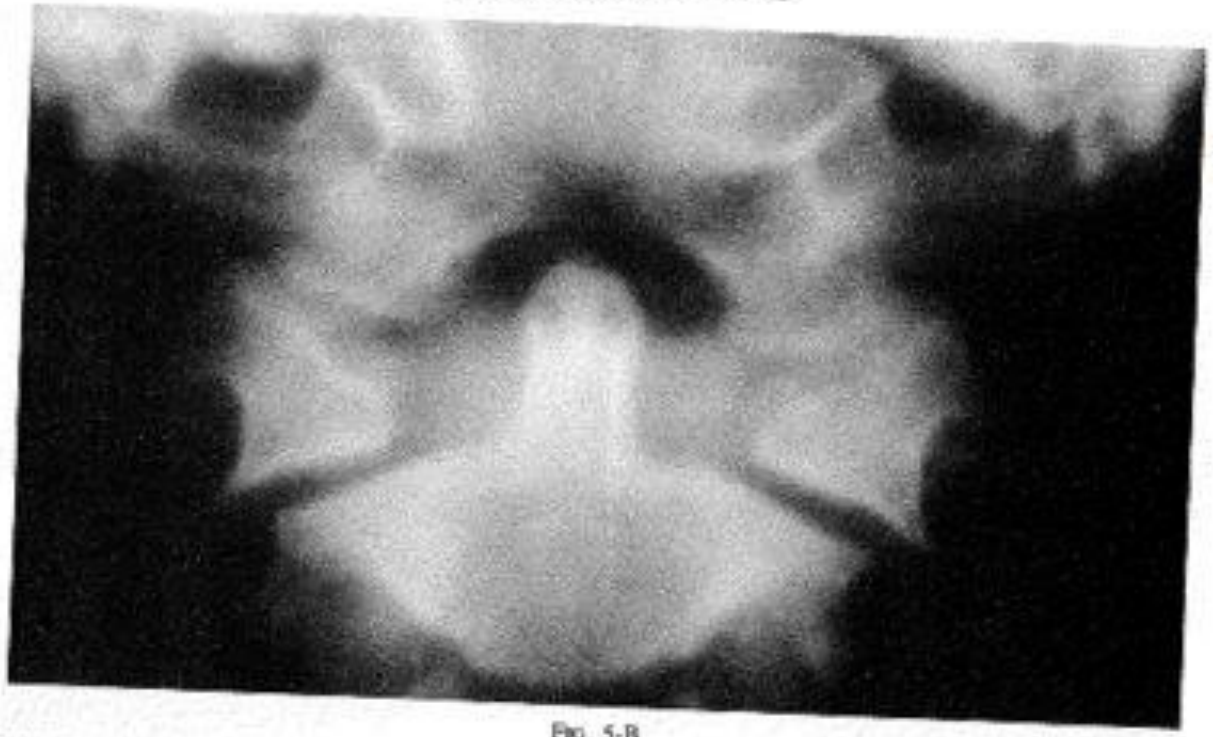

N=11

FIG. 5-B

Anteroposterior tomograms made on admission demonstrate symmetrical spreading of the lateral masses, with a total combined displacement of twelve millimeters.

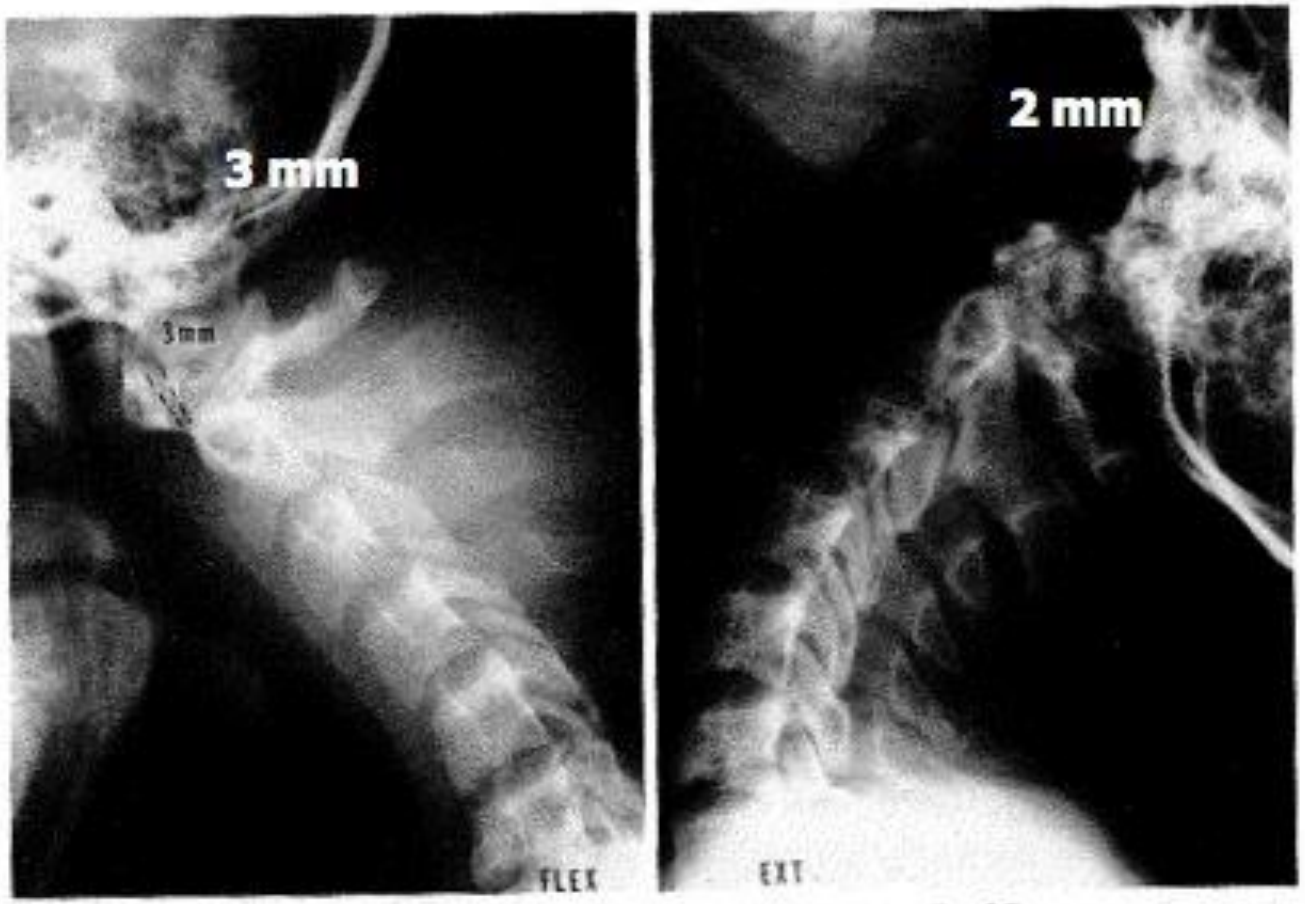

FIG. 5-D FIG. 5-E

Figs. 5-D and 5-E: Despite clear documentation of the rupture of the transverse ligament, on roentgenograms made at the one-year follow-up the atlanta-dens interval was three millimeters with the neck in flexion (Fig. 5-D) and two millimeters with the neck in full extension (Fig. 5-E).

O tratamento das fraturas de Jefferson tem sido controverso

A imobilização imediata com halo-colete não reduz e não mantém a redução.

Tração de 2 a 7 dias reduz as massas laterais mas a luxação se refaz durante o uso do halo-colete.

Tração prolongada reduz a luxação. A importância da redução é discutível.

Alguma instabilidade em flexão pode estar presente mas é normalmente limitada.

Nenhuma instabilidade tardia foi notada.

O tratamento das fraturas de Jefferson tem sido controverso

A imobilização imediata com halo-colete não reduz e não mantém a redução.

Tração de 2 a 7 dias reduz as massas laterais mas a luxação se refaz durante o uso do halo-colete.

Tração prolongada reduz a luxação. A importância da redução é discutível.

Alguma instabilidade em flexão pode estar presente mas é normalmente limitada.

Nenhuma instabilidade tardia foi notada.

O tratamento das fraturas de Jefferson tem sido controverso

A imobilização imediata com halo-colete não reduz e não mantém a redução.

Tração de 2 a 7 dias reduz as massas laterais mas a luxação se refaz durante o uso do halo-colete.

Tração prolongada reduz a luxação.
A importância da redução é discutível.

Alguma instabilidade em flexão pode estar presente mas é normalmente limitada.

Nenhuma instabilidade tardia foi notada.

Lesão do Ligamento Transverso

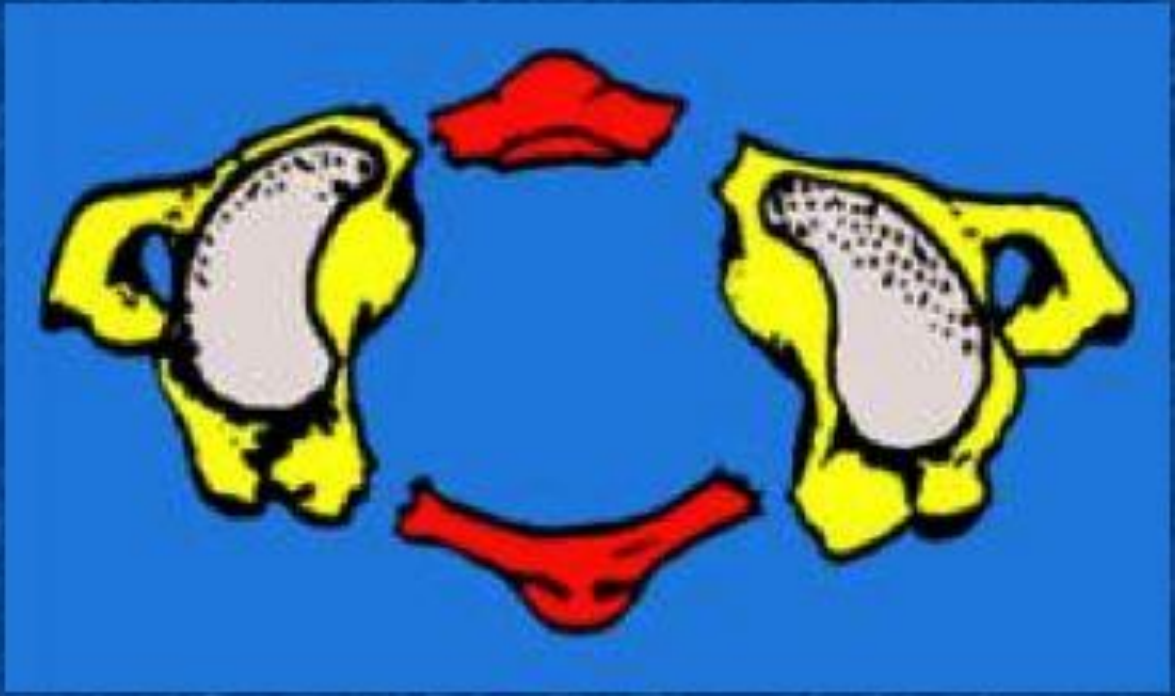

Regra de "Spence"

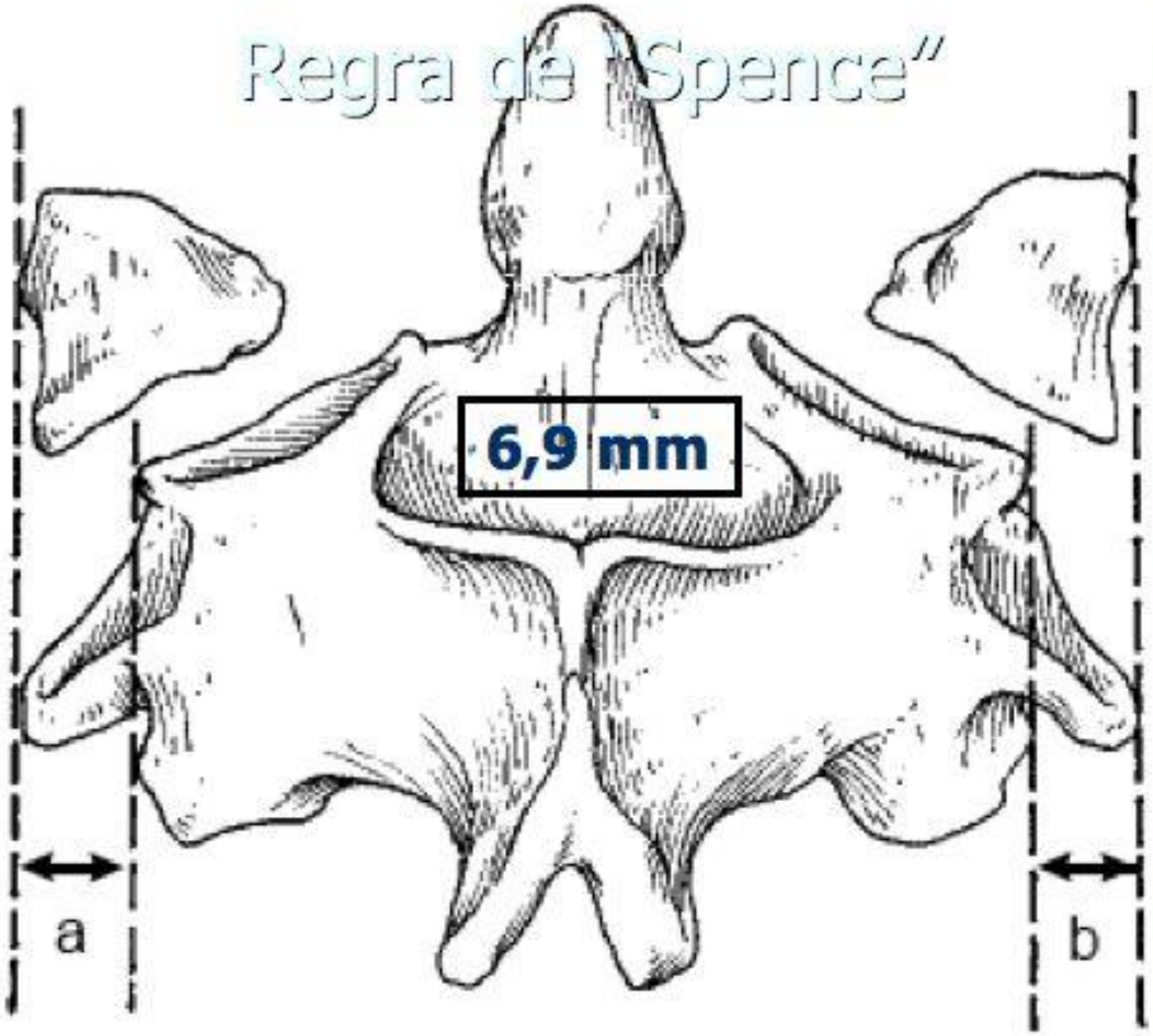

Bursting Atlantal Fracture Associated with Rupture of the Transverse Ligament*†

BY KENNETH F. SPENCE, JR., M.D.‡, BALTIMORE, MARYLAND, LIEUTENANT COMMANDER SCOTT DECKER§, AND COMMANDER KENNETH W. SELL§, MEDICAL CORPS, UNITED STATES NAVY

From the Tissue Bank, Naval Medical Research Institute and the Department of Orthopaedic Surgery, Naval Hospital, National Naval Medical Center, Bethesda

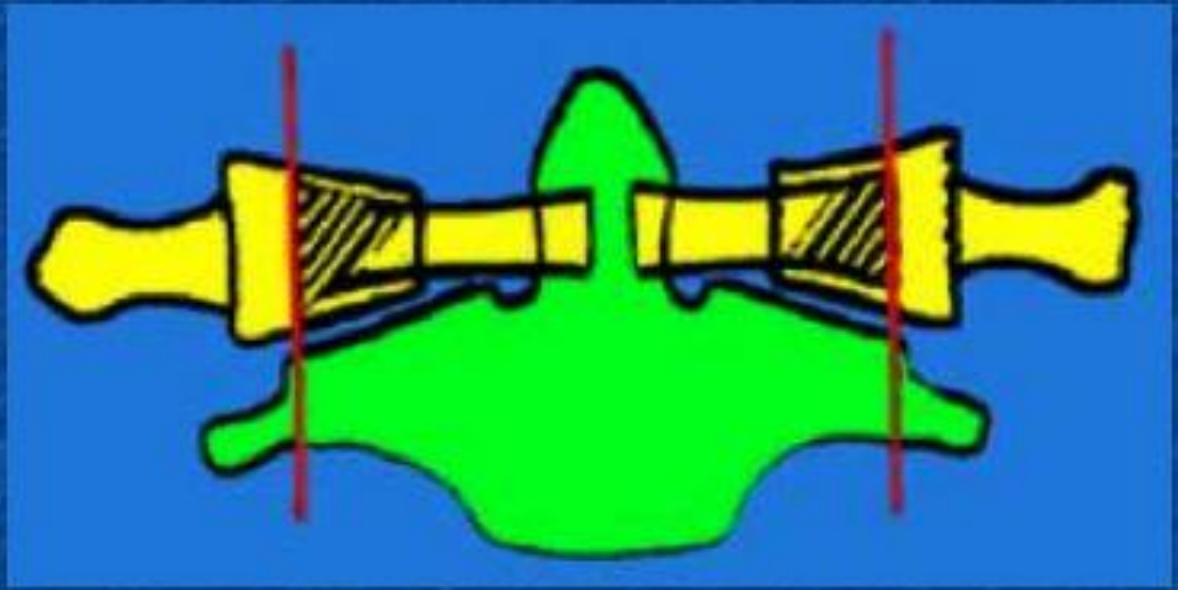

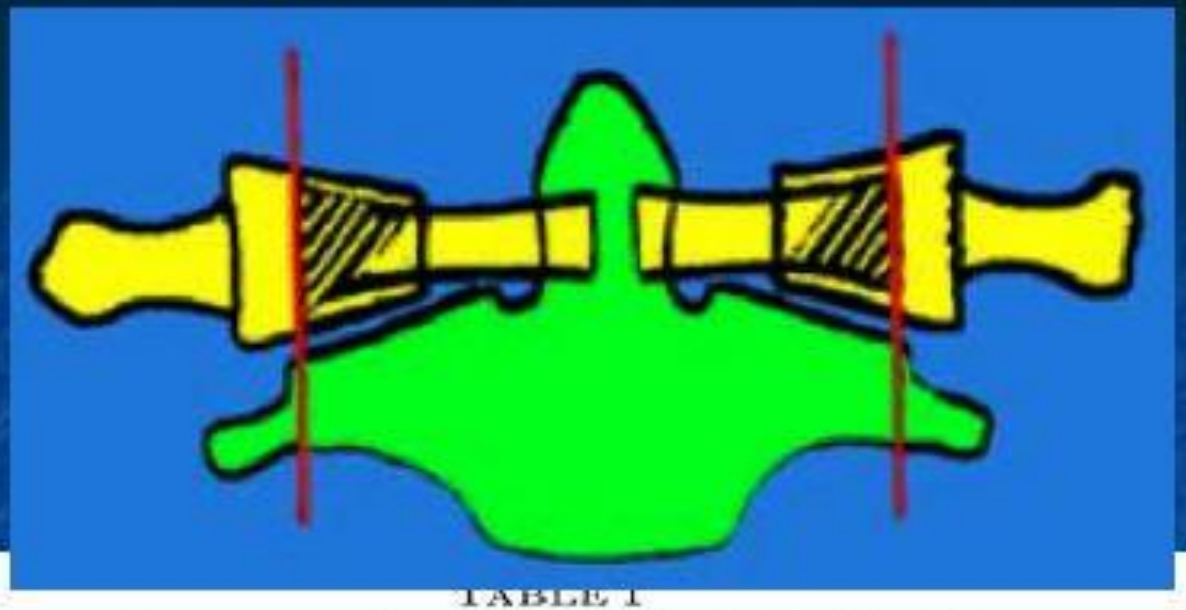

TABLE I

WIDTH AND EXCURSION OF LATERAL MASSES

Experiment No.	Resting Width (*cm*)	Taut Width (*cm*)	Difference* (*mm*)	Breaking Width (*cm*)	Breaking Force† (*kg*)	Total Excursion‡ (*mm*)	Site of Break
1	4.94	5.03	0.9	5.50	104	5.6	Central
2	5.18	5.28	1.0	5.83	73	6.5	Lateral
3	5.38	5.63	2.4	6.04	— **	6.6	Lateral
4	5.07	5.30	2.7	5.64	43	5.7	Central
5	5.17	5.40	2.3	5.65	45	4.8	Central
6	4.69	5.10	4.1	5.37	80	6.8	— **
7	5.28	5.55	2.7	5.98	38	7.0	Central
8	4.84	5.07	2.3	5.41	— **	5.7	Central
9	4.47	4.98	5.1	5.23	47	7.6	Central
10	4.57	4.80	2.3	5.29	39	7.2	Lateral

* Mean excursion to tighten ligament 2.3 millimeters.
† Mean breaking force 58 kilograms.
‡ Mean excursion to rupture ligament 6.3 millimeters.
** Failure to record.

X=6,8 mm

- Spence:
- 6,9 mm: LTA roto

↓

Fusão C1C2

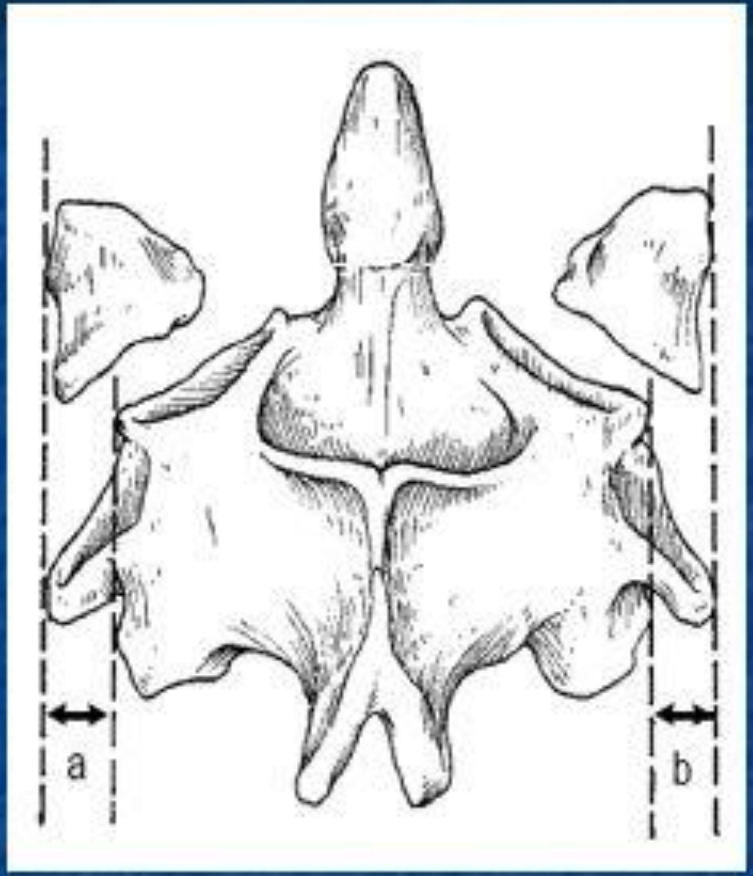

Experimental Study of Atlas Injuries II
Relevance to Clinical Diagnosis and Treatment

TAKENORI ODA, MD,* MANOHAR M. PANJABI, PhD,† JOSEPH J. CRISCO, III, PhD,†
THOMAS R. OXLAND, MASc,† LEE KATZ, MD,‡ and LUTZ-P. NOLTE, PhD§

Our results showed that the most reliable tool to diagnose the status of the transverse ligament, especially from a functional viewpoint, was ADI on flexion radiographs.

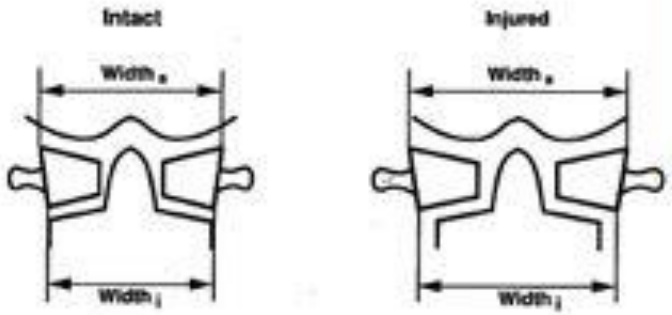

$$LMS_s = \frac{Width_s\,(Injured) - Width_s\,(Intact)}{Width_s\,(Intact)} \times 100$$

$$LMS_i = \frac{Width_i\,(Injured) - Width_i\,(Intact)}{Width_i\,(Intact)} \times 100$$

B

Table 1. Produced Injuries

Spine No.	Preinsuma Posture	Dropped Mass (kg)	C1 Sites of Injury	Clinical Diagnosis of C1 Injury	Associated Injuries
1	N	6	MS	Transverse ligament rupture	—
2	N	6	MS	Transverse ligament rupture	C0 condyle fracture
3	N	6	AA(r),BA(r),LM(r),PA(r)	Burst fracture	C0 condyle fracture, C2 tear-drop fracture
4	N	6	AA(l),BA*(l),LM(l),PA(l,r)	Burst fracture	Traumatic spondylolisthesis of the axis
5	N	6	AA(l),BA(r),LM(r)	Burst fracture	—
6	N	3	AA(r),BA(l),PA(l,r)	Burst fracture	—
7	N	3,4	AA(r),MS,PA(r)	Burst fracture	—
8	N	3,4,5,6,7	PA(l,r)	Posterior arch fracture	Traumatic spondylolisthesis of the axis
9	E	1,2,3	AA(r),BA(r),PA(l,r)	Burst fracture	—
10	E	1,2,3,4	AA(l),LM(r),PA(l,r)	Four-part fracture†	—

*Partial avulsion (posterior half only).
†Four-part (bilateral anterior and posterior) fracture without a prominent burst.
N = neutral; E = extended; MS = midsubstance tear of the transverse ligament; LM = lateral mass; AA = anterior arch; BA = bony avulsion of the transverse ligament; PA = posterior arch; l = left side; r = right side.

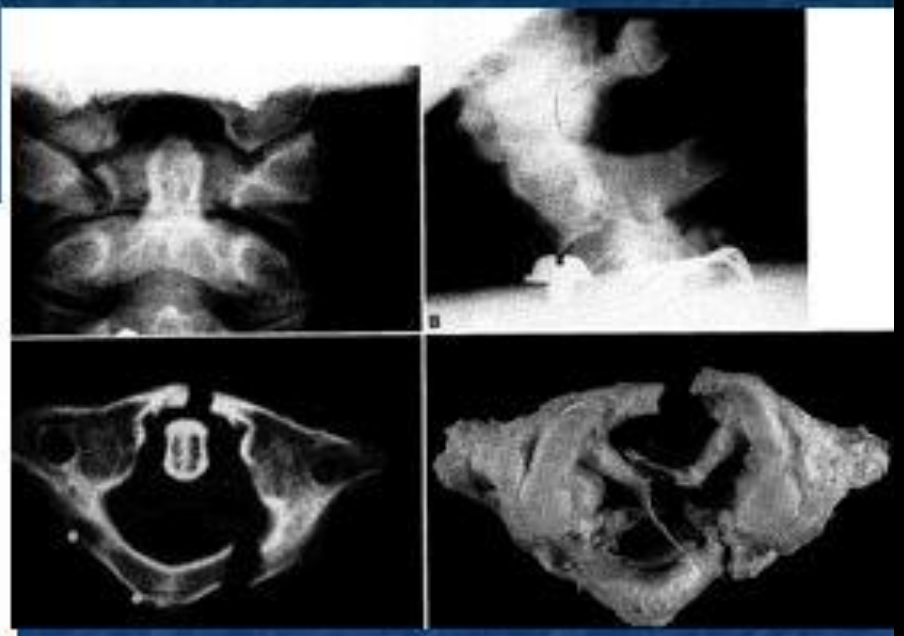

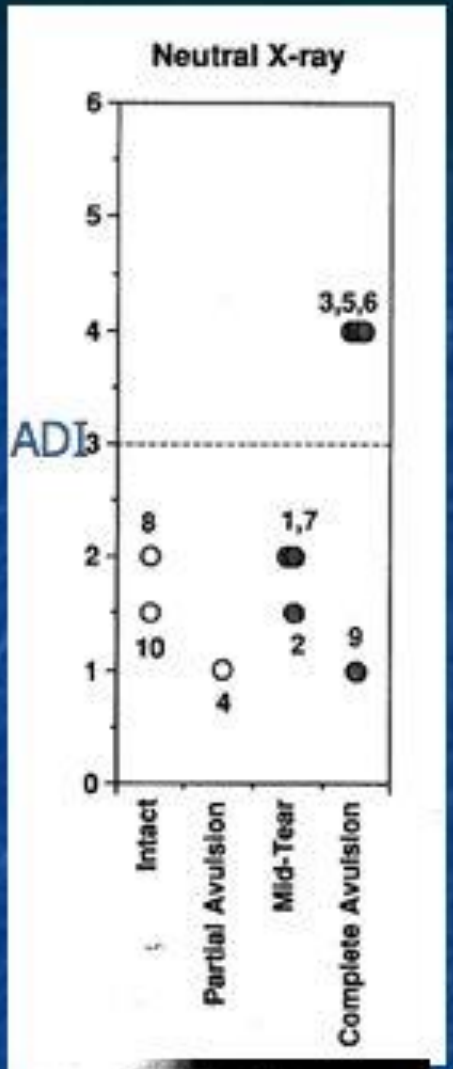
Neutral X-ray
6
5
4
ADI 3
2
1
0
3,5,6
8
1,7
10
2
9
4
Intact
Partial Avulsion
Mid-Tear
Complete Avulsion


ADI

cirurgi r

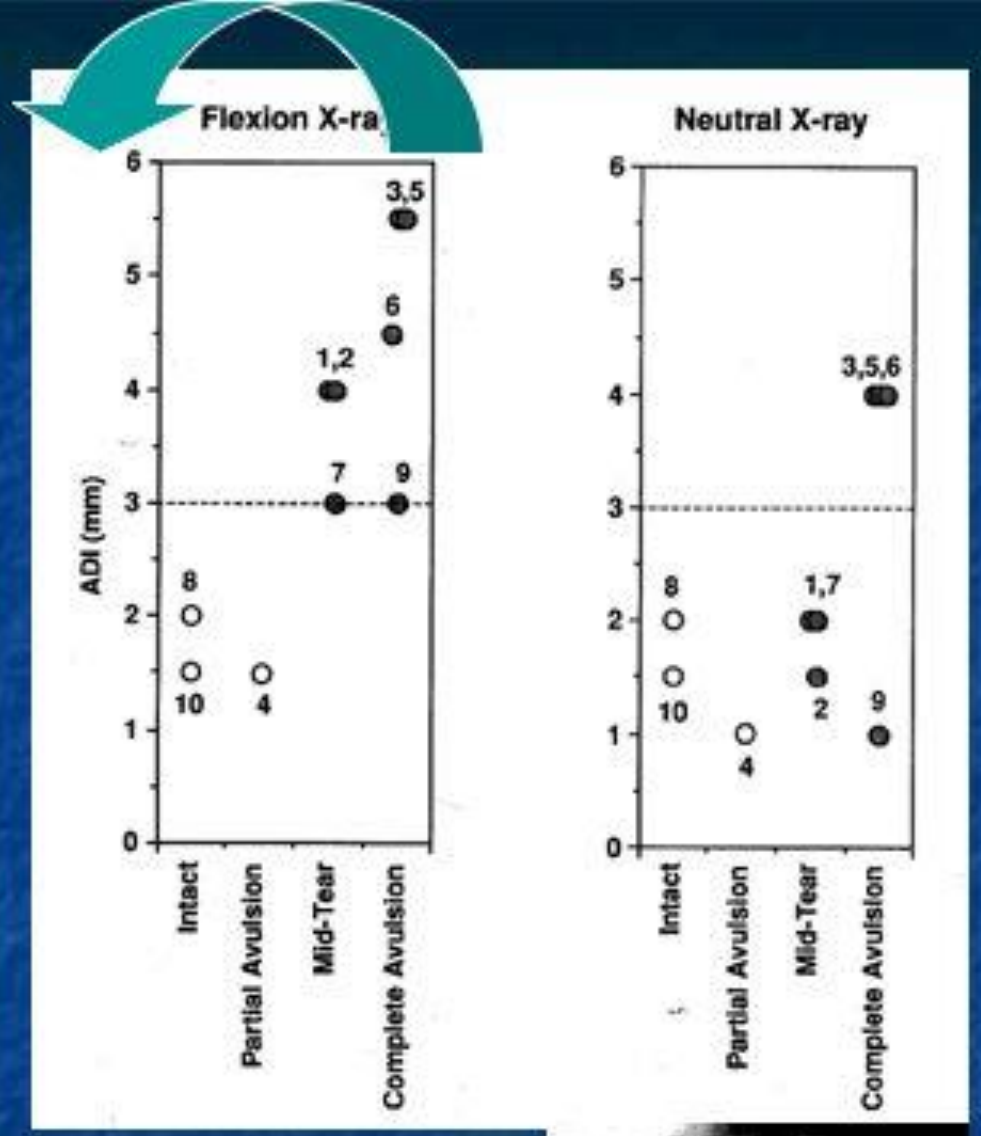

ADI

cirurgia

1. ADI>3 mm= Lesão do Ligamento Transverso.
2. Exame mais importante no diagnóstico é o rx dinâmico

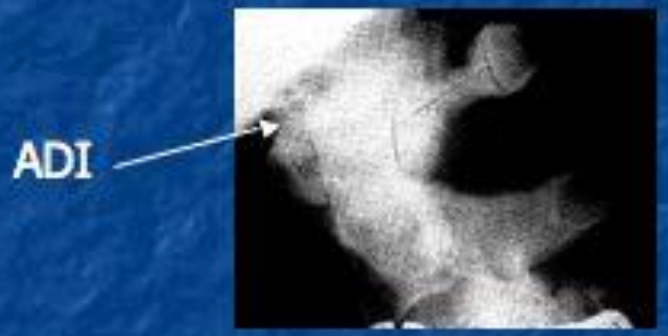

Injuries Involving the Transverse Atlantal Ligament: Classification and Treatment Guidelines Based upon Experience with 39 Injuries

38(1), January 1996

Dickman, Curtis onntag, Volker K.H. M.D.

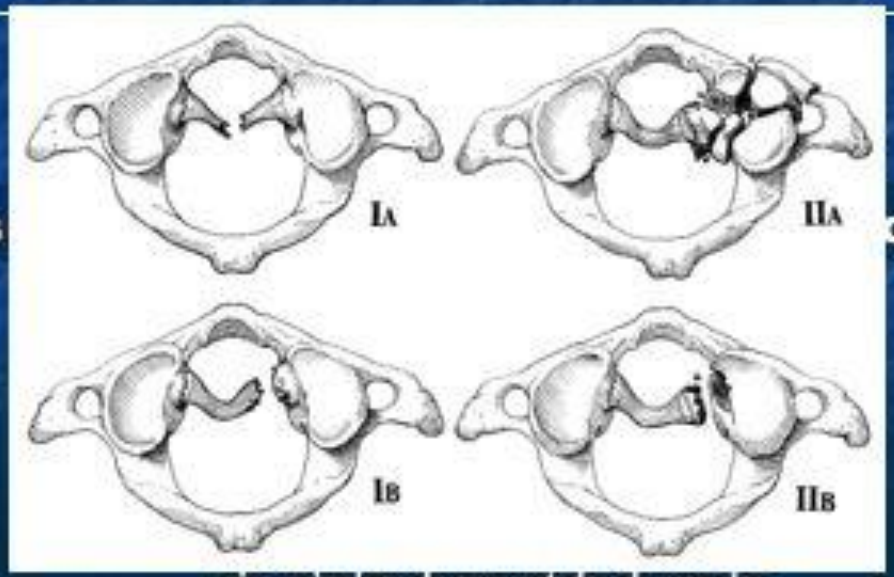

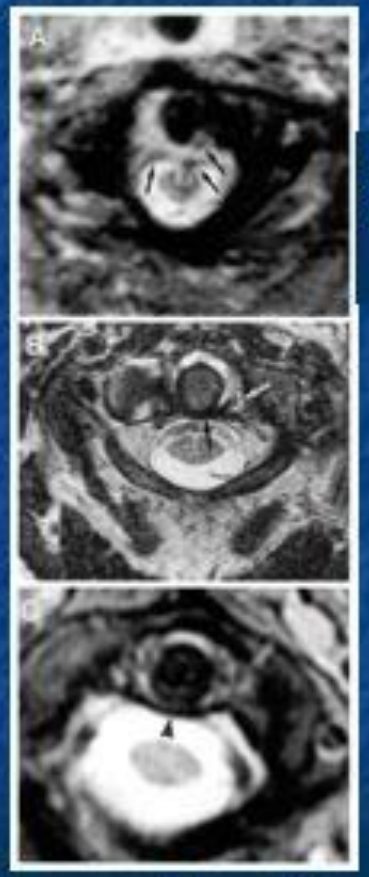

16: Tipo I
15 aumento ADI
(x= 8 mm; 2-14 mm)

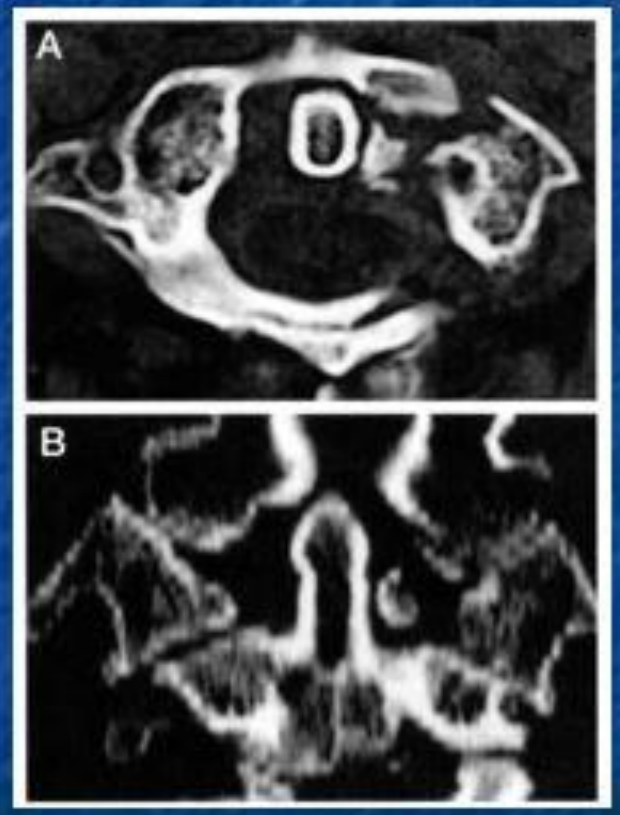

23: Tipo II
96% Fratura do Atlas

- Todos: subluxação móvel
- C1C2

- ¾ Tipo II:
- Cicatrizam

LTA

Tipo I: Incapaz cicatrizar Cirurgia

- 15 pacientes operados:
- Fixação C1C2 (amarrilho)
- 6 parafusos transarticulares C1C2

Fixação Occipitocervical : fratura de C1 que impede a fixação.

¾ Tipo II: Cicatrizam

Halo-colete
Cirurgia no insucesso (26%)

- "Flexion and extension radiographs are not advocated ...because of the risk of neurological injury."

Dickman.; Greene; Sonntag

X

1. ADI>3 mm= Lesão do Ligamento Transverso.
2. Exame mais importante no diagnóstico é o rx dinâmico

Oda; panjabi;Crisco et. Al.

Fraturas do Atlas

- Opções: tratamento dirigido ao tipo da fratura.
- LTA intacto: imobilização cervical.
- Lesão do LTA: imobilização ou cirurgia.

SERVIÇO DE NEUROCIRURGIA

TRAUMA RAQUIMEDULAR
PROTOCOLO

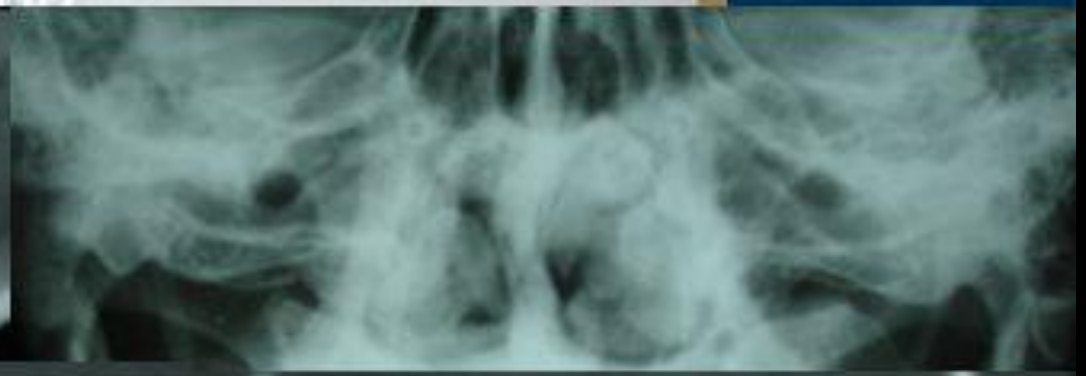

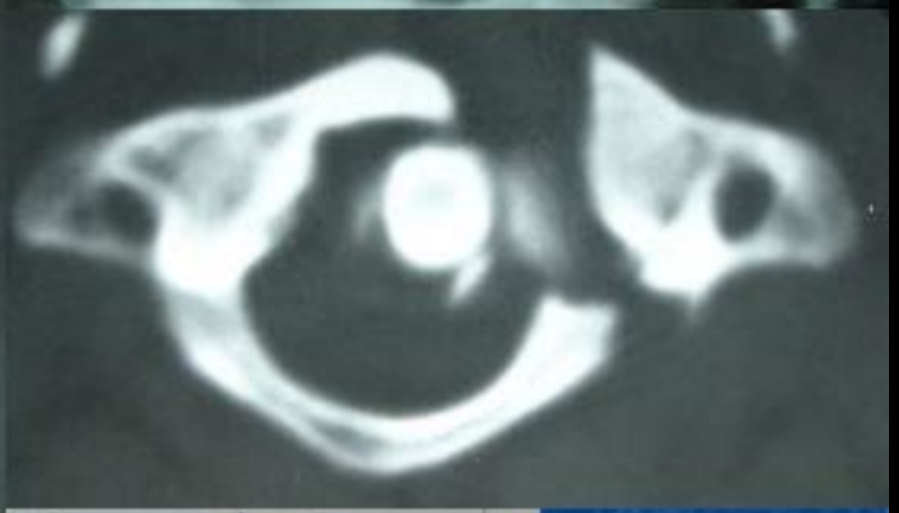

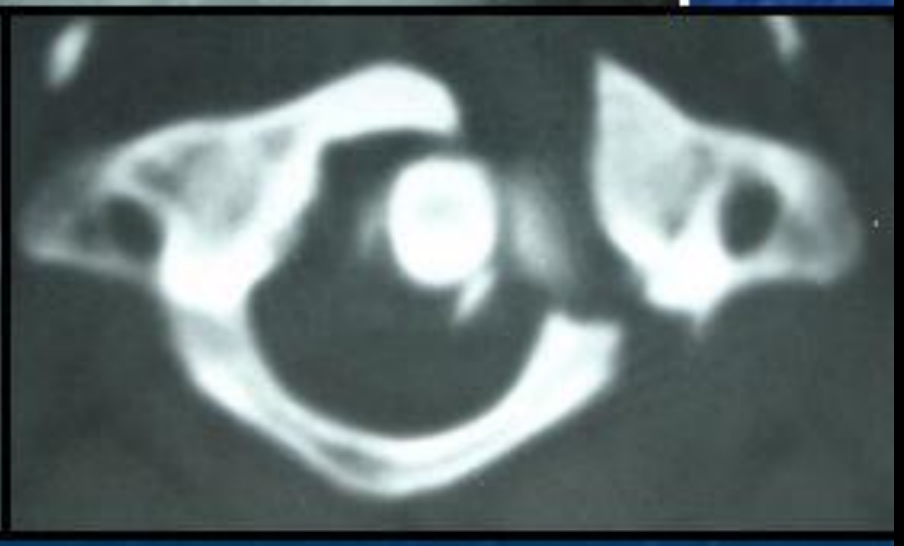

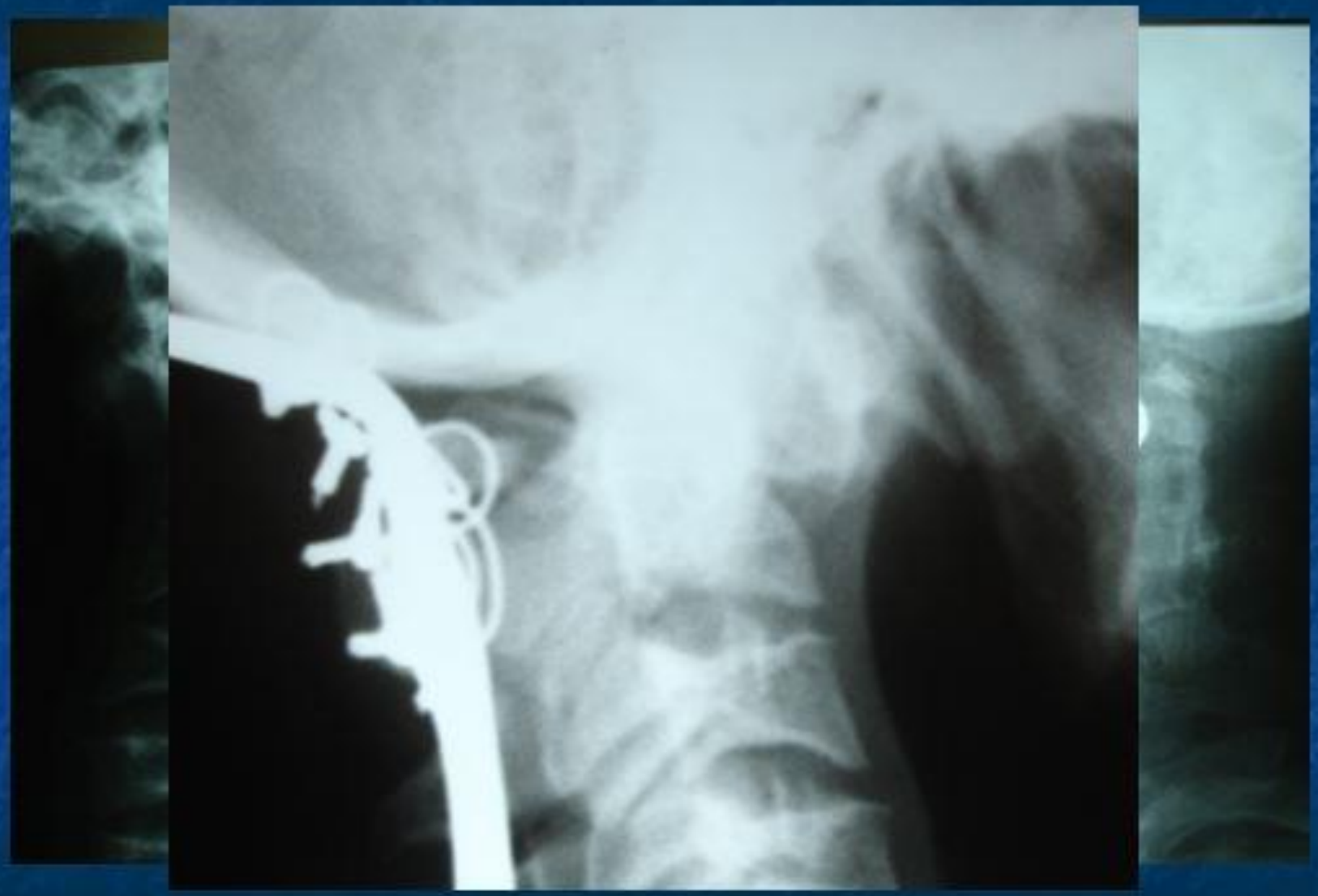

cirurgiadacolunavertebral.com.br

J.R.S.Alves
22.07.05
Moto
Paresia mão E

cirurgiadacolu

cirurgiadacolunavertebral.com.br

Fraturas do Axis-(C2)

- Dente do axis
- Espondilolistese
- Miscelânea

cirurgiadacolunavertebral.com.br

- Pubmed 1966-2001
- 711 artigos

Fractures of the Odontoid Process of the Axis*

BY LEWIS D. ANDERSON, M.D.†, AND RICHARD T. D'ALONZO, M.D.‡,
MEMPHIS, TENNESSEE

From the Department of Orthopaedic Surgery, University of Tennessee College of Medicine and the Campbell Foundation, Memphis

ABSTRACT: **Odontoid fractures were classified into three types, and, in a series of forty-nine fractures, two avulsion, thirty-two body, and fifteen basilar fractures were treated and followed for an average of twenty-two months**

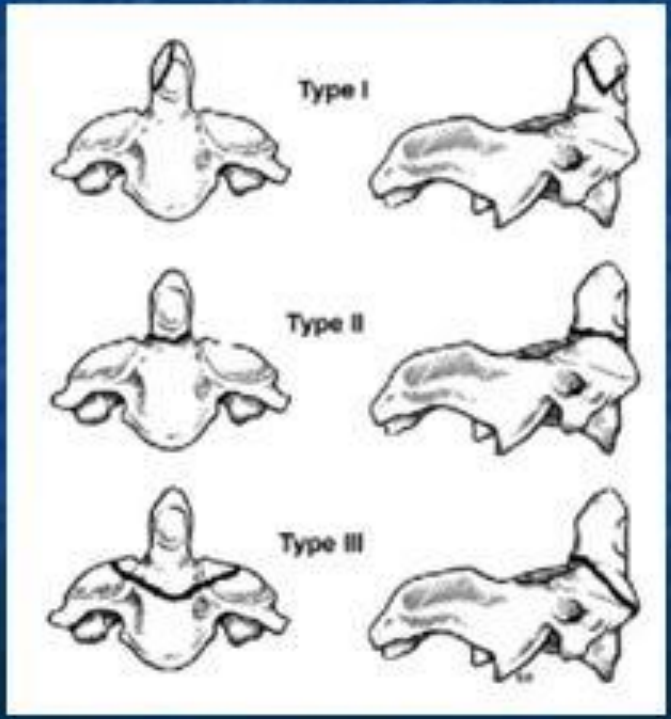

cirurgiadacolunavertebral.com.br

Fractures of the Odontoid Process of the Axis*

BY LEWIS D. ANDERSON, M.D.†, AND RICHARD T. D'ALONZO, M.D.†
MEMPHIS, TENNESSEE

From the Department of Orthopaedic Surgery, University of Tennessee College of Medicine and the Campbell Foundation, Memphis

ABSTRACT: Odontoid fractures were classified into three types, and, in a series of forty-nine fractures, two avulsion, thirty-two body, and fifteen basilar fractures were treated and followed for an average of twenty-two months (range, six months to nineteen years). Body fractures are most prone to non-union and surgery (spine fusion) is commonly required in this group.

Fractures of the odontoid process and the body of the axis have always aroused interest but there is little agreement on the best method of treatment and the long-term prognosis of these injuries. The incidence of non-union of fractures of the odontoid process has been variously estimated to be as low as 4.8 per cent and as high as 62.8 per cent [1,2,6-10]. Osgood and Lund reviewed the relevant literature in 1928, and found only fifty-five reported cases of fracture of the odontoid process. They noted that most previous authors had found a high incidence of neurological involvement and death, but suspected that this was related to many of the reported cases being from autopsy material. However, in ten of their reported patients paralysis was not present at the time of initial injury and subsequently caused death after a second, trivial injury. Osgood and Lund did state that the general impression at the t[illegible]on rarely occurred. Until the time of their review in 192[illegible]ses of operative treatment for this fracture. Two of the [illegible]d by Minter and Osgood in 1910.

Subsequent opinions [illegible] of neurological involvement, both at the time of initial i[illegible]d myelopathy. Schwartz and Wigton reported two cases of delayed myelopathy — one some eighteen years after injury and the other five years after trauma to the head and neck. Both were thought to be secondary to an unrelated fracture of the odontoid process with instability.

In our own review of the literature we found over fifty reported cases of delayed myelopathy, vary[illegible] of involvement, including spastic hemiparesis, urinary and fecal in[illegible]lipsed syndrome, monoparesis, quadriplegia, dysphagia, and neur[illegible]ves. Some of the neurological defects were progressive. Others [illegible]atic. Some began at the time of injury, while others had a delayed onset as long as forty-eight years following the initial injury. Recently, Schatzker and associates reported that of thirty-seven patients with fractures of the odontoid process, non-union developed in twenty-three (63 per cent), and Roberts and Wickstrom recently reported that in a series of fifty fractures of the odontoid process, forty of which were treated conservatively, eight developed non-union (20 per cent). They thought that delay in immobilization and inadequate immobilization contributed to the rate of non-union, and concluded that fractures of the odontoid process should be immobilized for twenty weeks in traction or a Minerva cast. If union was not present at the end of that period, they recommended cervical fusion. Schatzker and associates classified the frac-

* Read at the Annual Meeting of The American Academy of Orthopaedic Surgeons, Dallas, Texas, January 18, 1974.
† 898 Madison Avenue, Room 837, Memphis, Tennessee 38163.

1974

FIG. 2-A

FIG. 2-B

Figs. 2-A, 2-B, and 2-C: A Type-I fracture of the odontoid process located high in the odontoid process.
Fig. 2-A: The open-mouth-odontoid view.
Fig. 2-B: Water's view. The odontoid is located at the center of the foramen magnum in this view.

FIG. 2-C

The fracture healed by bone growth with conservative treatment.

. In Type III, the fracture line extends downward into the cancellous portion of the body and is really a fracture through the body of the axis. We further classified each of these types as displaced or undisplaced. As far as

VOL. 56-A, NO. 8, DECEMBER 1974

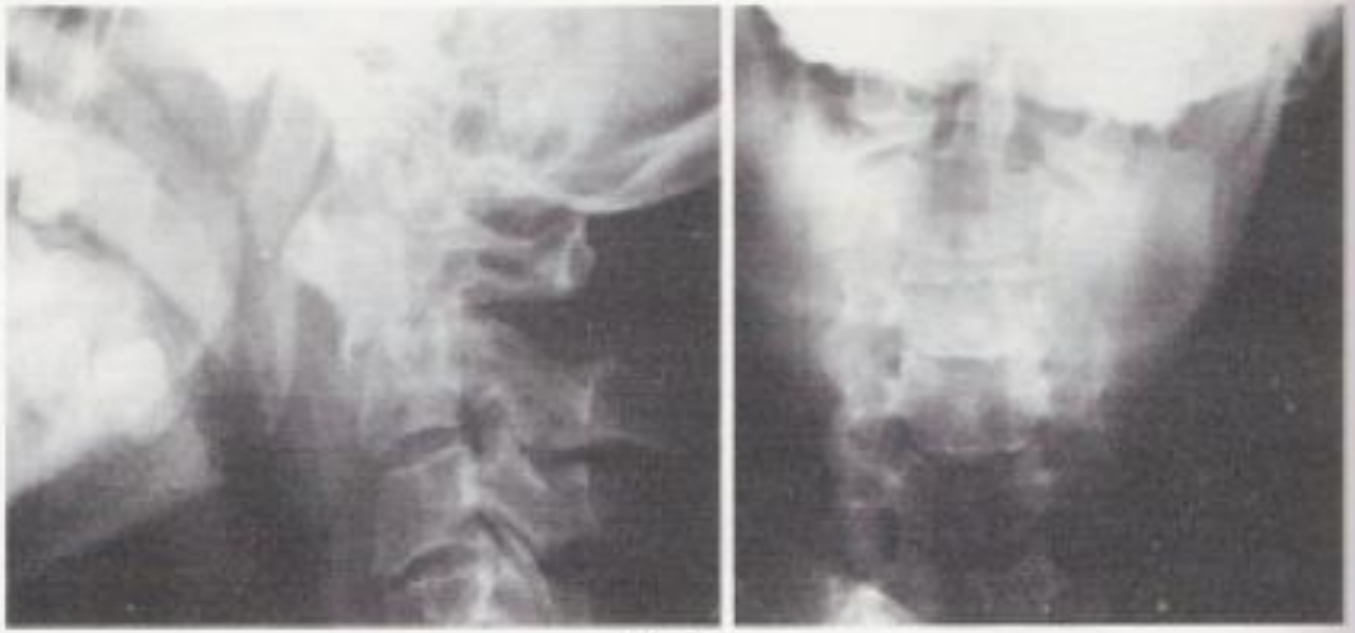

FIG. 5-A

Figs. 5-A and 5-B: A Type-III odontoid fracture.

Fig. 5-A: Lateral roentgenogram and open-mouth odontoid view. The odontoid process is displaced five millimeters anteriorly in relationship to the body of the second cervical vertebra. It was reduced almost completely with 2.6 kilograms of skeletal traction.

Arq Neuropsiquiatr 2002;60(3-B):823-829

TRATAMENTO CIRÚRGICO DAS FRATURAS DO ODONTÓIDE TIPO II COM PARAFUSO ANTERIOR

Análise de 15 casos

Fernando Luiz Rolemberg Dantas[1], Mirto Nelso Prandini[2], Antonio Carlos Vieira Caires[3], Gilberto de Almeida Fonseca[3], Jair Leopoldo Raso[4]

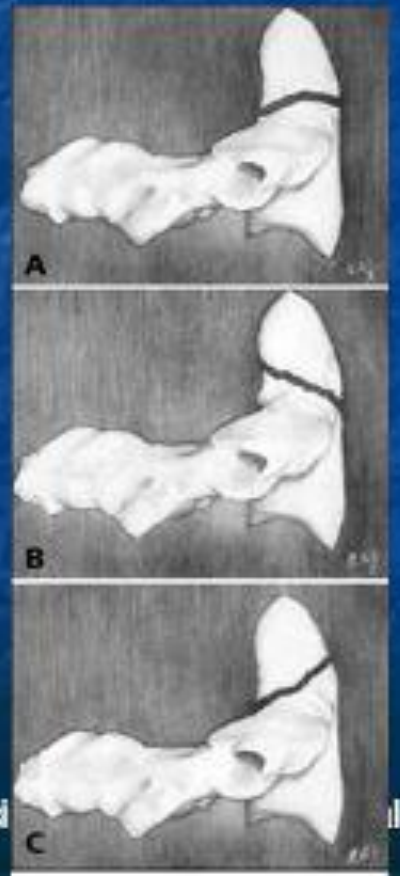

Tipo II A

- 1988-Hadley et al.
- IIA fratura cominutiva da base com fragmento livre (5%).
- Instável
- Fixação posterior precoce C1C2.

cirurgiadacolunavertebral.com.br

Fraturas do Odontóide

- Tratar ou não tratar
- Redução
- Imobilização
  - Colar
  - Halo
- Cirurgia anterior
- Cirurgia posterior

A opção de não tratar :

- Cervical Spine Research Society
- Estudo multicêntrico

(18 pcts II-3 III)

Sem tratamento nenhum paciente apresentou fusão

Não tratar fratura do Dente não é uma opção adequada

Redução Postural


FLEXÃO
gladacolunavertebral.com.br

>70 % redução

***IIA**

Tração e Imobilização

- 3/3 tipo I: Fusão
- 87% tipo III: Fusão
- 57% tipo II: Fusão

- "...traction and collar...may be considered a management option fot type I and III."

- "The low fusion rate for type II, collar is not ideal for..."

Colar Filadelfia e Minerva

Colar Philadelphia
com Orifício

COLAR FORESTIER BROWN OU MINERVA

cirurgiadacolunavertebral.com.br

Evidence-Based analysis of odontoid fracture

Halo

- Halo: 8 a 12 semanas

- Odontoide:
- I: 100% sucesso
- II:62 % sucesso
  - 30% não união
  - 8 pcs mal-união
- III:84% fusão
  - 8% insucesso
  - 7 casos de mal-união

Neurosurg Focus 2000

Deslocamento e Cicatrização

Deslocamento > 6mm ⟷ 86% insucesso

Cirurgia

- > 50 anos
- >6mm
- Deslocamento posterior
- IIa
- LLT

Odontóide tipo II

Cirurgia Via Posterior

Cirurgia Via Anterior

Cirurgia Posterior para Fratura do Odontóide

amarrilho

8 artigos

147 pacientes OD II

29 OD III

Fusão:

87% (II)

100%(III)

Cirurgia Via Anterior

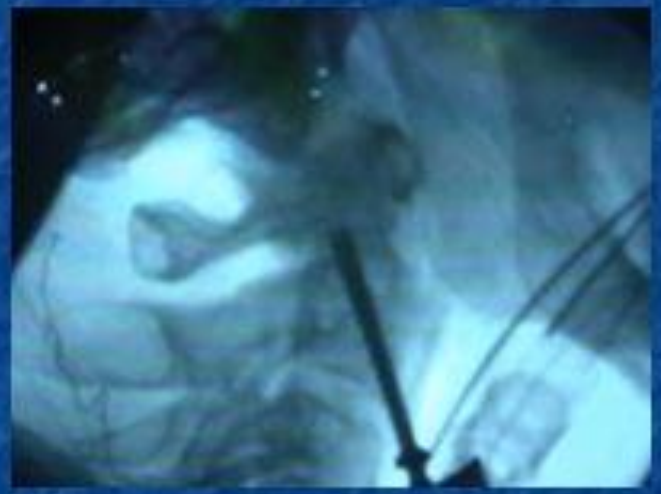

cirurgiadacolunavertebral.com.br

Parafuso no Dente

- Mantem a rotação.
- Cirurgia rápida
- Bem tolerada

Fusão:
81-96%

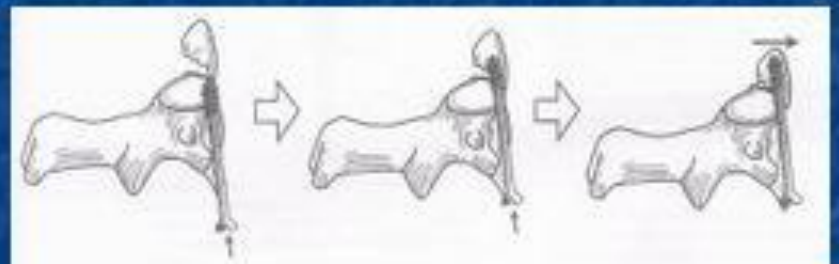

FIGURE 17-12 ■ Diagonal C2 fractures reduced to anulation and mandatory if compression is applied via

- Fusão:
- Tipo II: 89%
- Tipo III: 100%

- Subach
- Neurosurgery 1999
- Fusão: 25/26

Fraturas recentes e antigas

- <6 meses=88% sucesso
- >18 meses=25%

Afpelbaum
JNS 2000

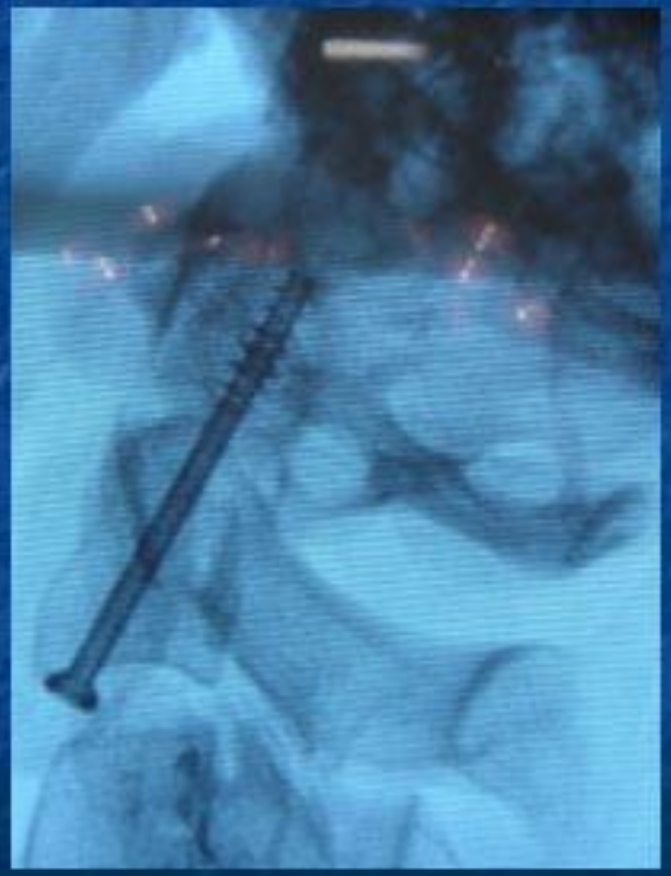

Fraturas no Idoso

- 23% fusão com imobilização externa.
  - (Ryan et. Al.)
- 26% mortalidade em inds imobilizados.
  - (Hanigan et. Al.)
- Pitzen et.al:
- 7 operados
- 2 óbitos (per-op compl)
- Bednar et. Al.:
- N=11:
- 1 óbito
- 10 fusões.
- Lennarson et. Al.
- Idade > 50 anos:ñ fusão (21x>)

CASOS CLÍNICOS

cirurgiadacolunavertebral.com.br

N B Jr. H. S Catarina

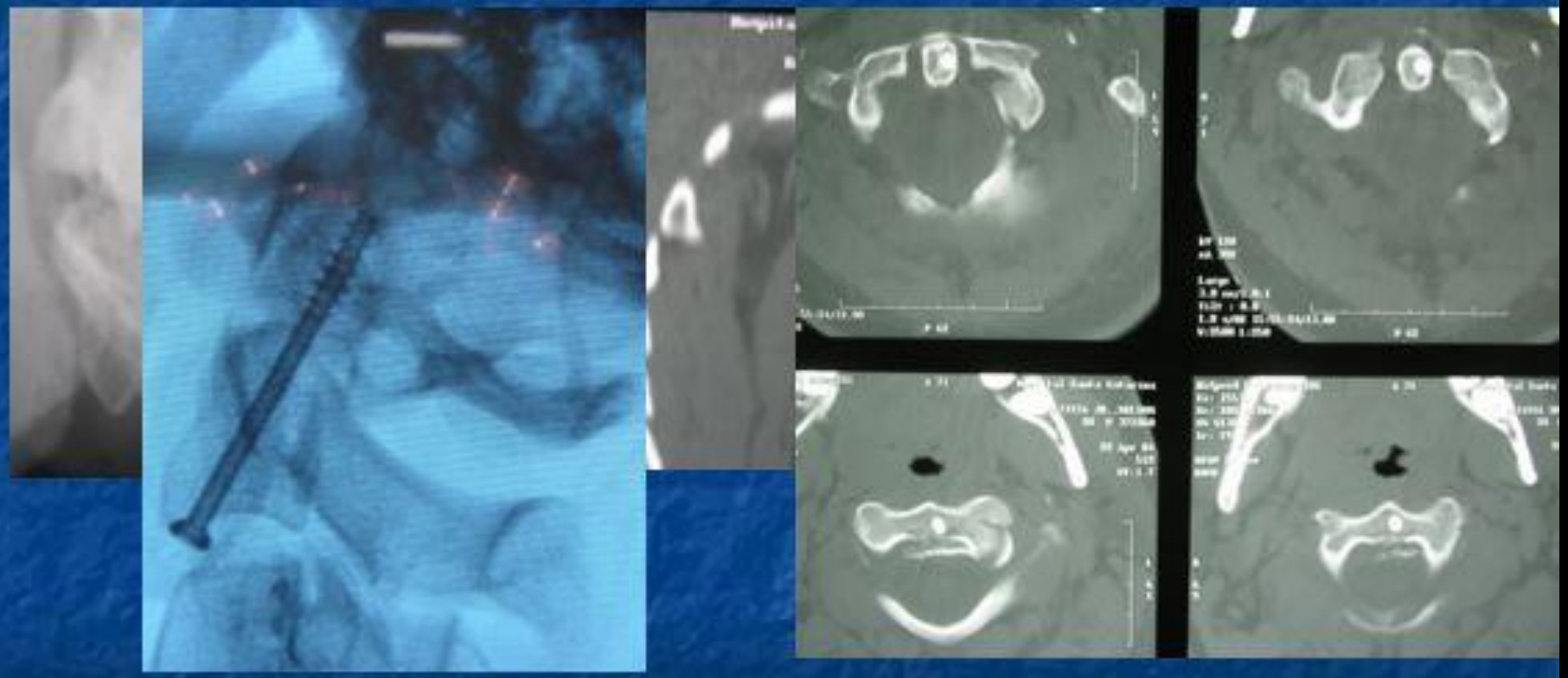

cirurgiadacolunavertebral.com.br

cirurgiadacolunavertebral.com.br

cirurgiadacolunavertebral.com.br

Sistemas de Instrumentação

Fixações posteriores

Sistemas de Fixação Posterior	Vantagens	Desvantagens
Amarrilho C1C2 (Galle-Brooks-Sonntag)	Técnica habitual Evita parafusos	Menor rigidez Necessita fixação externa mais rígida Maior taxa não união
Parafuso C1C2 transarticular	O mais rígido	Potencial para lesão Artéria Vertebral
Fixação Segmentar **C1C2 (Harms)**	**Técnica habitual*** Rígida	Potencial para lesão Artéria vertebral Sangramento venoso
Ganchos Sublaminres (Halifax)	Evita parafusos	Menor rigidez parafusos Fraca extensão Pode ocupar canal

cirurgiadacolunavertebral.com.br

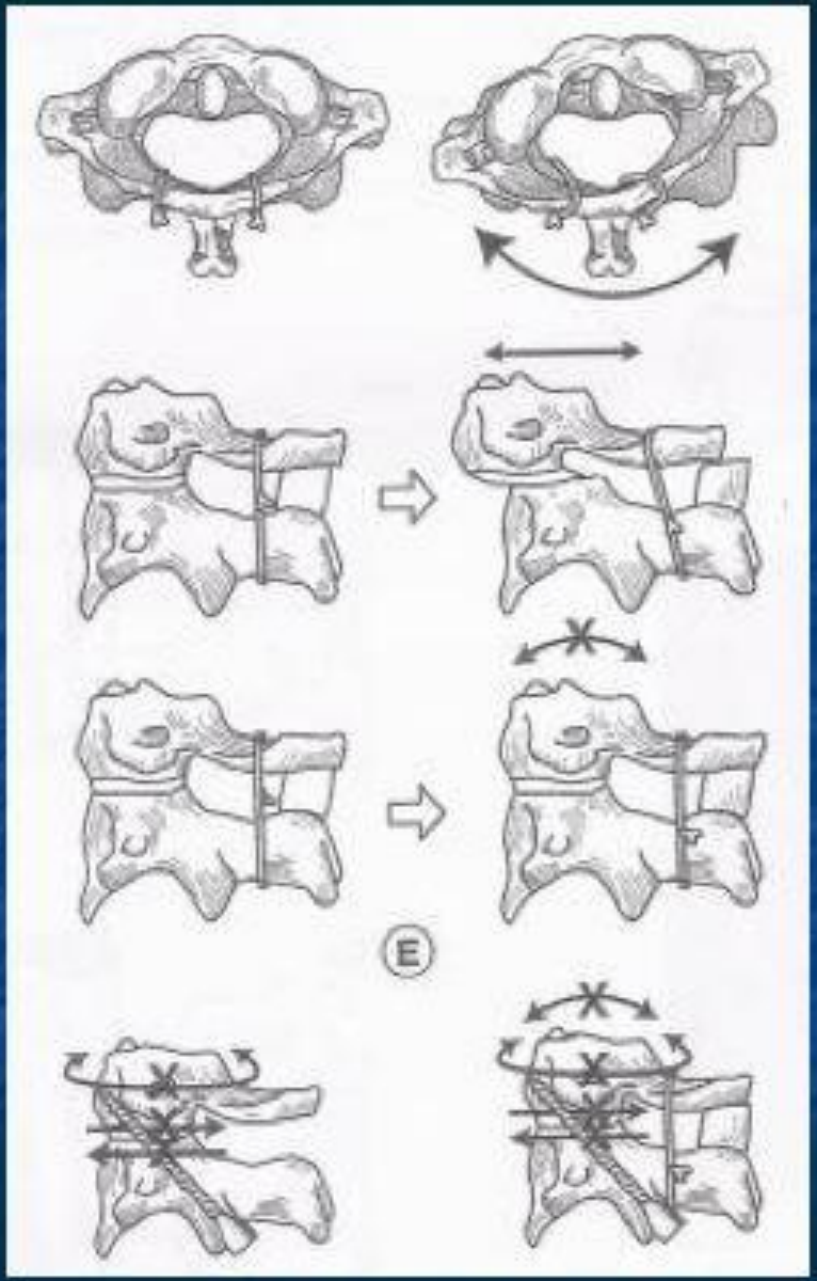

cirurgiadacolunavertebral.com.br

Instrumentação

- Cabos uni ou Multifilamentares
- Hastes em "U" invertido com amarrilho
- Placa-parafuso em "Y" invertido
- Placas Crâniocervicais especiais
- Parafuso Canulado C1C2
- Clamps C1C2
- Ganchos C1C2
- Sistemas de Parafusos e Hastes ou placas C1-C2

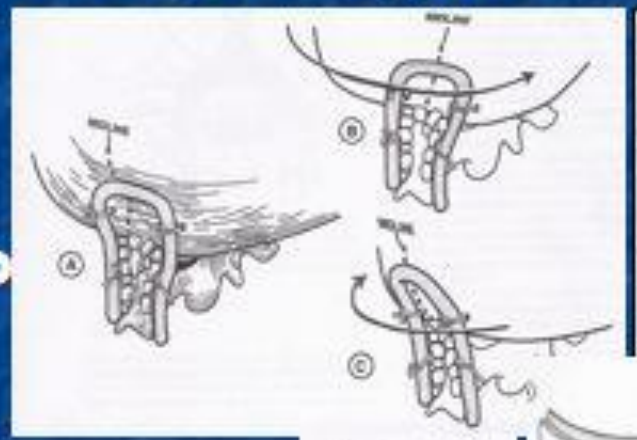

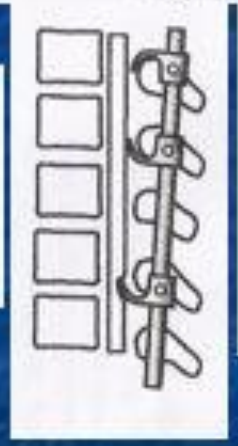

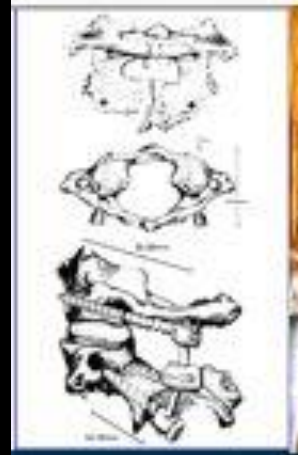

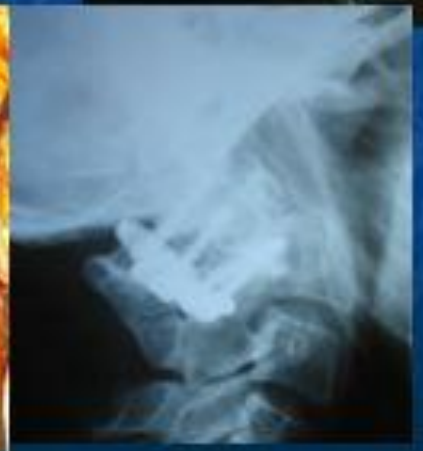

cirurgiadacolunavertebral.com.br

Parafuso Transarticular C1C2

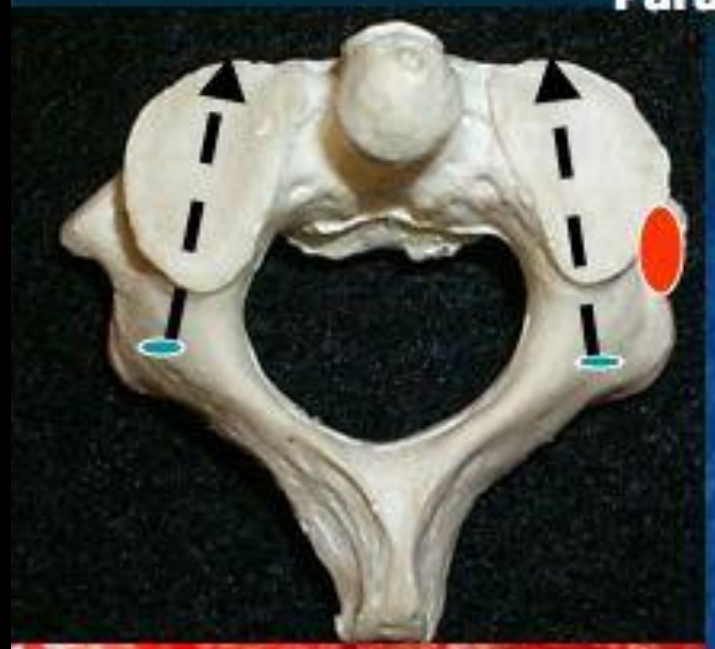

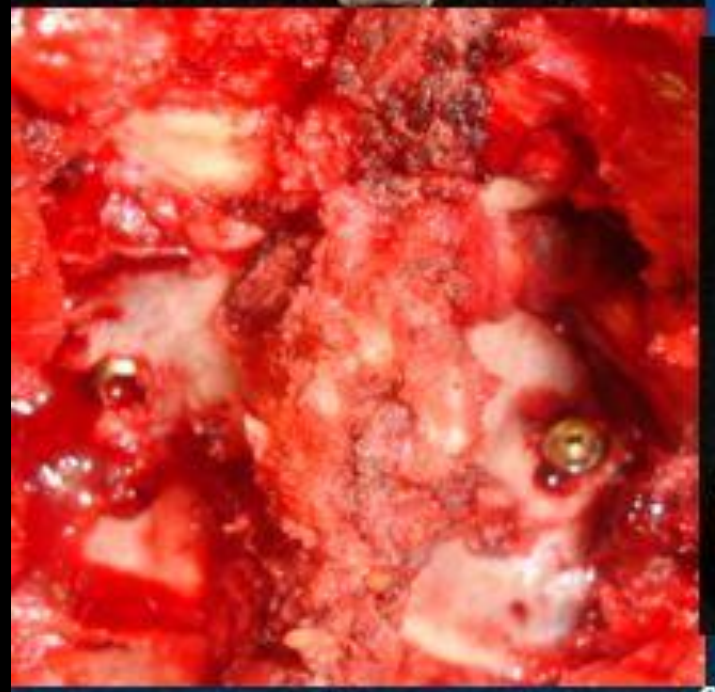

cirurgiadacolunavertebral.com.br

Parafuso Transarticular C1C2 Anterior

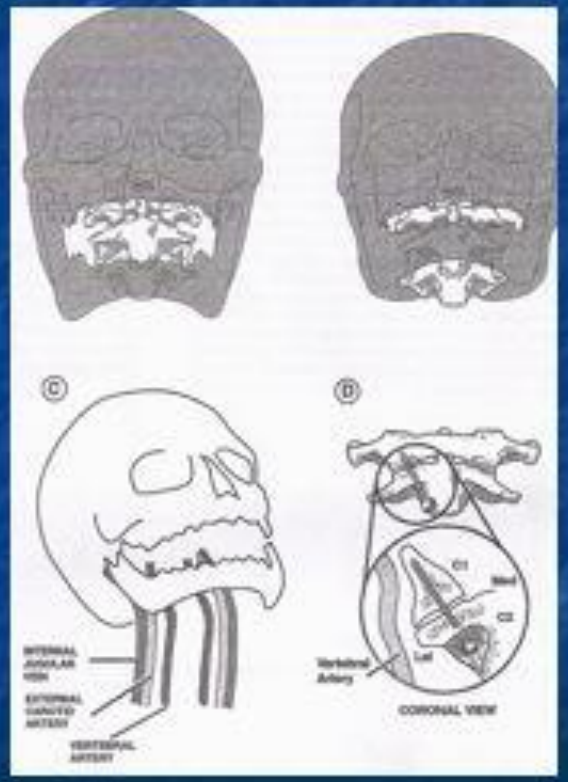

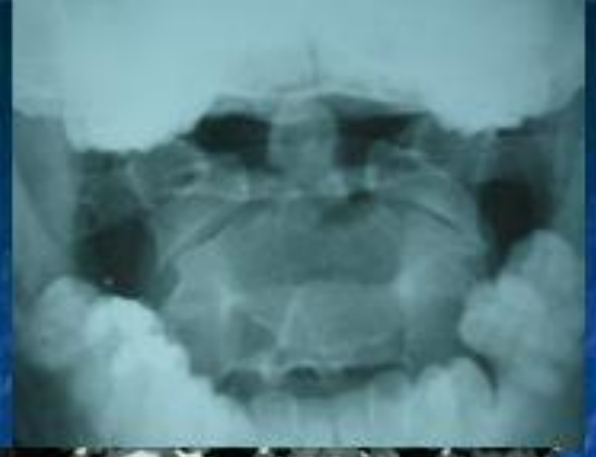

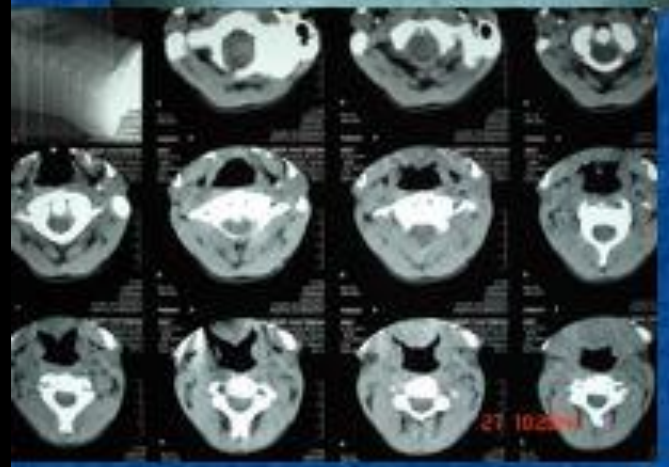

cirurgiadacolunavertebral.com.br

OBRIGADO!

cirurgiadacolunavertebral.com.br