

V CONGRESSO DE CIRURGIA
ESPINHAL DE SÃO PAULO

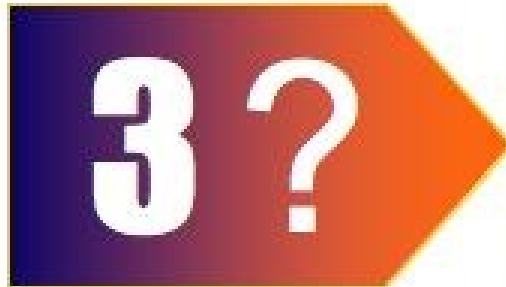E **VII** JORNADA DE
CIRURGIA ESPINHAL

**Fraturas
Toracolumbares**

Helton Defino

Faculdade de Medicina de Ribeirão Preto
USP





■ Conservador/Cirúrgico

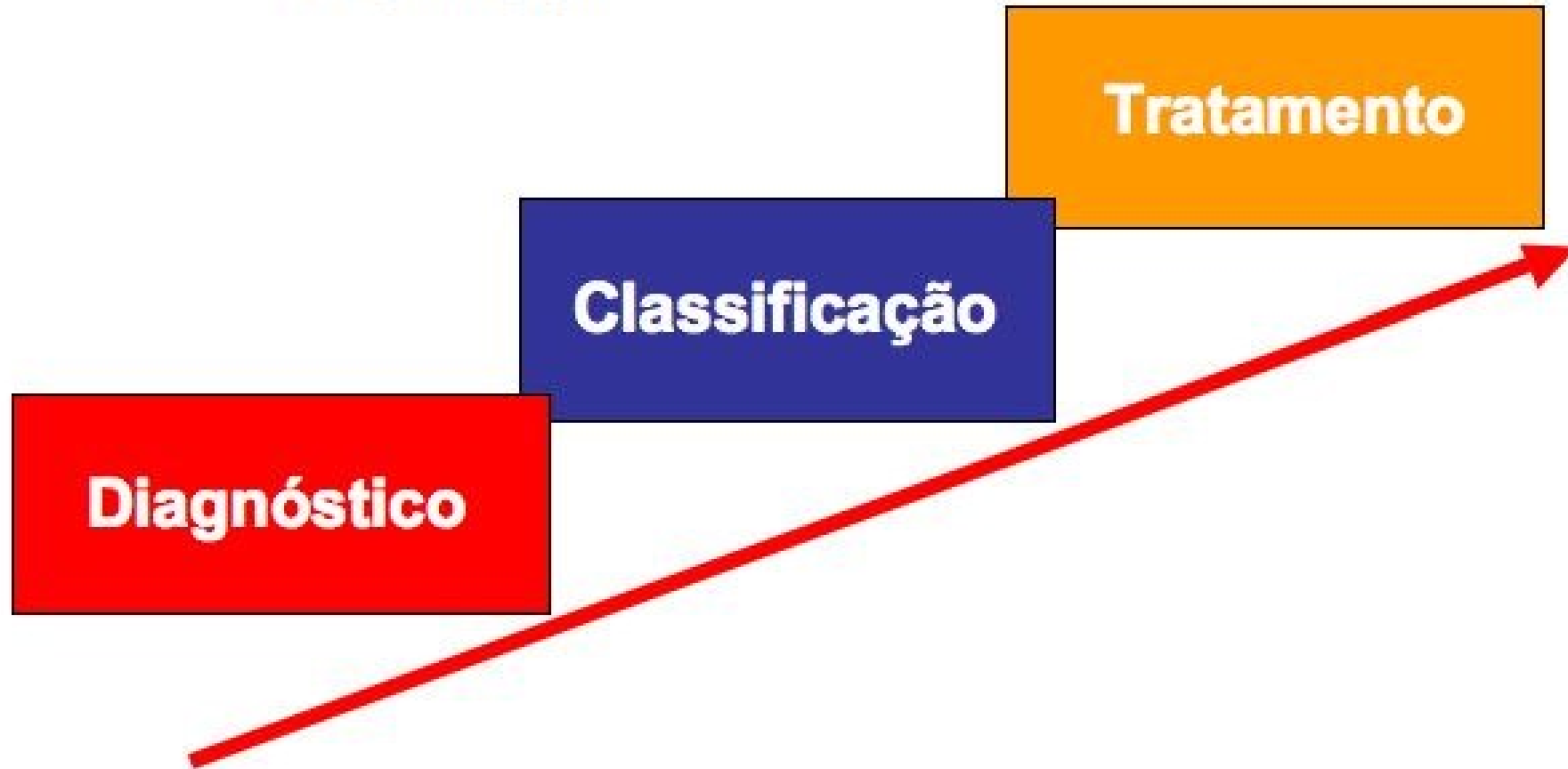
■ Método

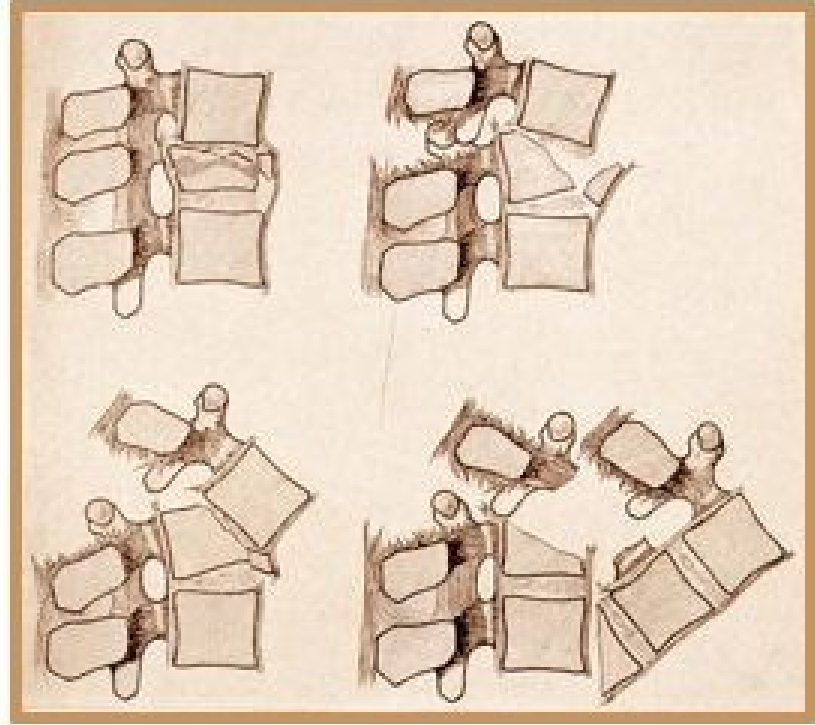
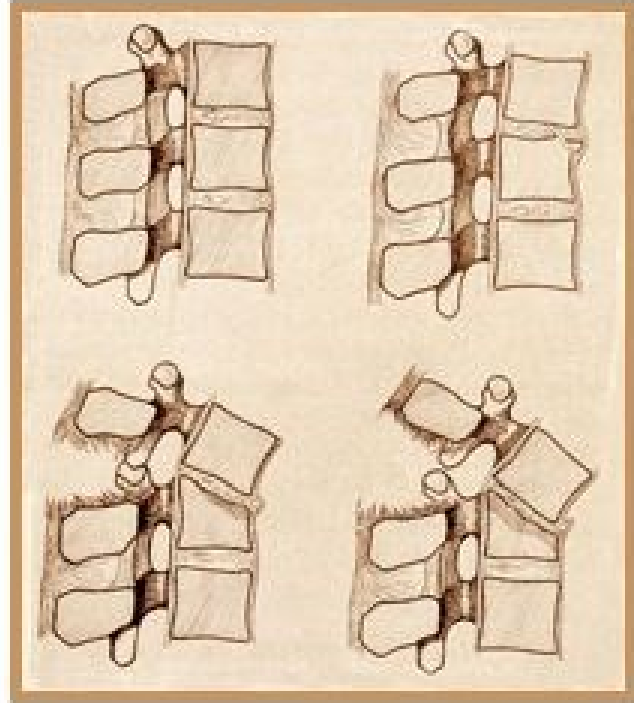
- Conservador
 - Repouso
 - Colete
 - Gesso
- Cirúrgico
 - Artrodese-curta/longa
 - Fixação
 - Descompressão

■ Abordagem

- Anterior
- Posterior
- Combinada

Lesões Torácica e Lombar





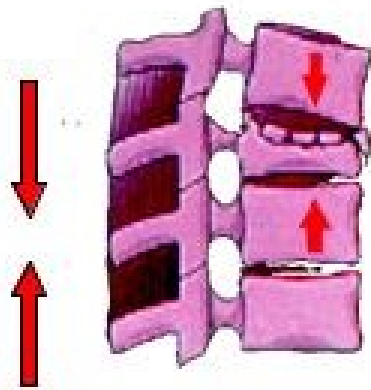
Böhler, 1935

Classificação AO

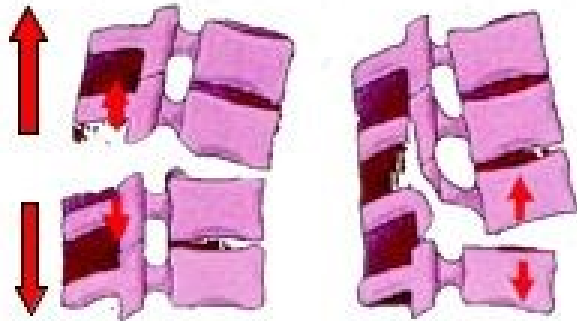
Compressão

Distração

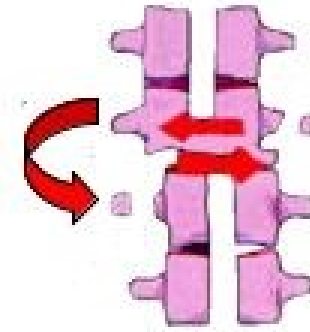
Rotação



A



B



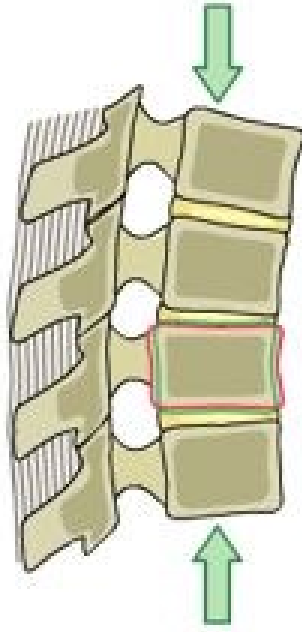
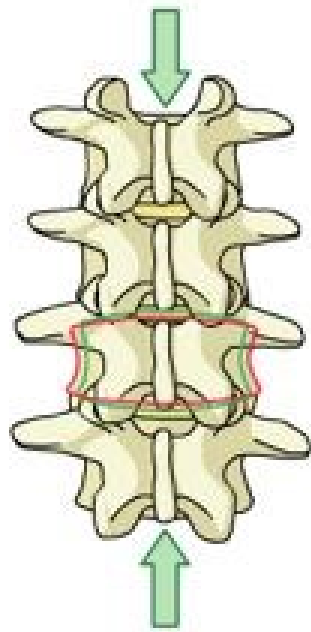
C

A - ↓ altura corpo vertebral - **compressão**

B - rotura A/P - **distração**

C - desvio rotacional - **rotação**

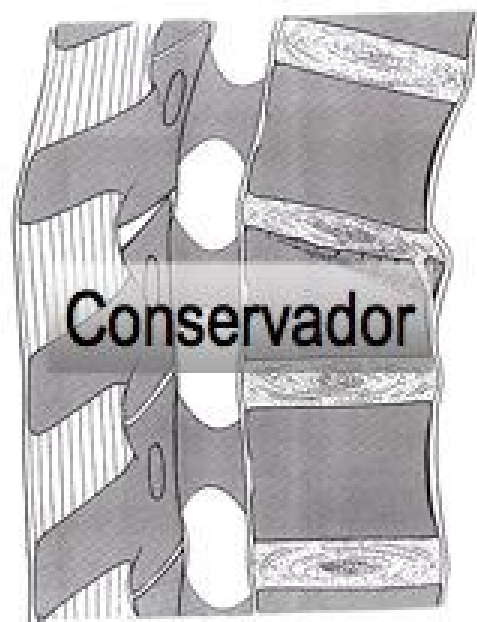
Tipo A - COMPRESSÃO



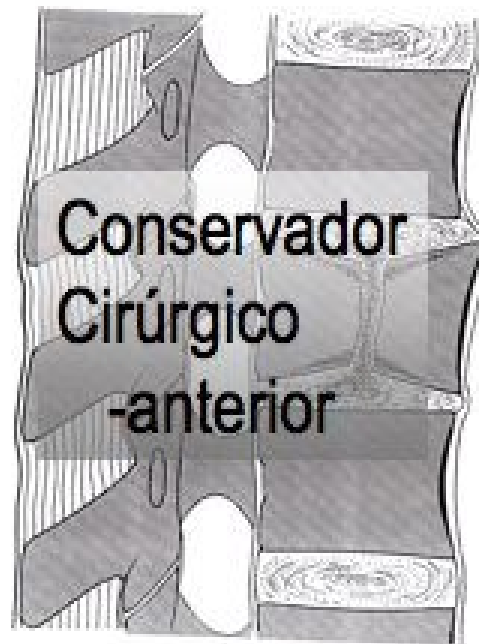
A

Compression

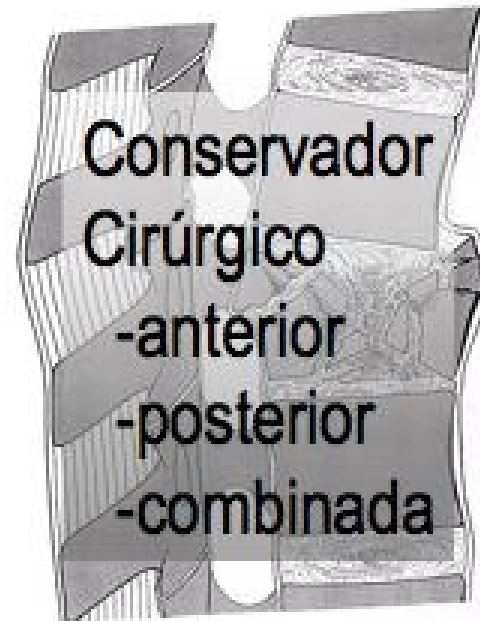Tipo A COMPRESSÃO



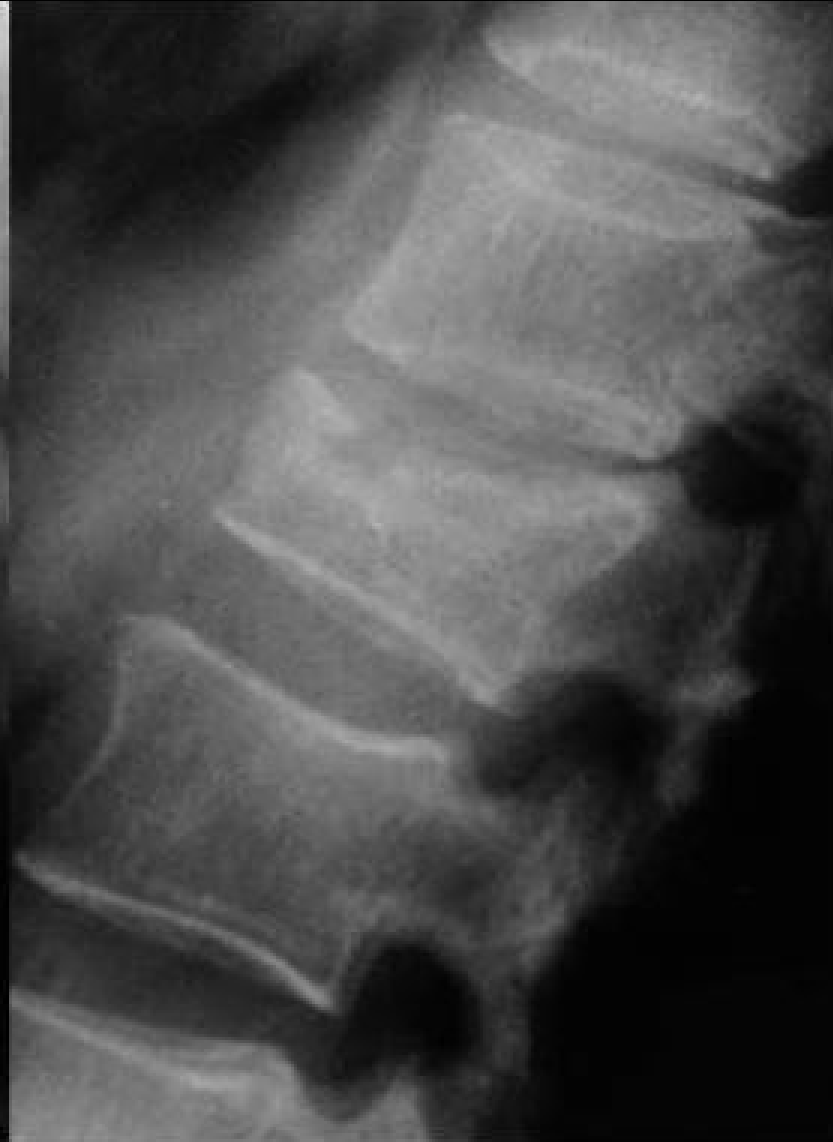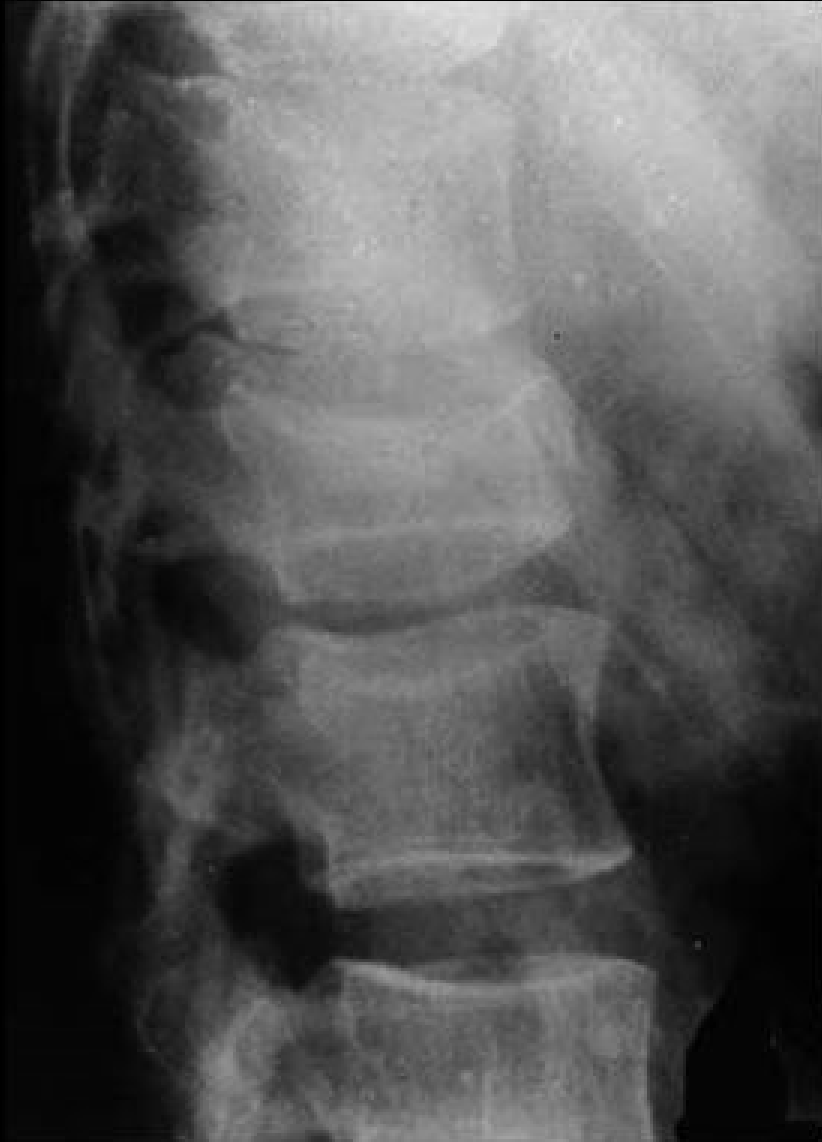A1
impacção



A2
"split"

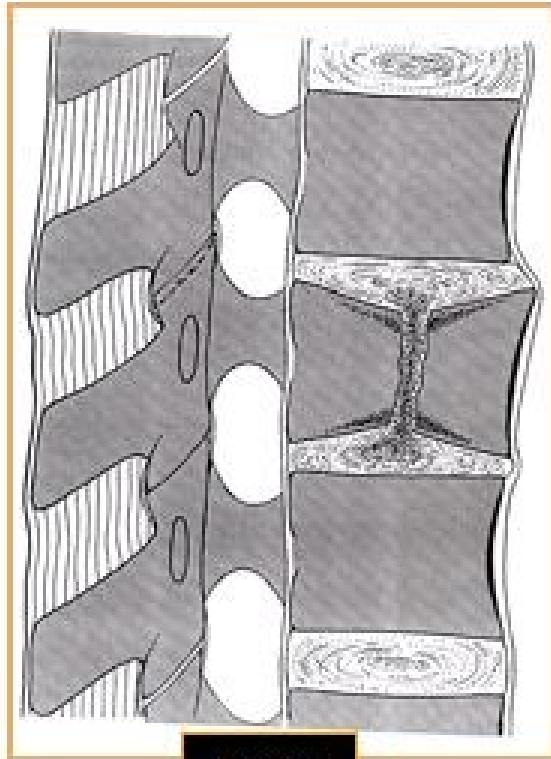


A3
explosão

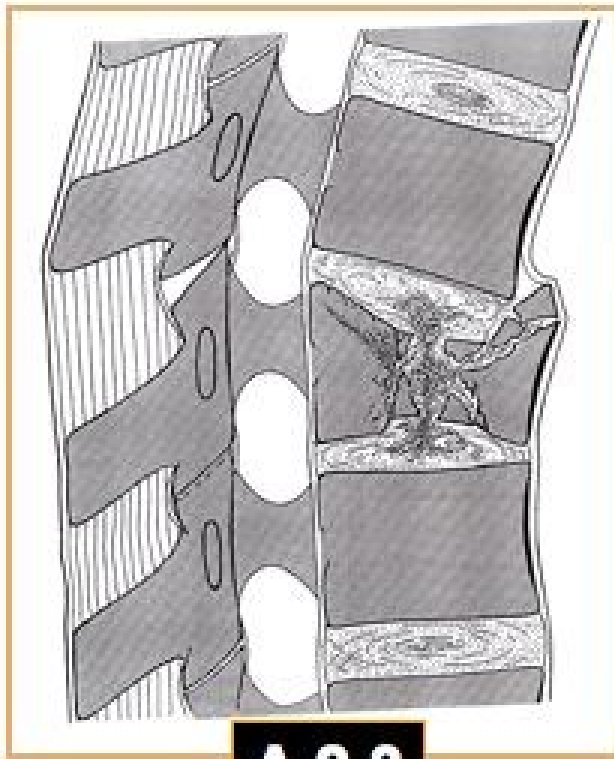


A2

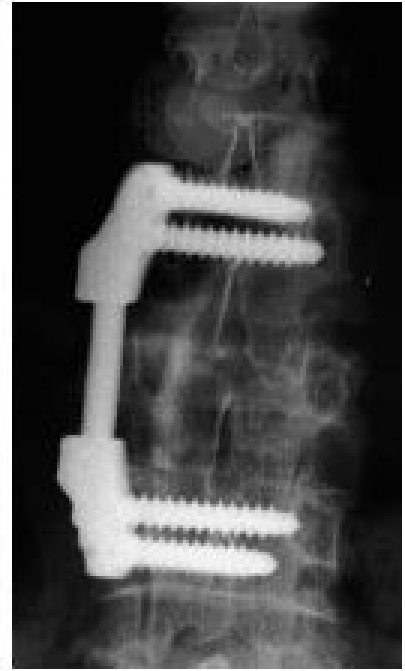
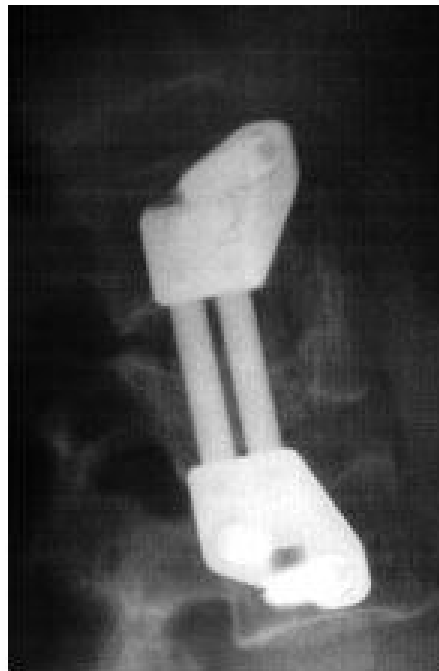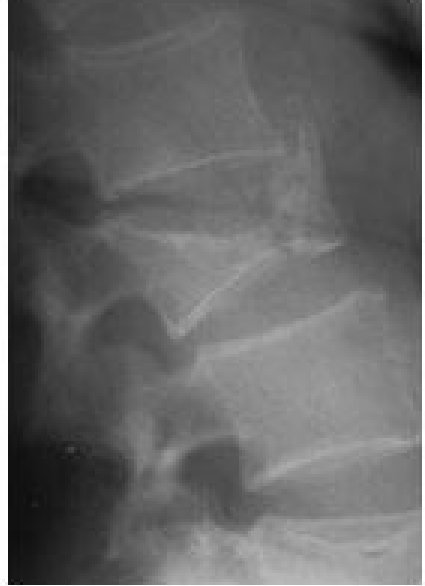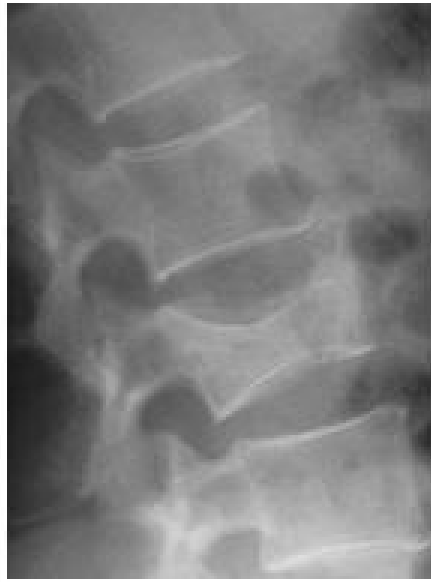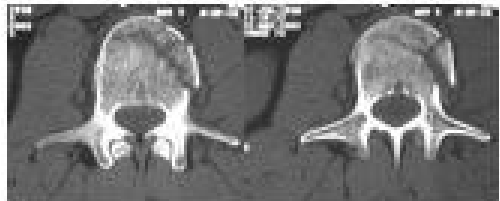
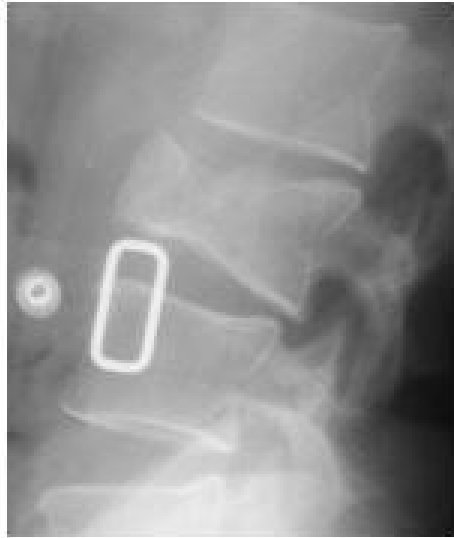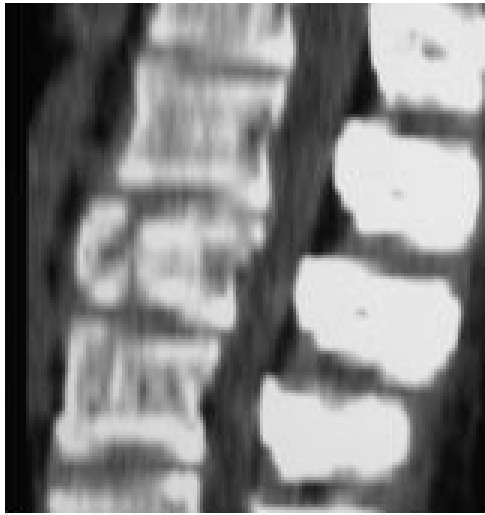
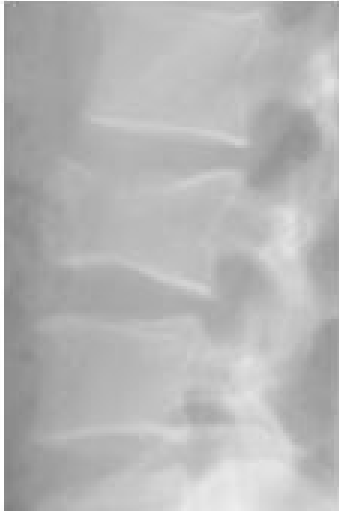“split”



A2.2



A2.3

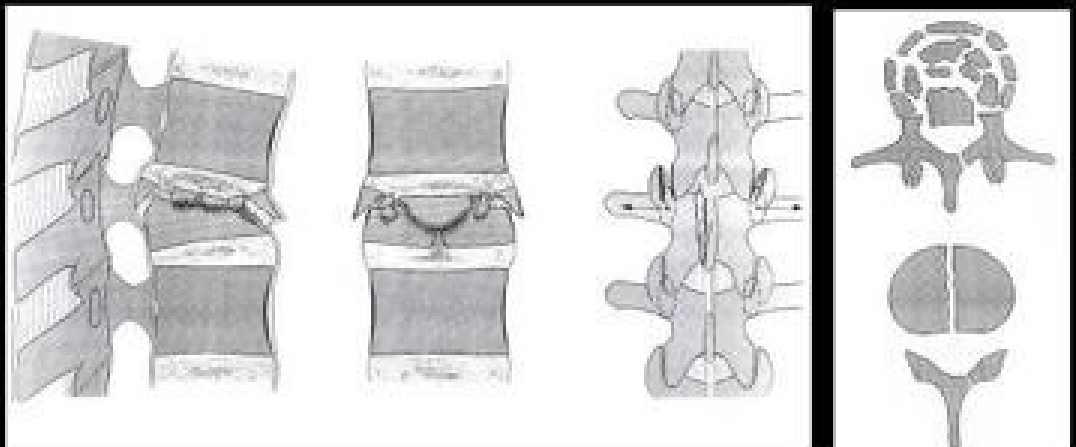


A1

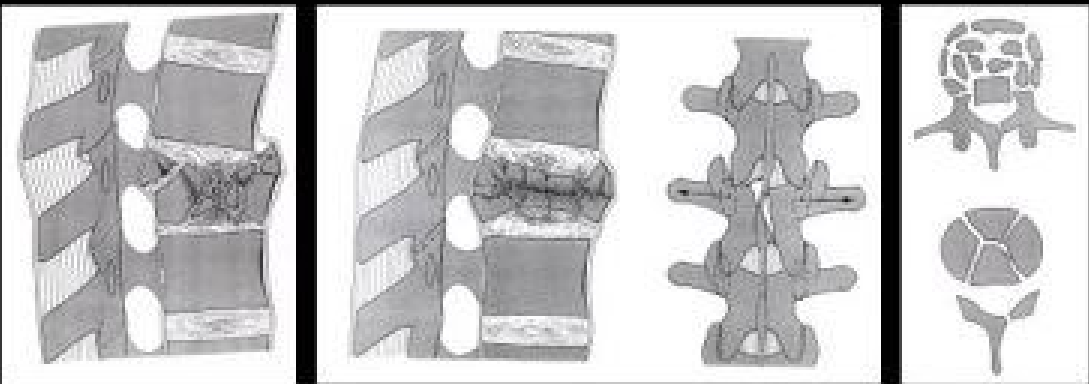


A3 Explosão

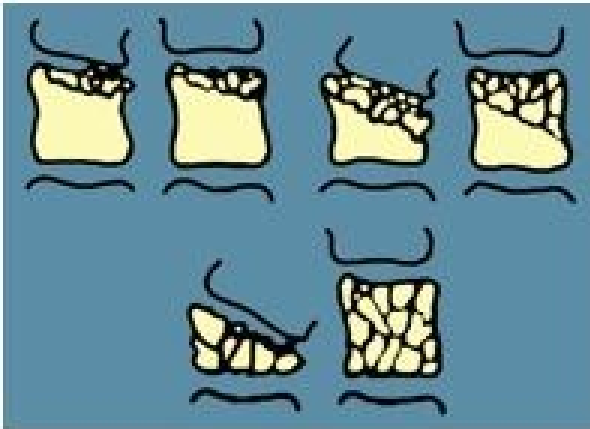
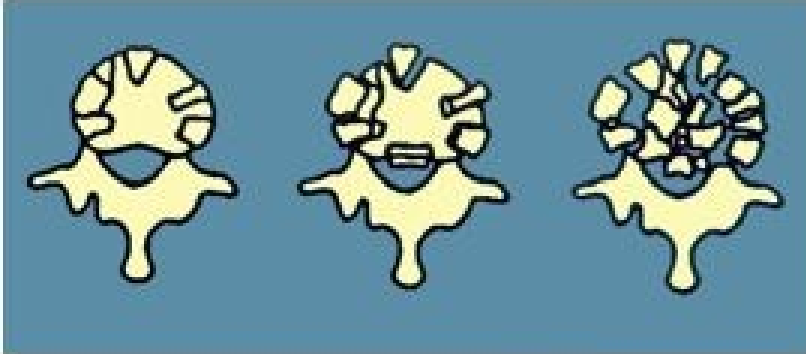
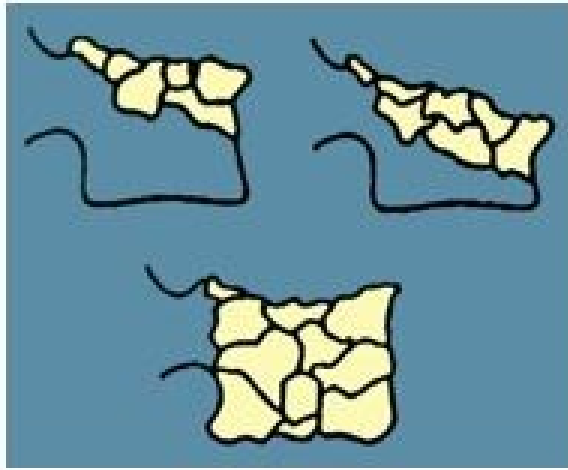
A2



A3

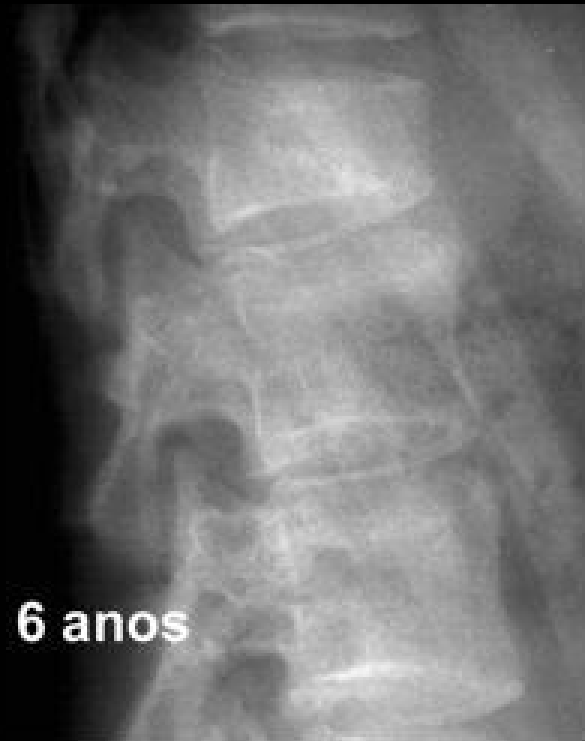
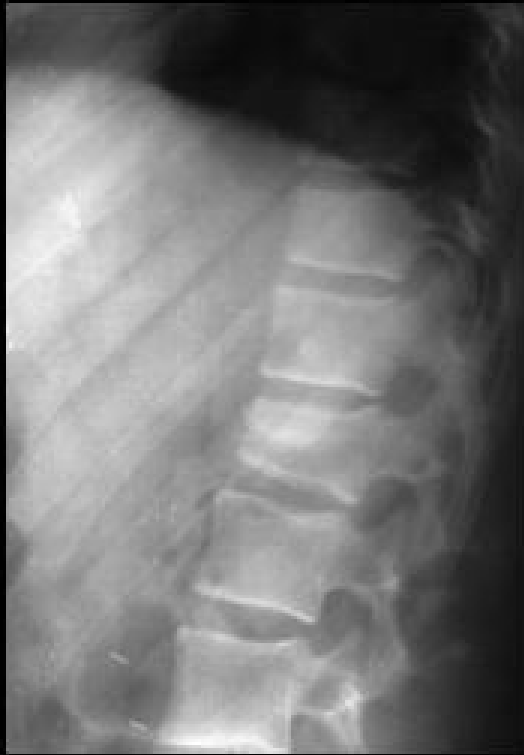
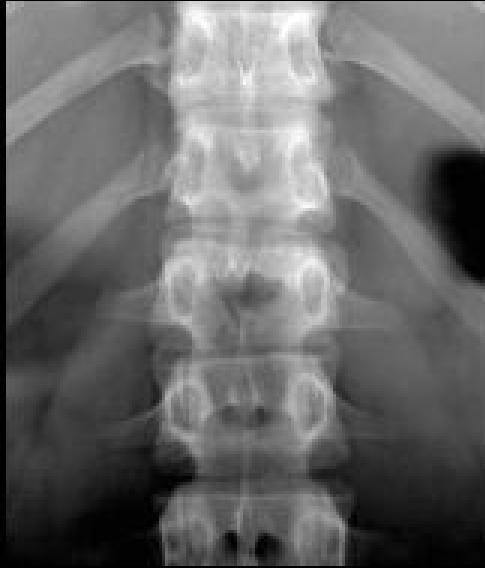Decisão Terapêutica

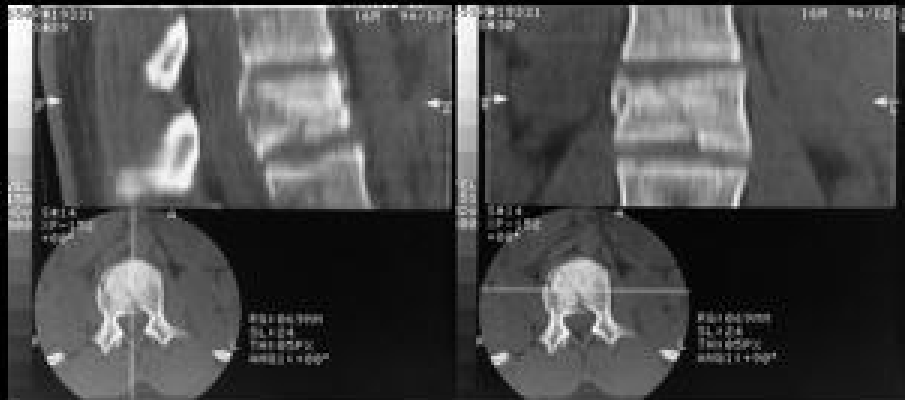

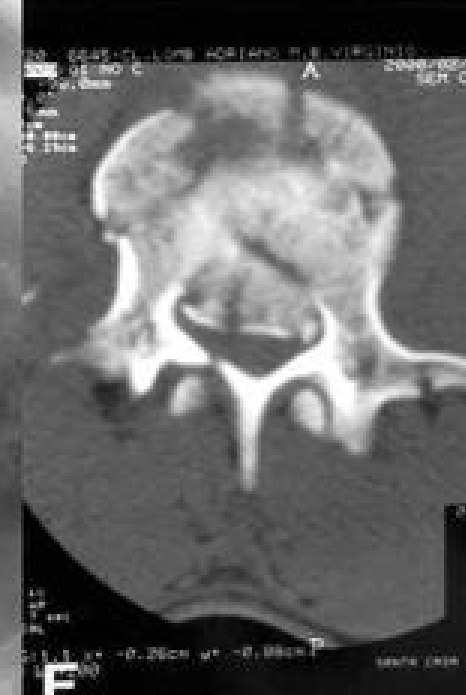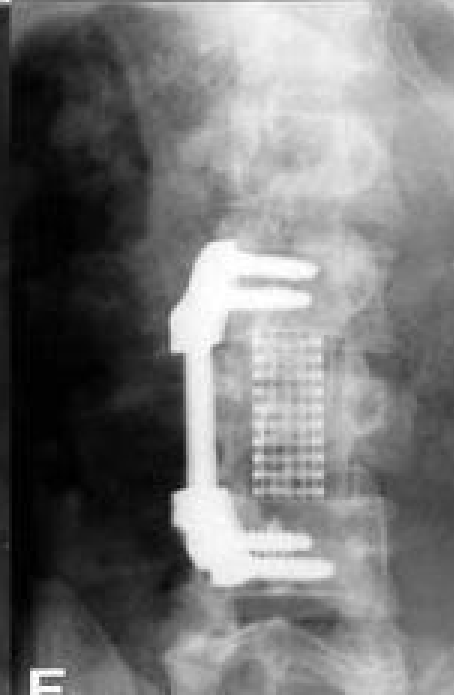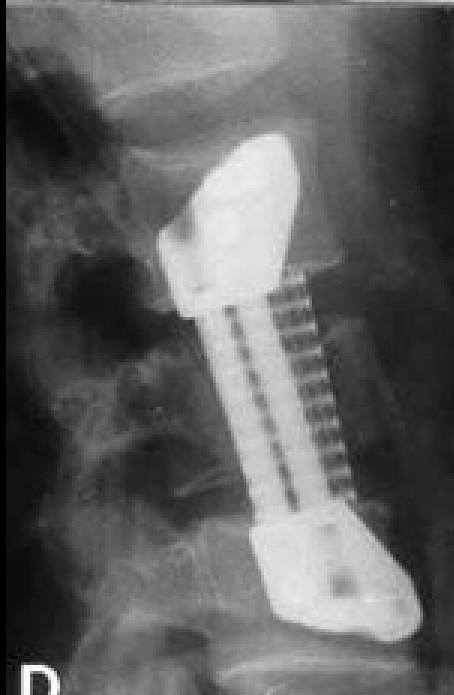
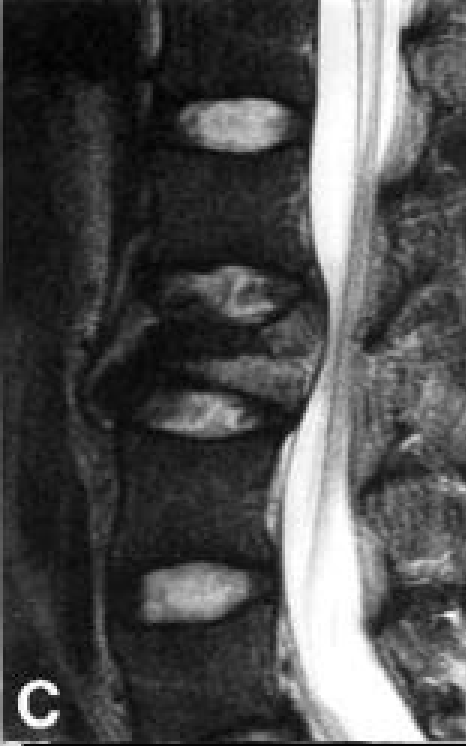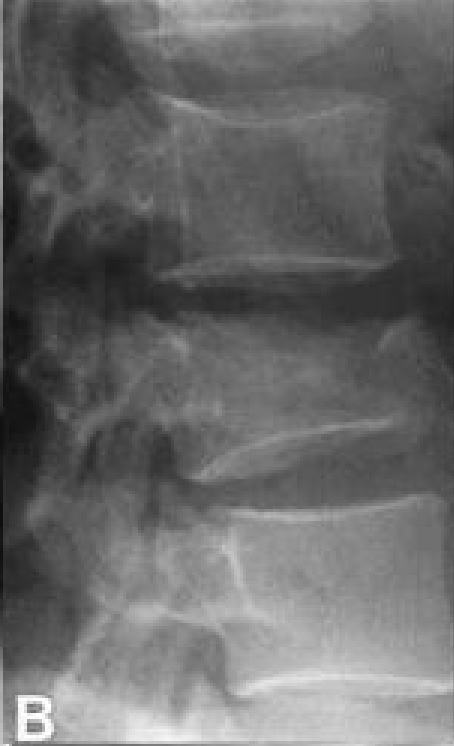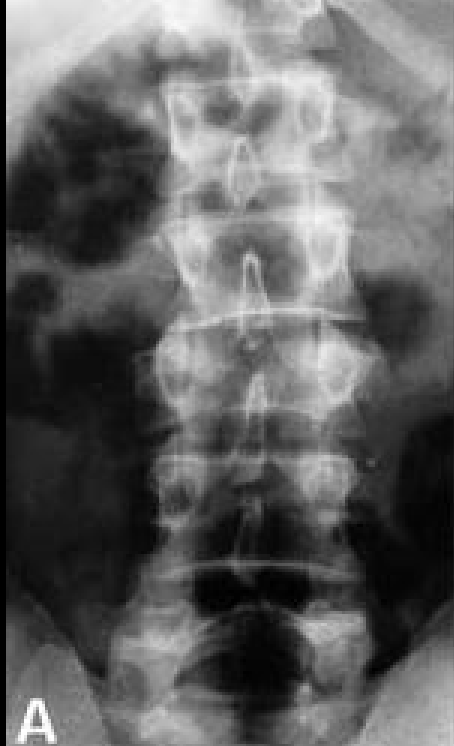- Tipo da fratura (A,B,C)
- Lesão neurológica
- Canal vertebral- >50%
- Lesões associadas

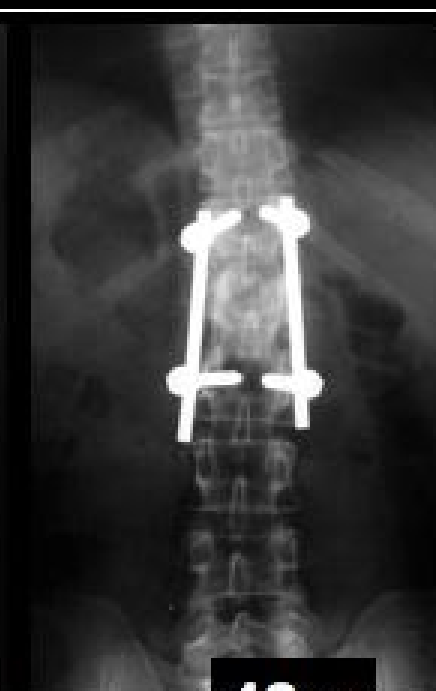
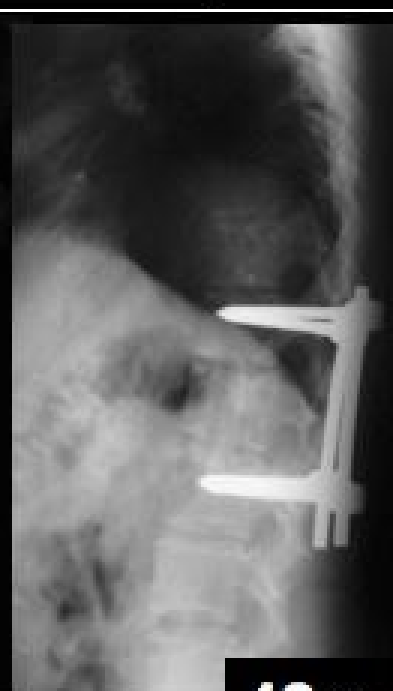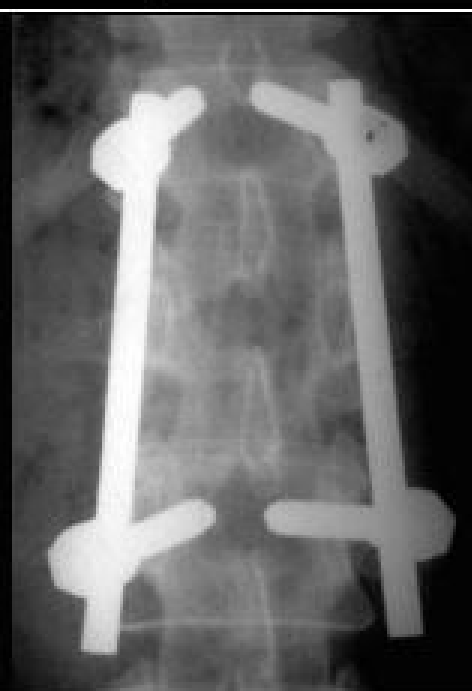
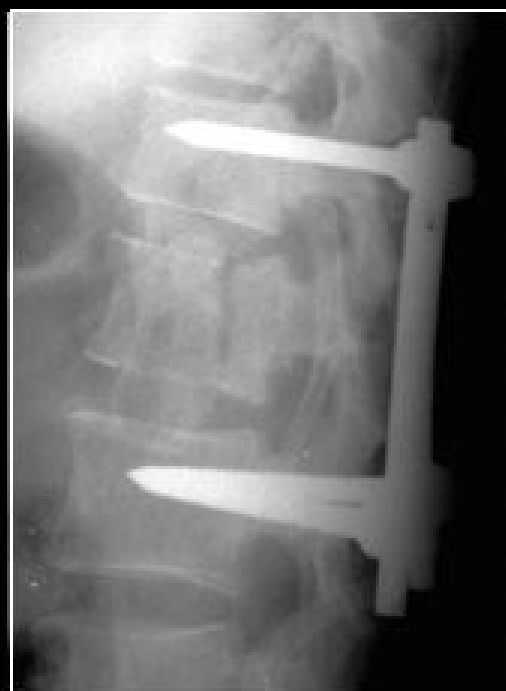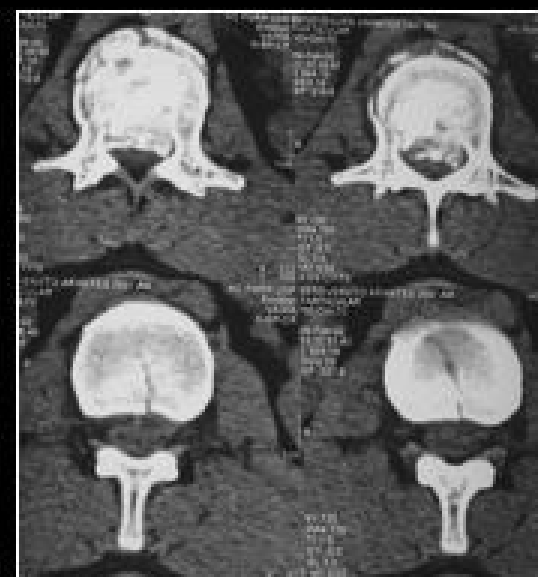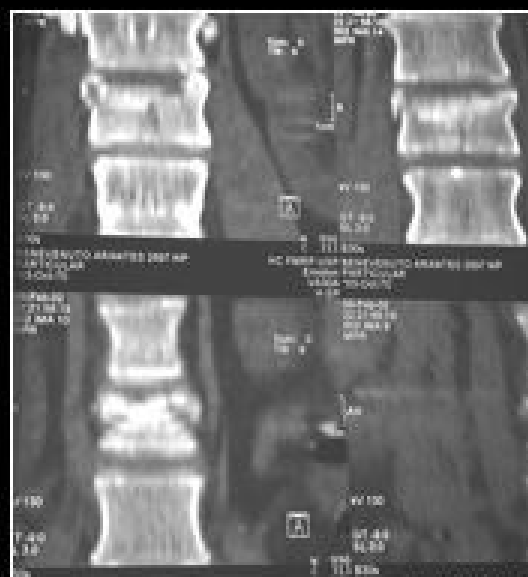
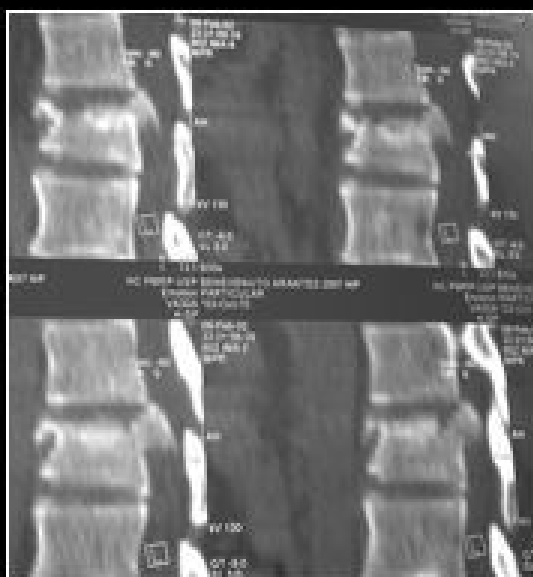“Filosofia do Cirurgião”
“Recursos”



6 anos





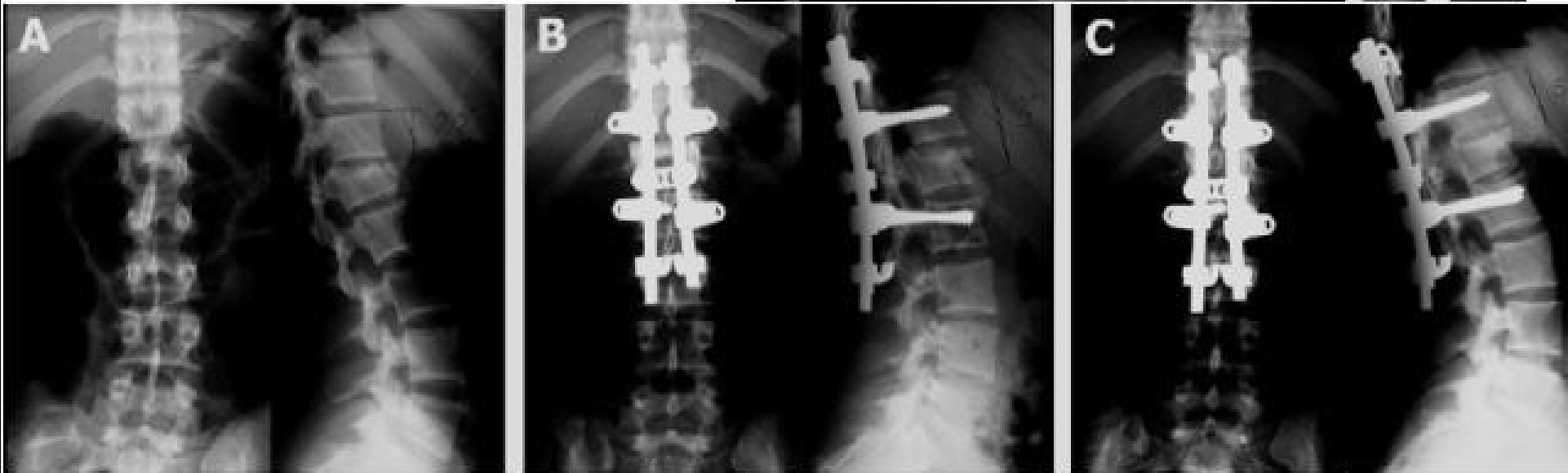


12m

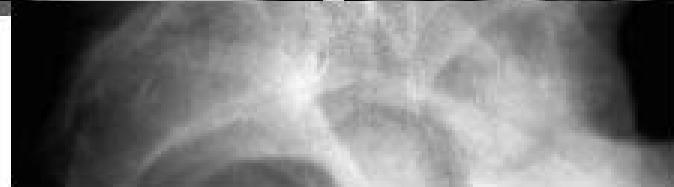12m

Abordagem Posterior

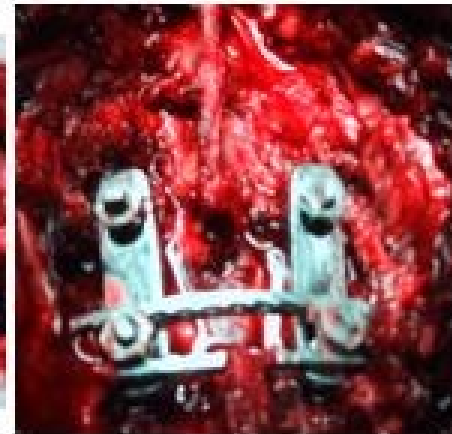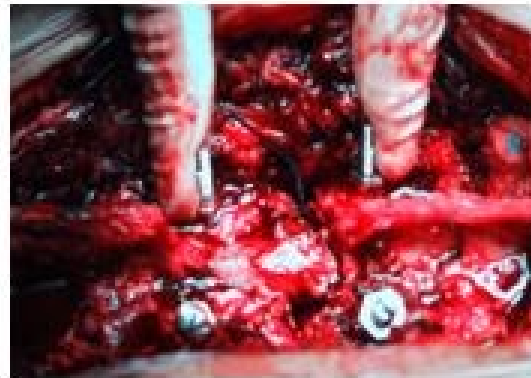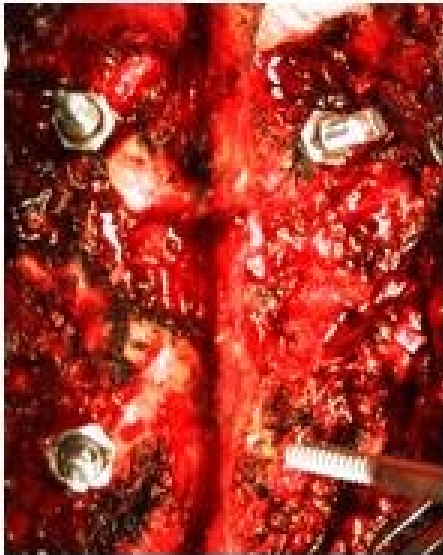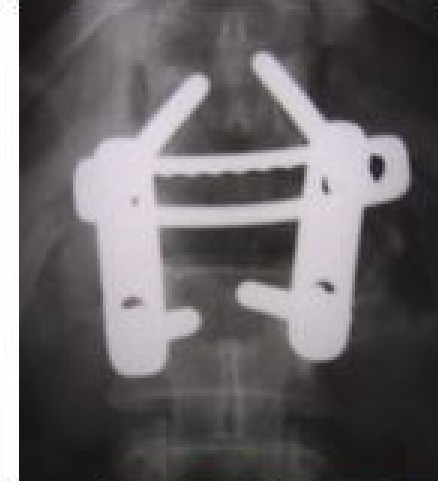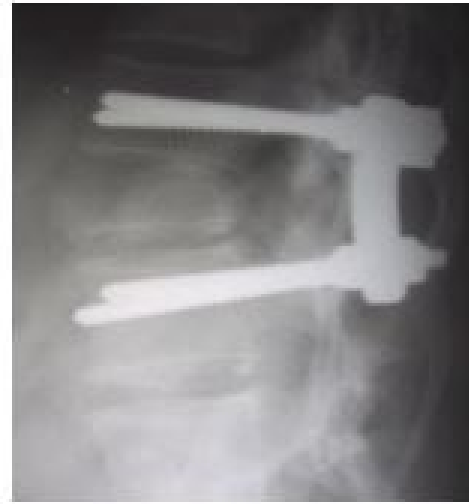- Longas

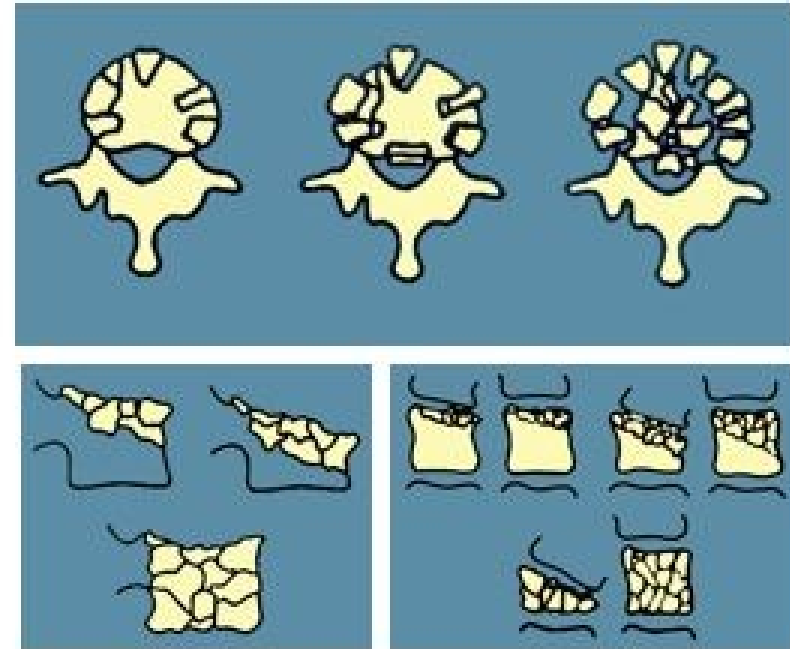

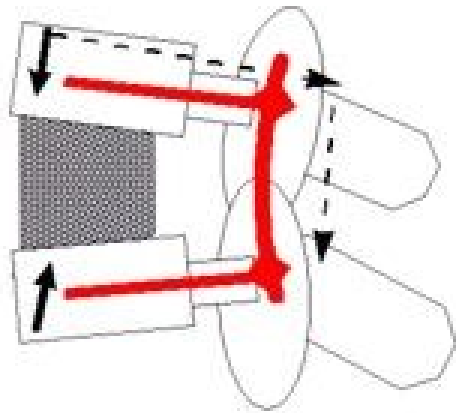
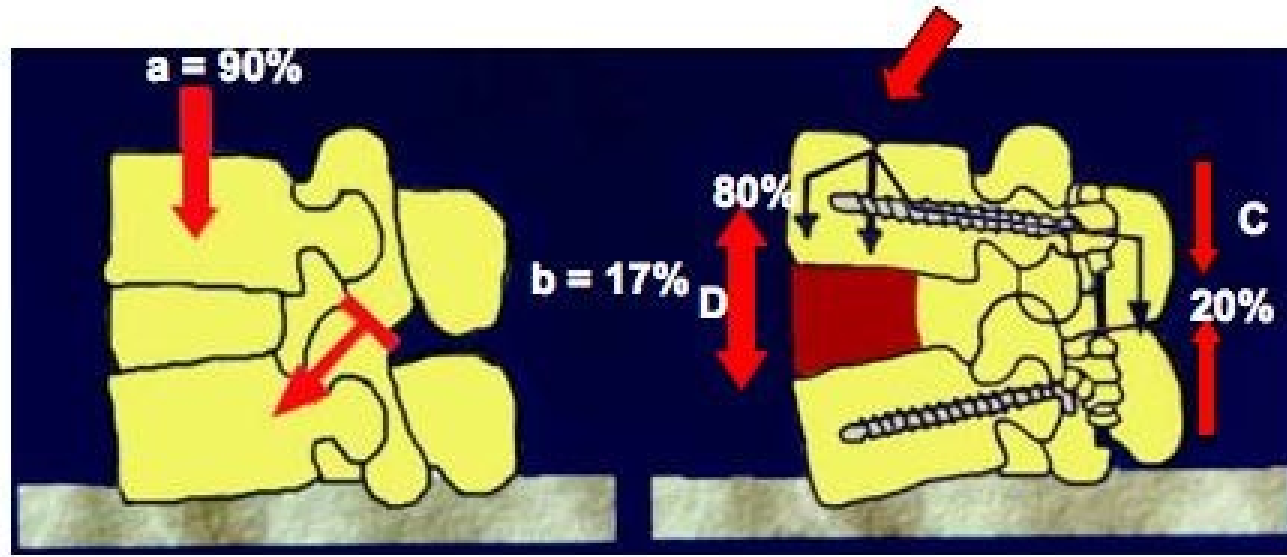


- Osteotomia/
encurtamento



Encurtamento

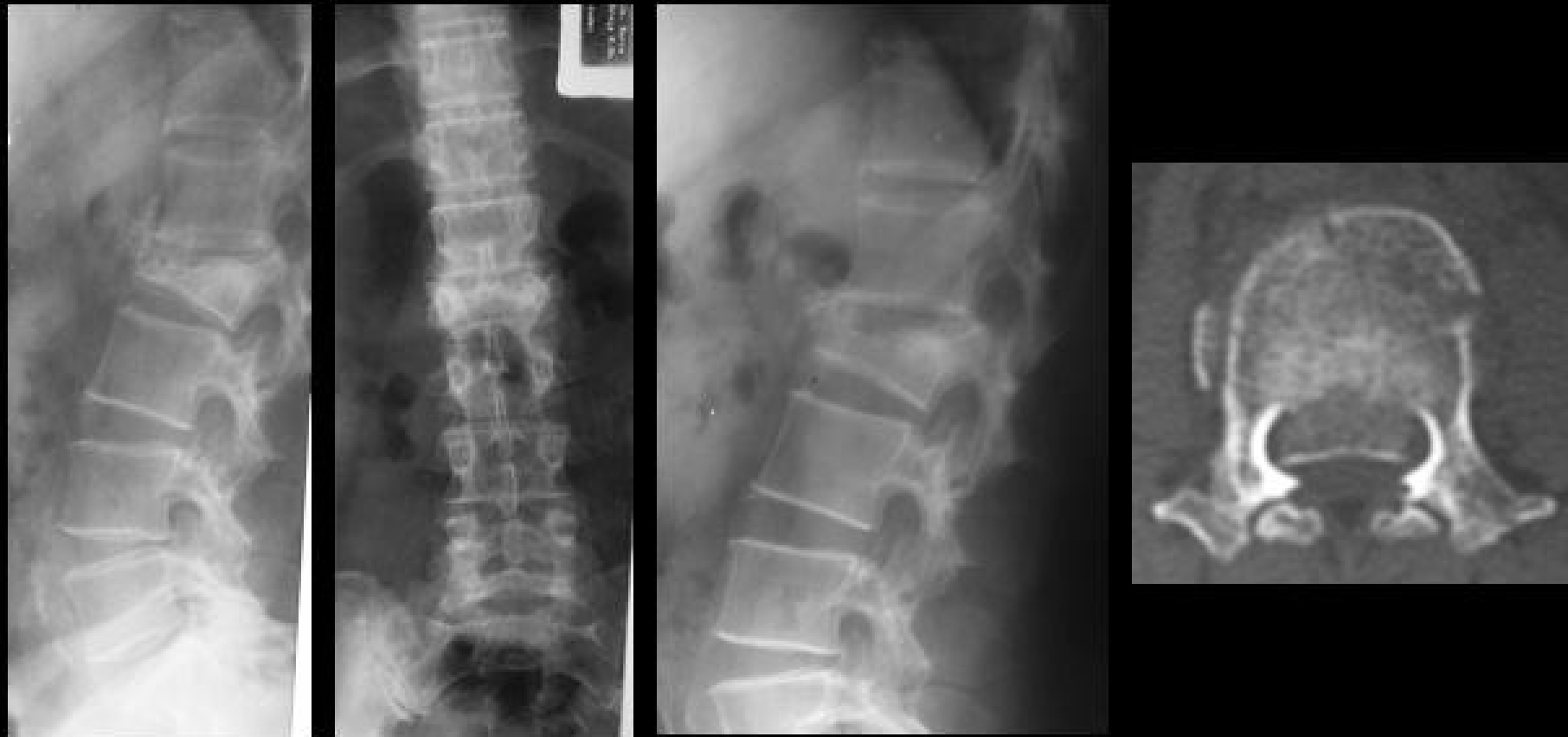




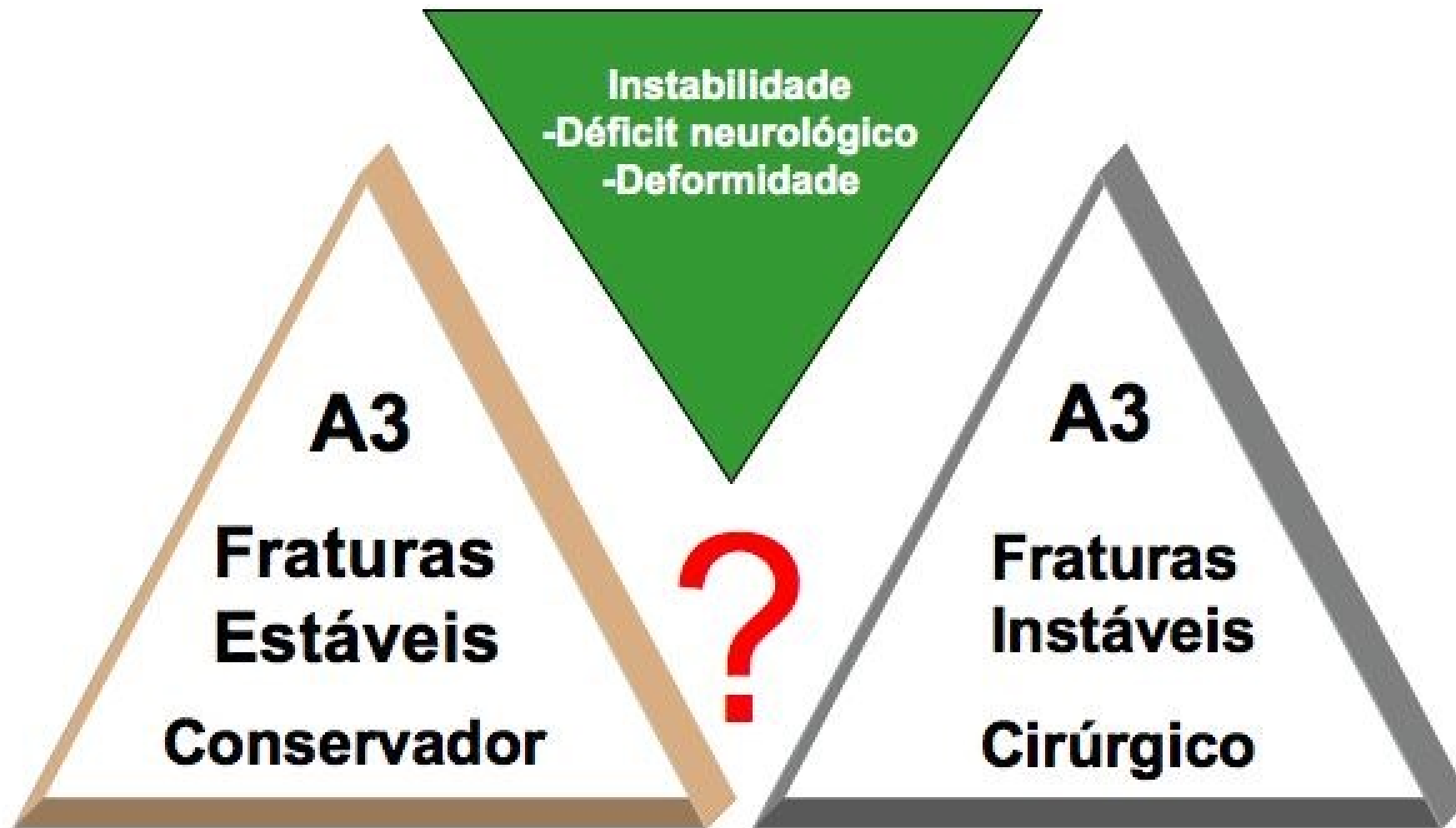
A.3

Indicações Cirúrgicas

- **Lesão Neurológica**
- **↓ altura corpo vertebral > 50%**
- **Angulação > 20 graus**
- **Compressão canal > 50%**
- **Inclinação lateral > 10 graus**



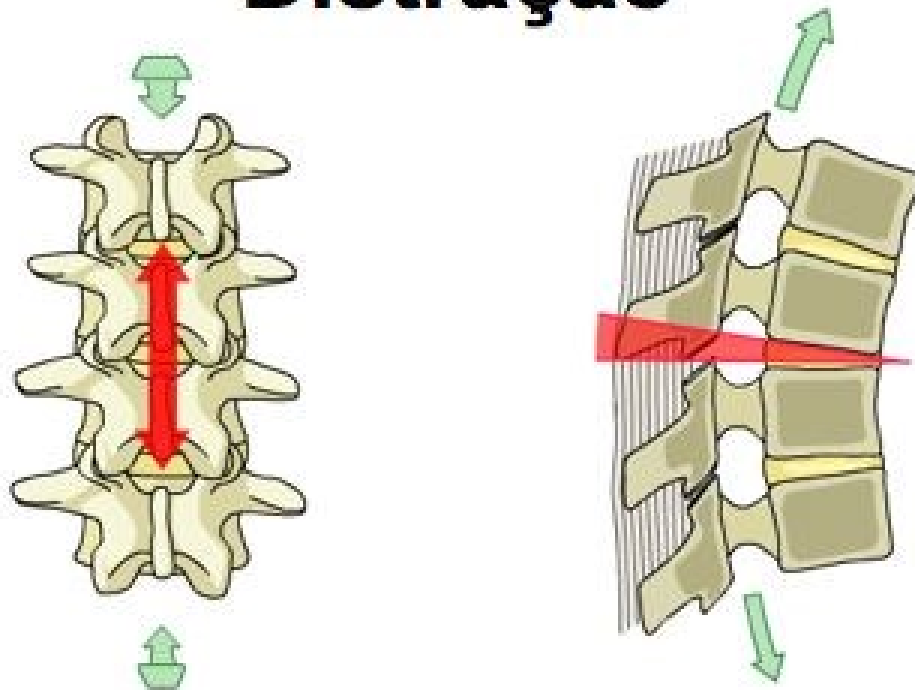
Médica/48 anos/Frankel E / assintomática / trabalho normal



Cirurgião
Recursos

Tipo B

Distração



Lesão óssea (Chance) - conservador

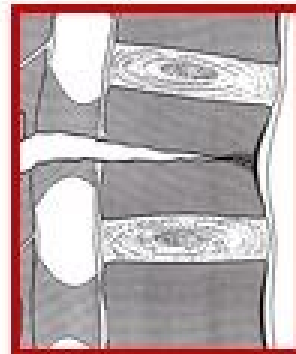


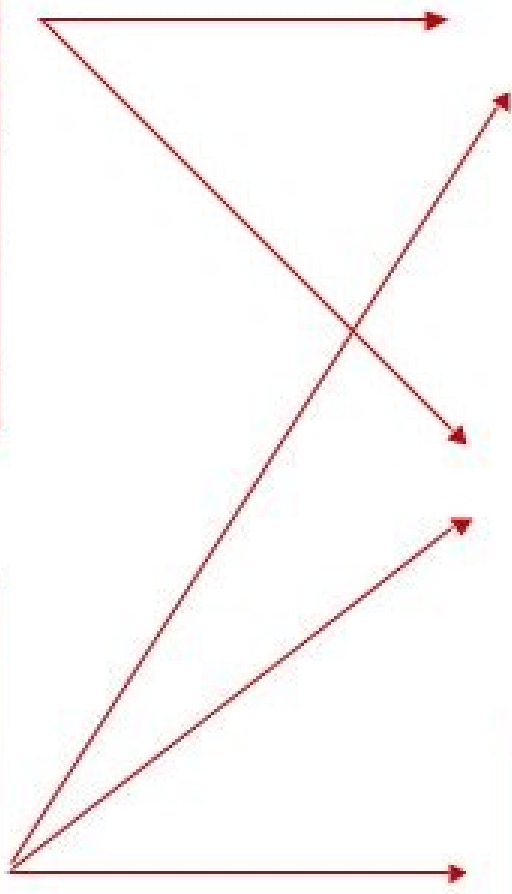
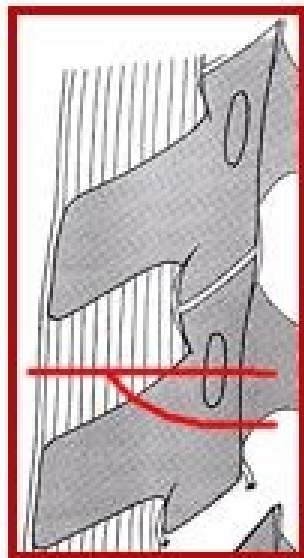
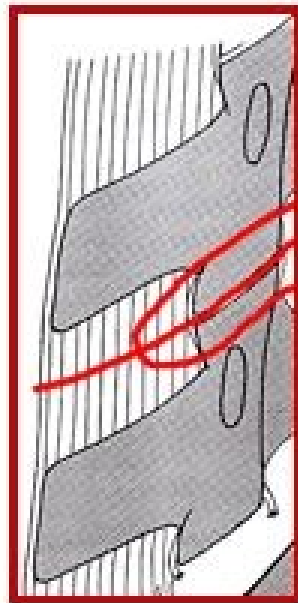
Lesão ligamentar - cirúrgico

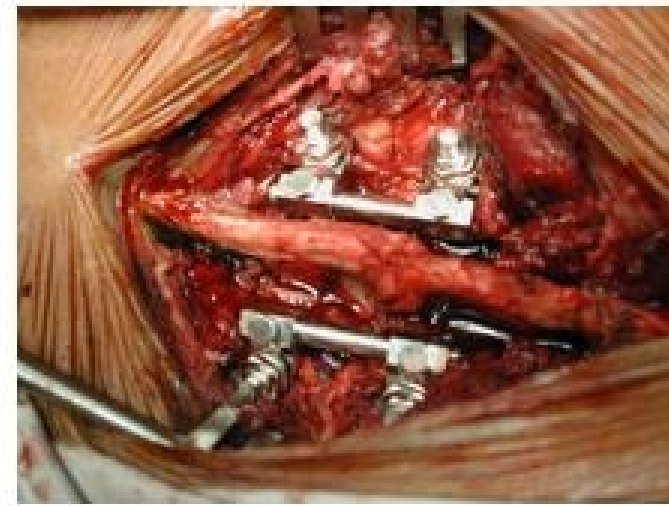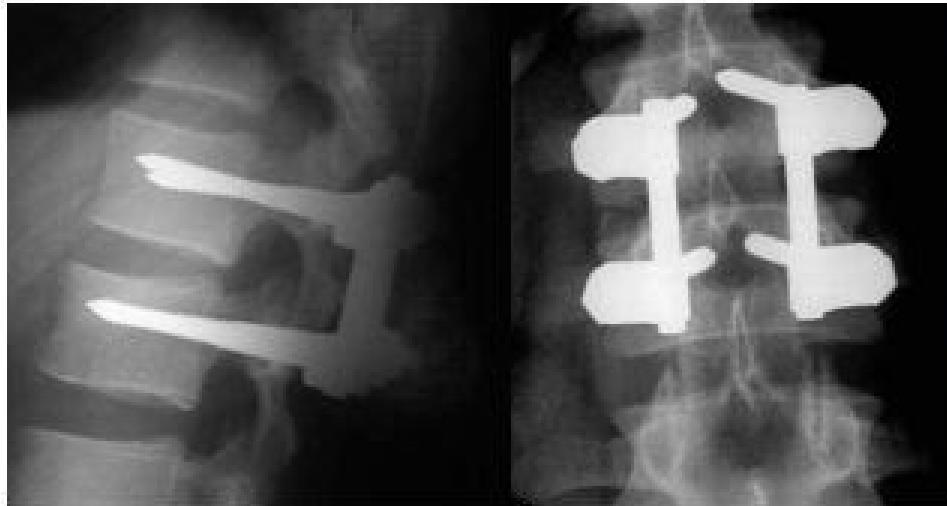
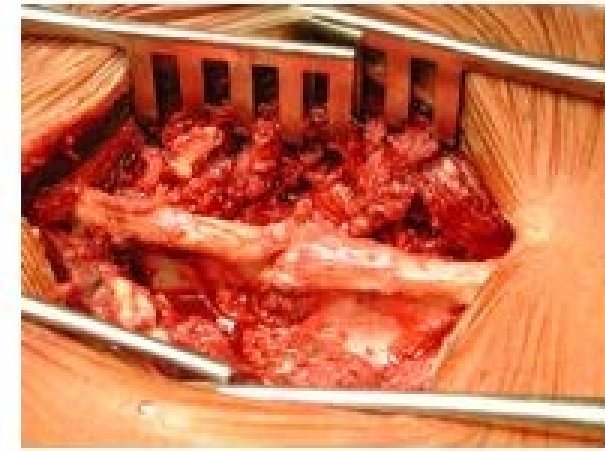
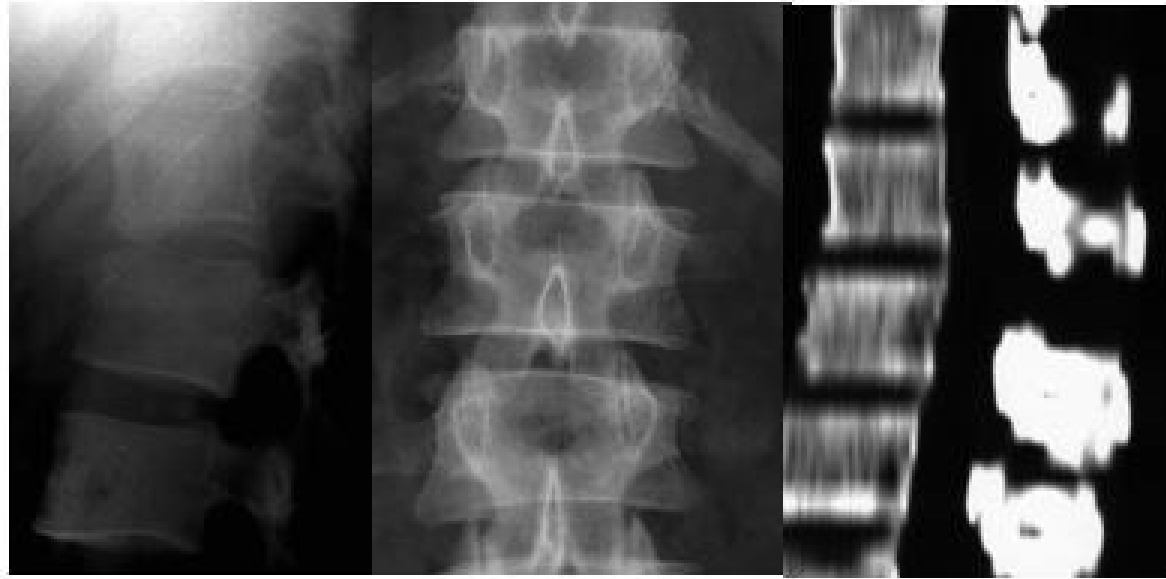
Fixação posterior

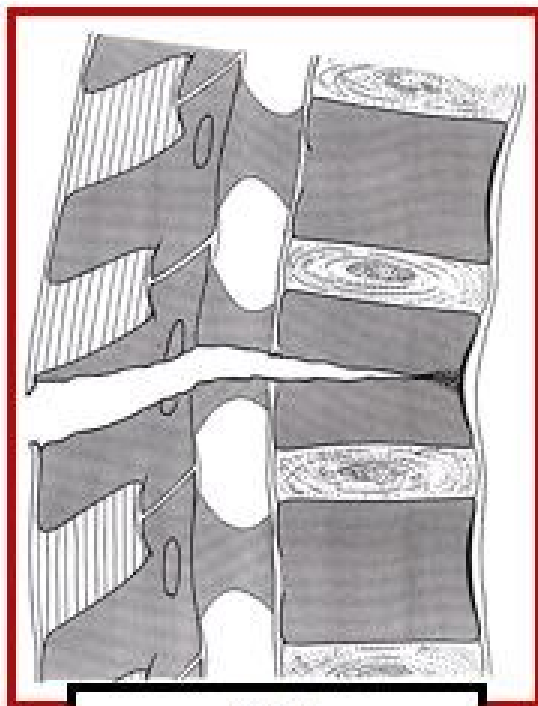
Fixação combinada (coluna anterior)

Tipo B

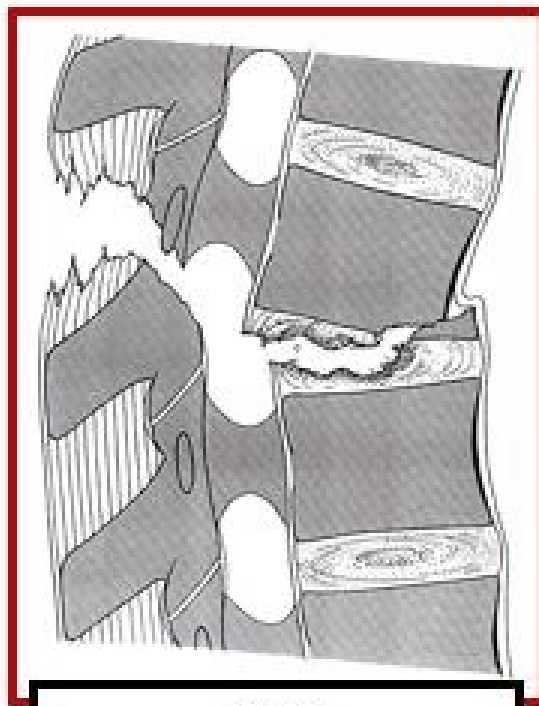
Lesão Posterior



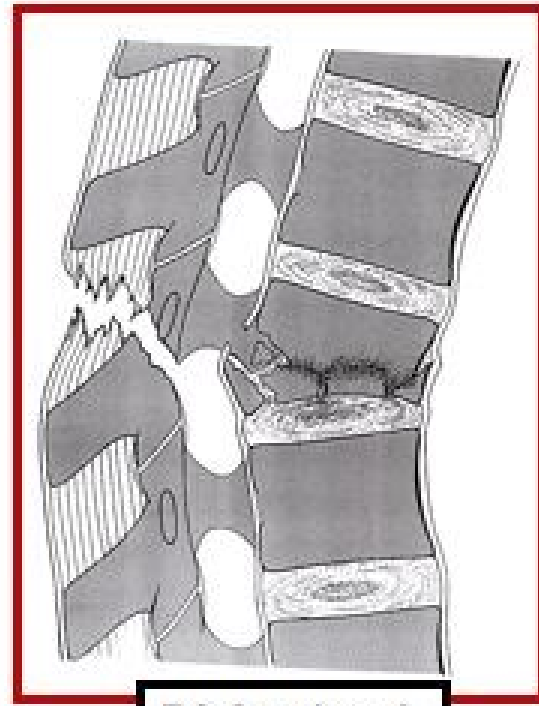




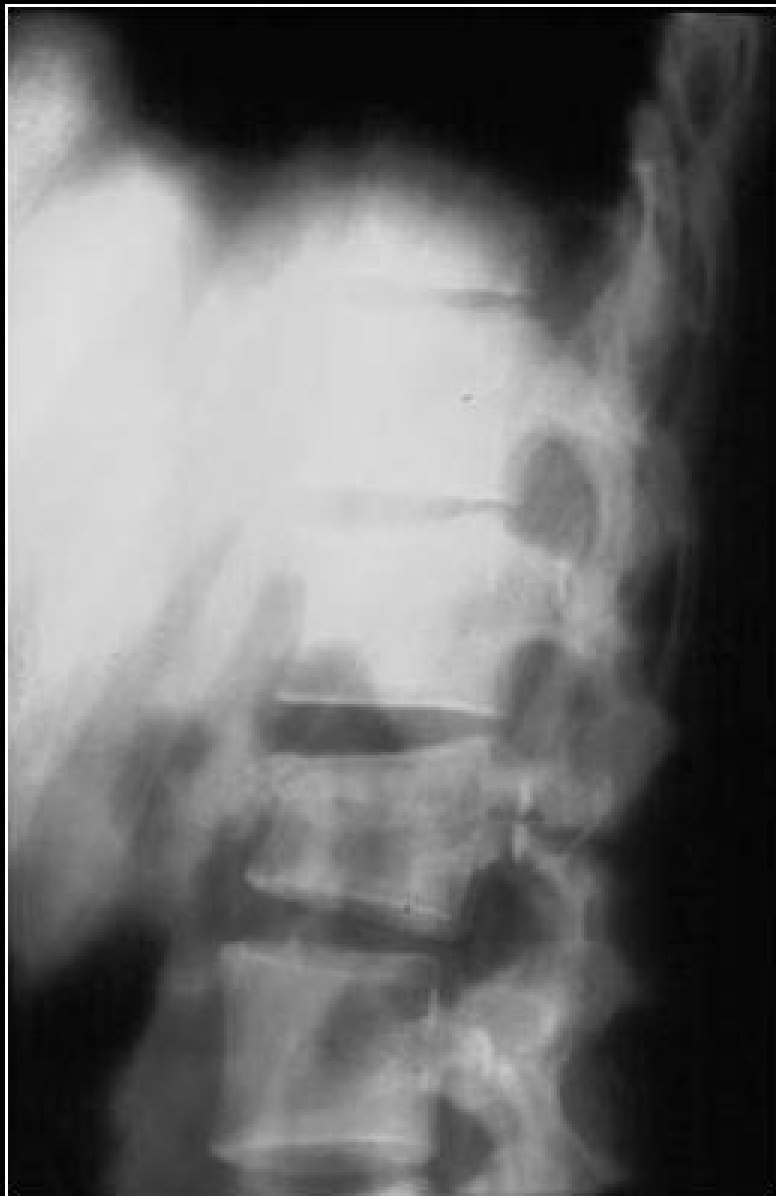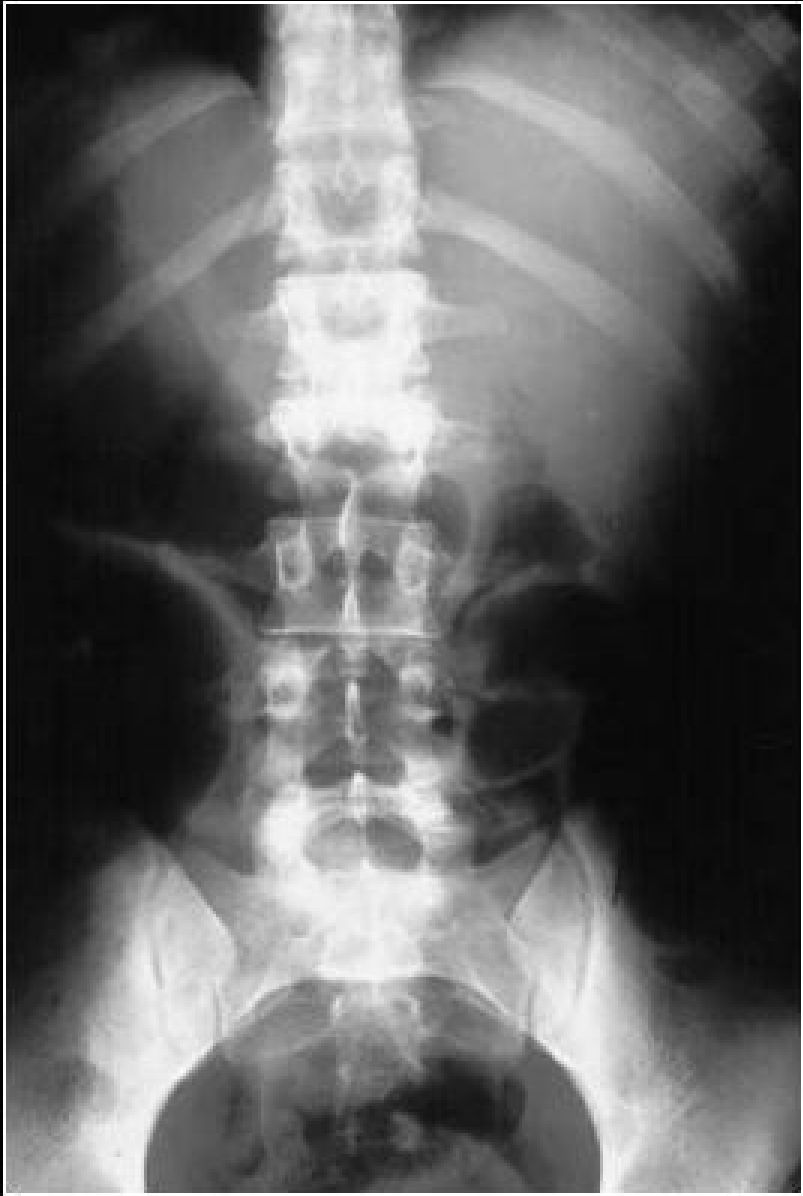B2.1
fratura transversa

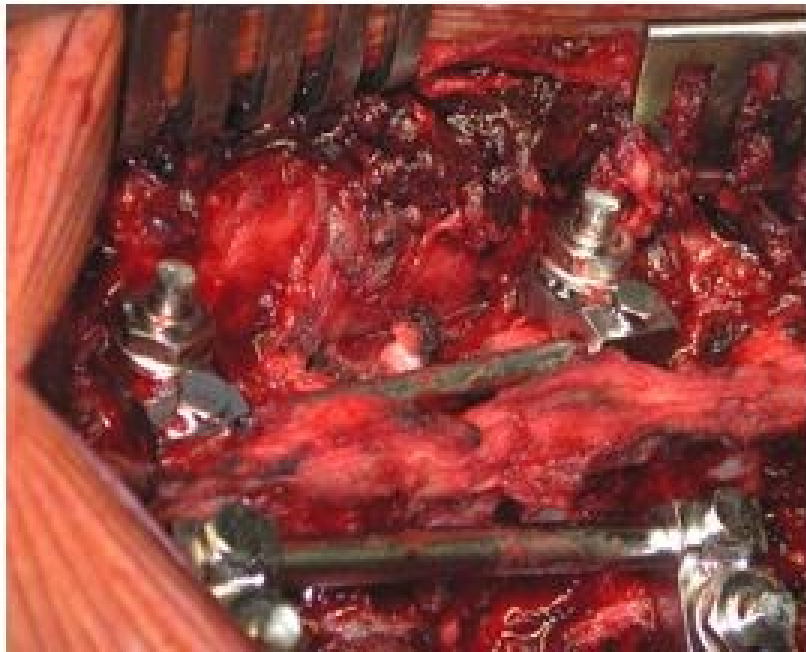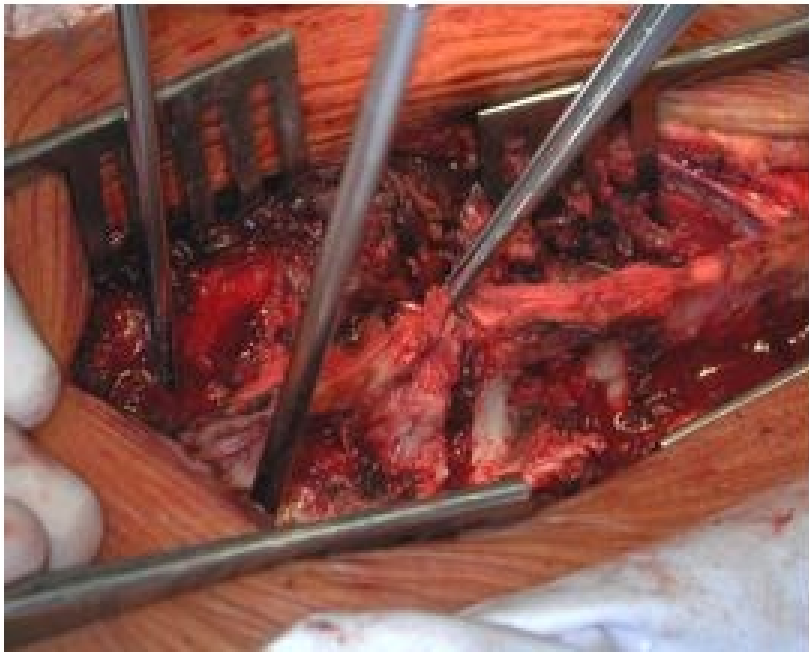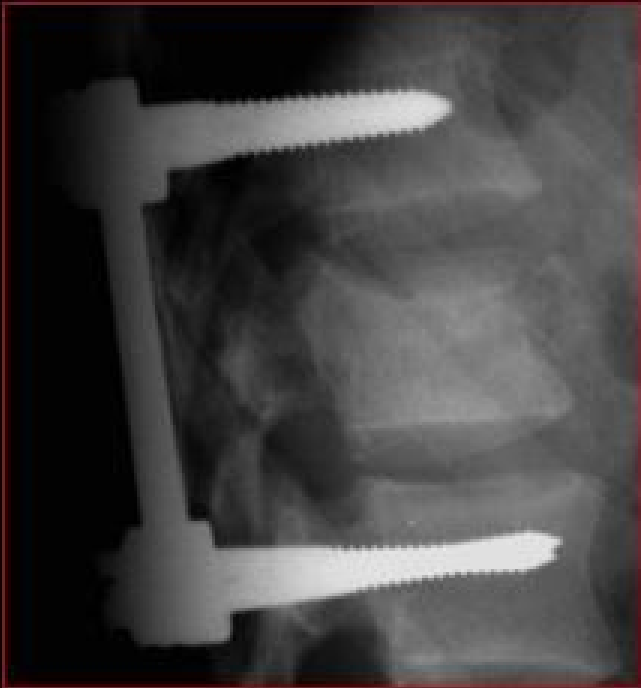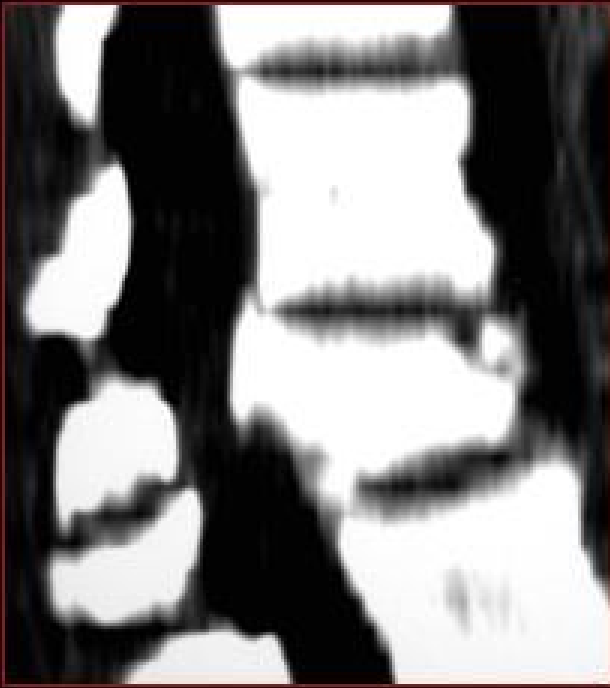


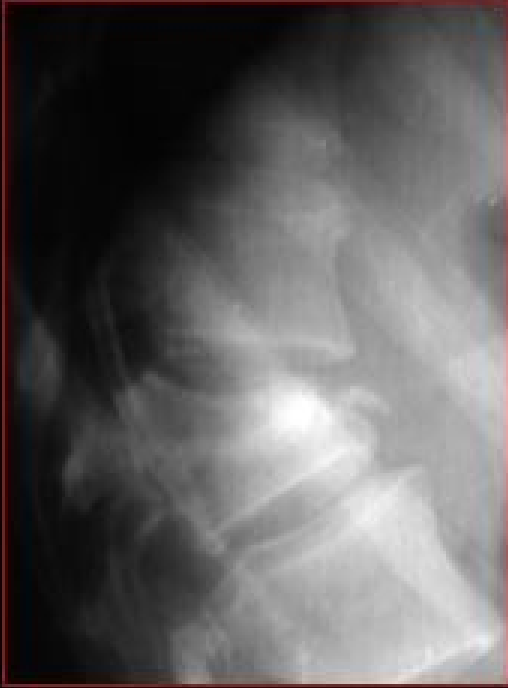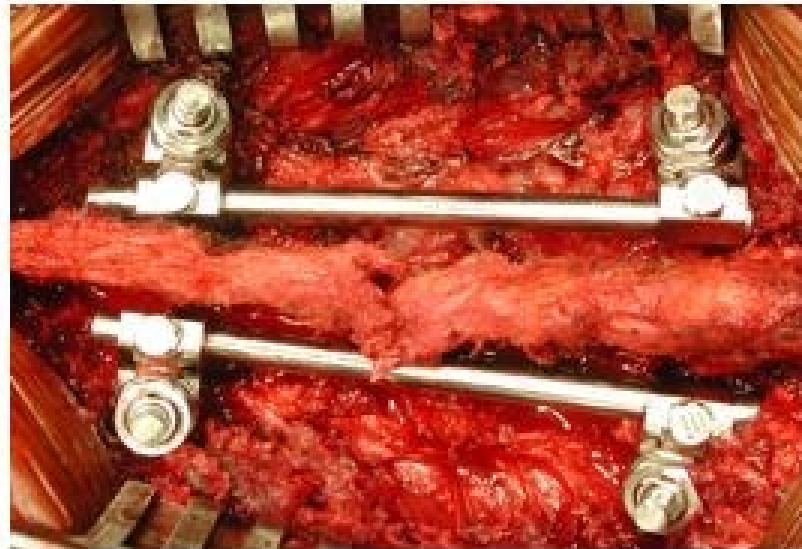
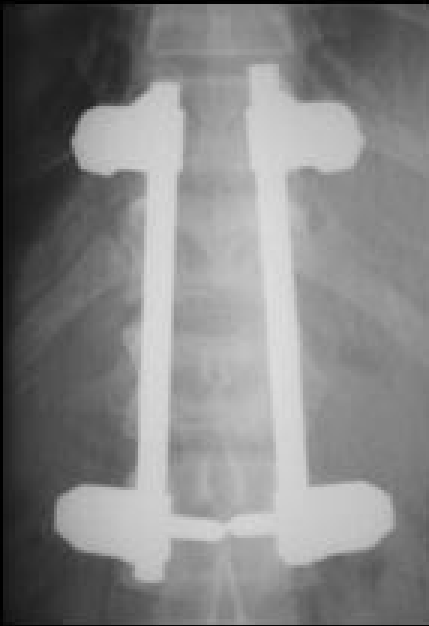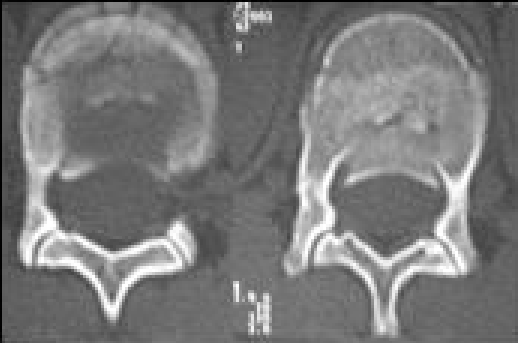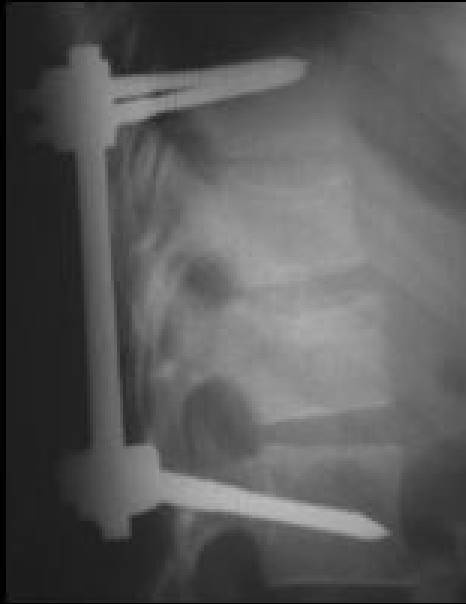B2.2
lesão pars articulares



B2.2 + tipo A



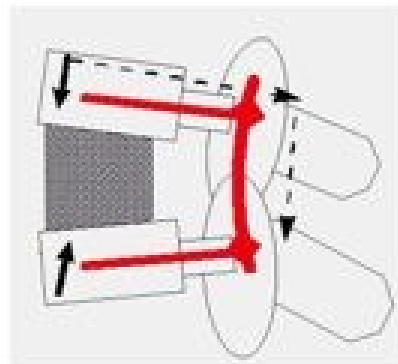
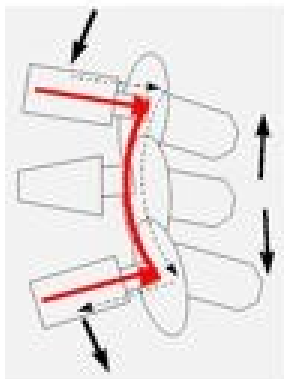
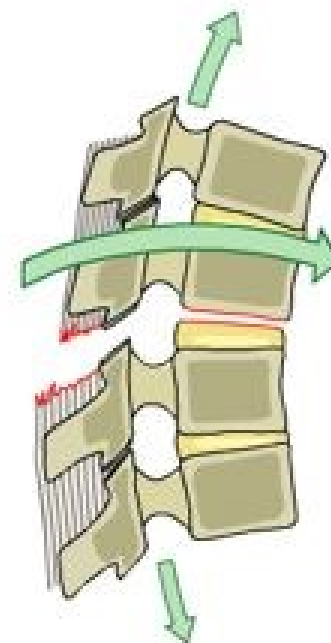
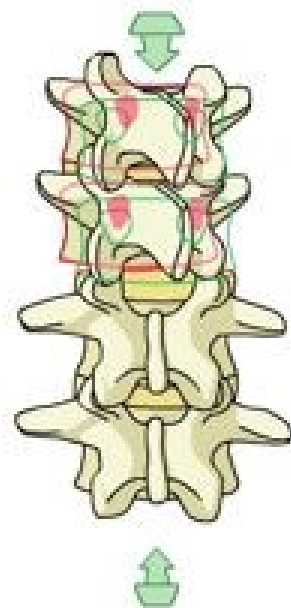




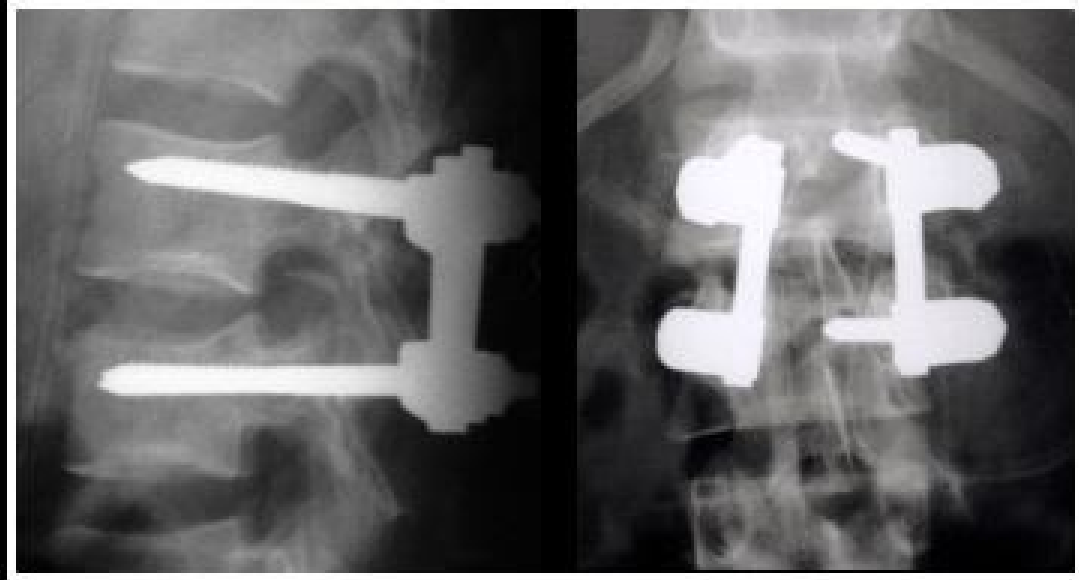
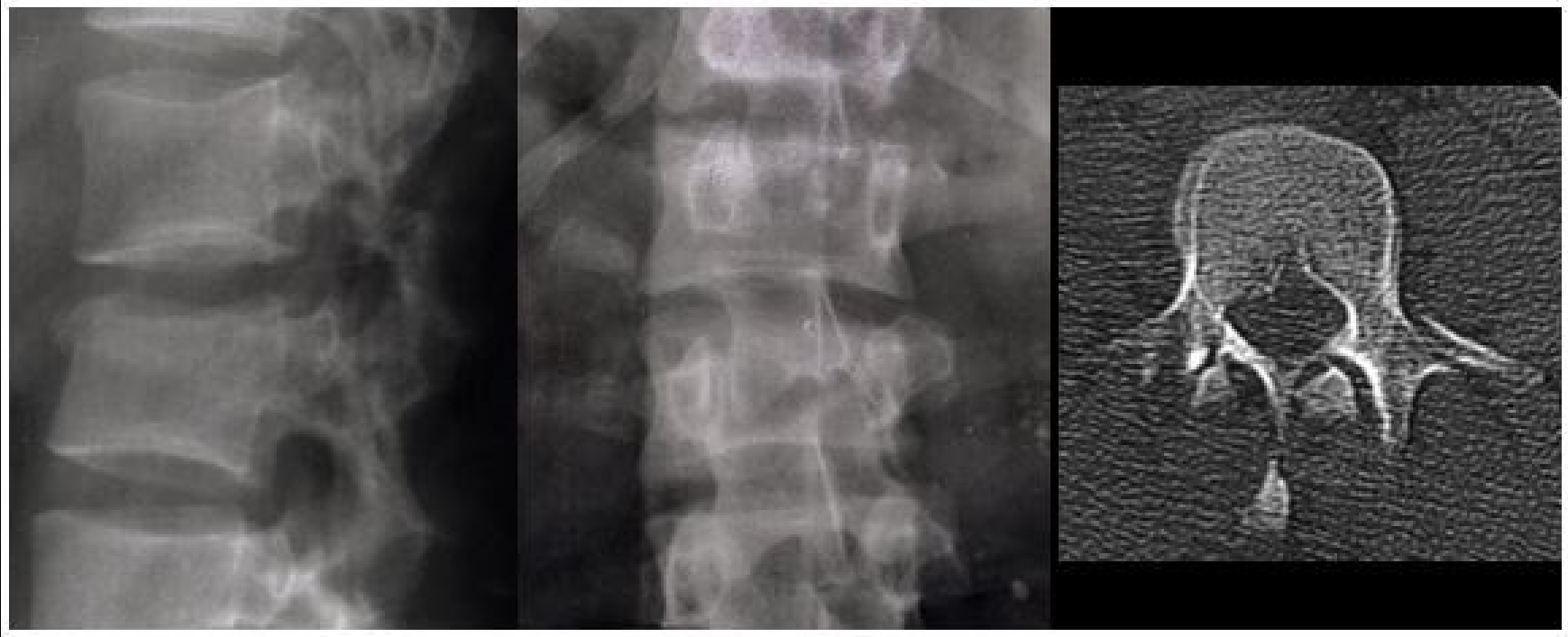
Tipo C

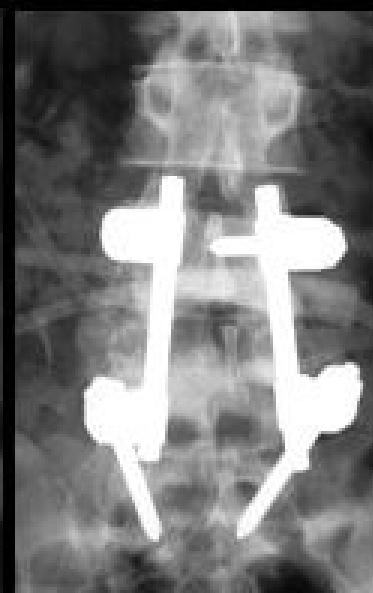
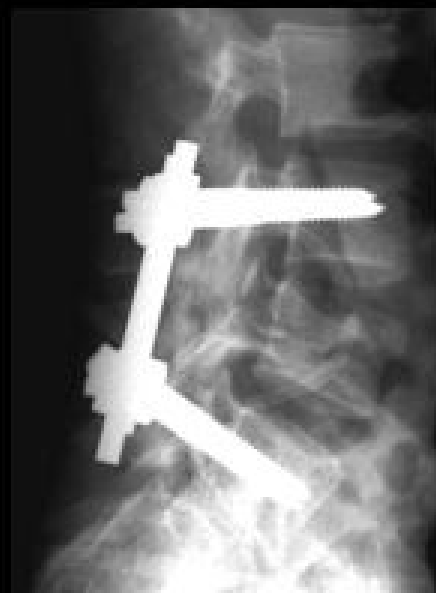
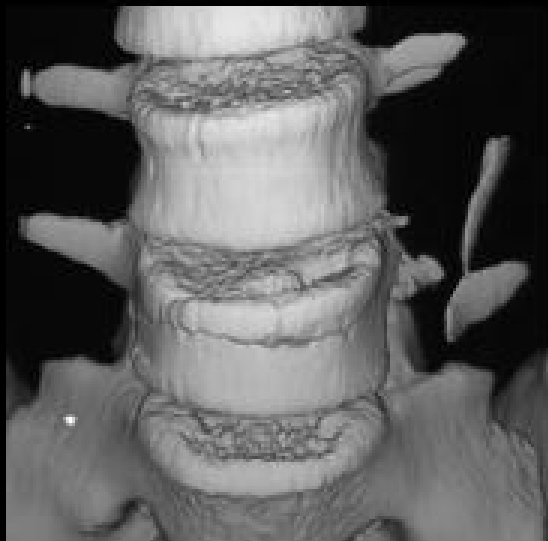
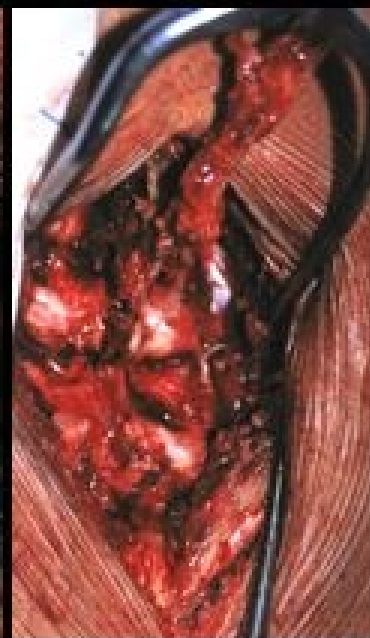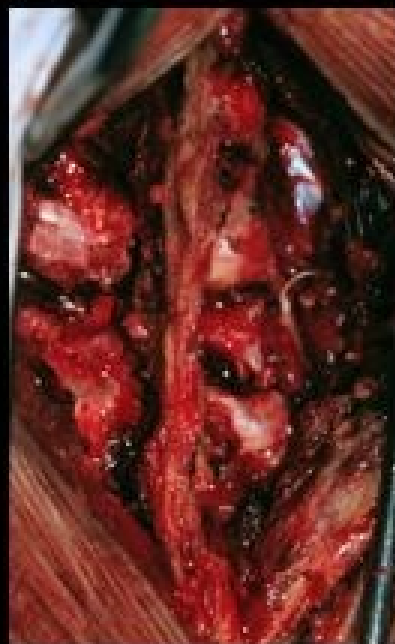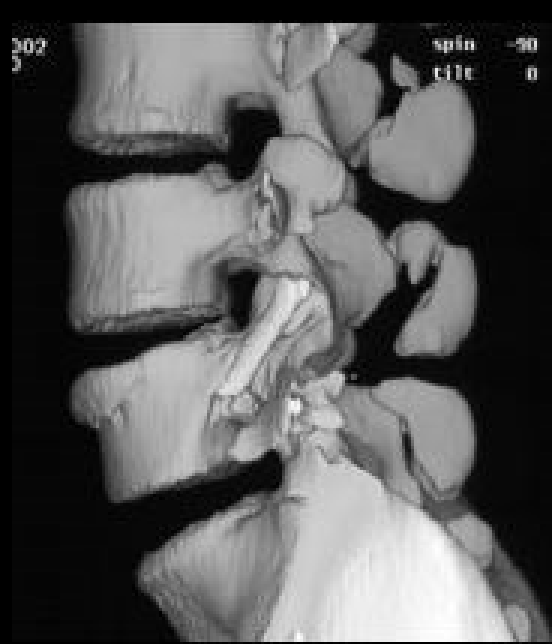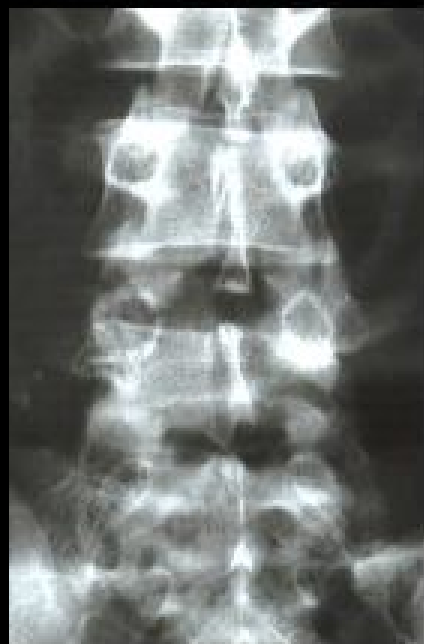**Lesões instáveis -
tratamento cirúrgico**

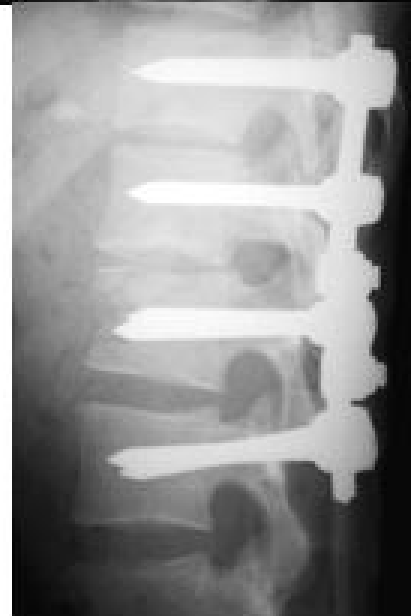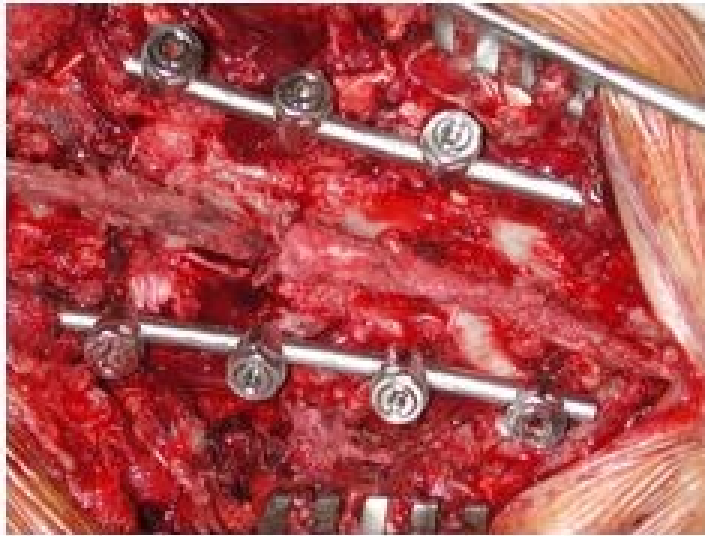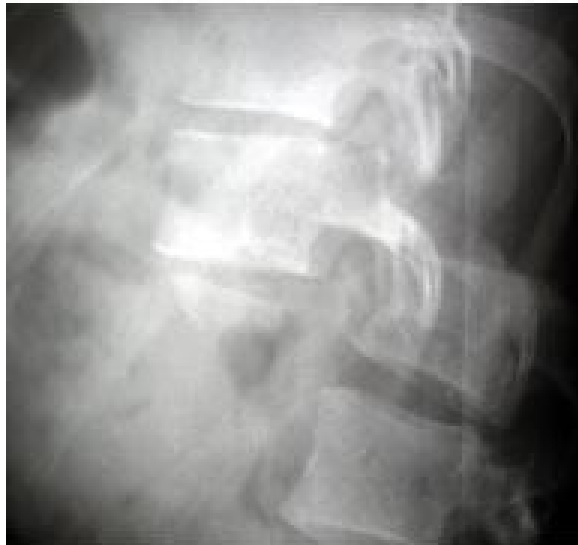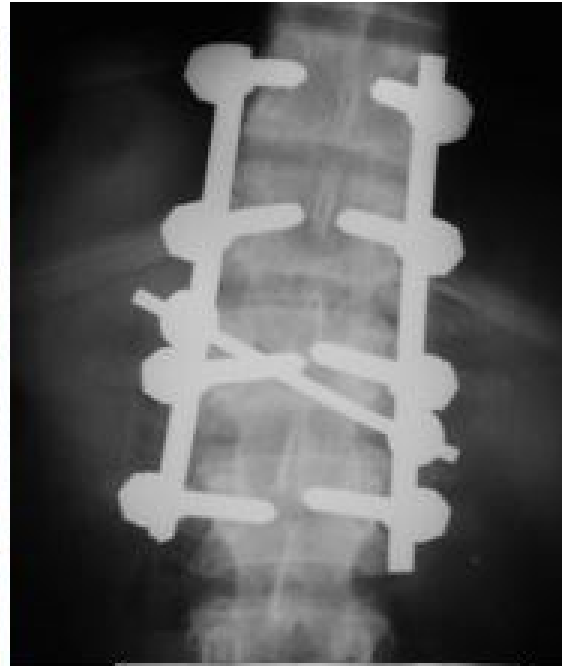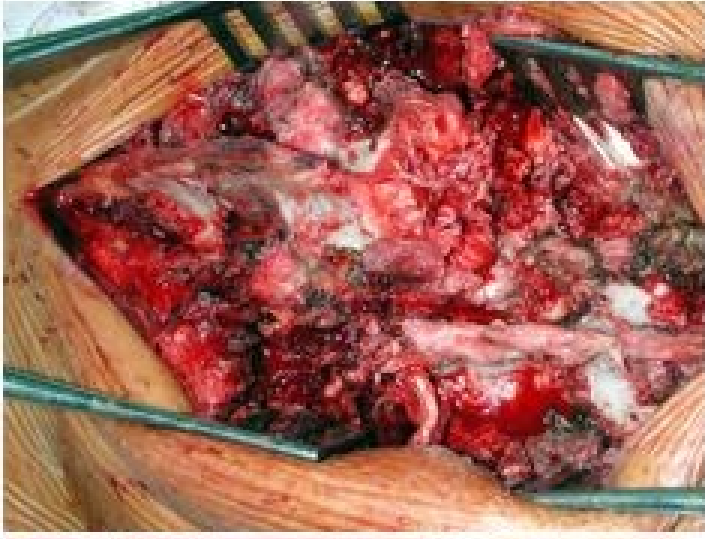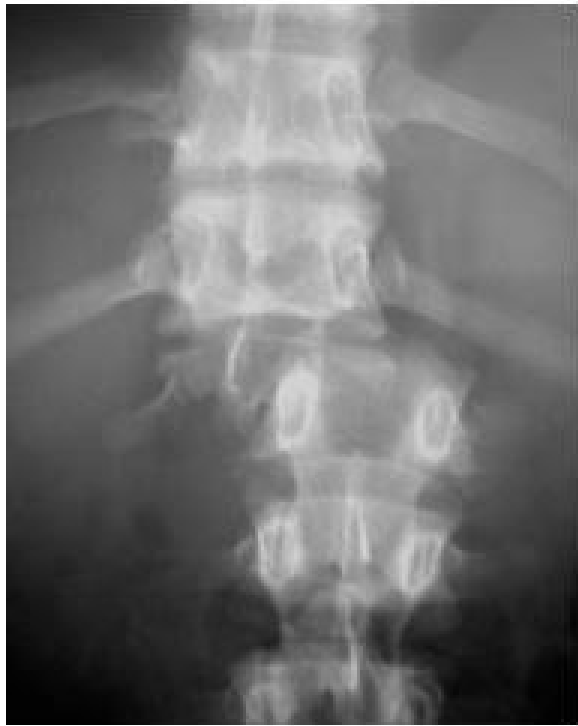- Fixação posterior
- Fixação combinada
(coluna anterior)

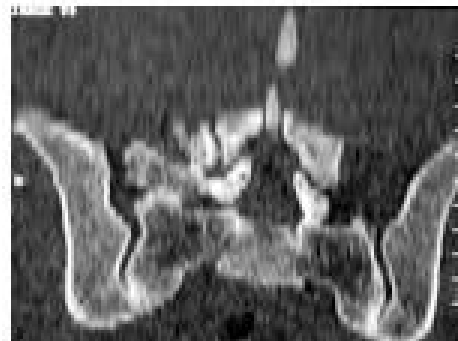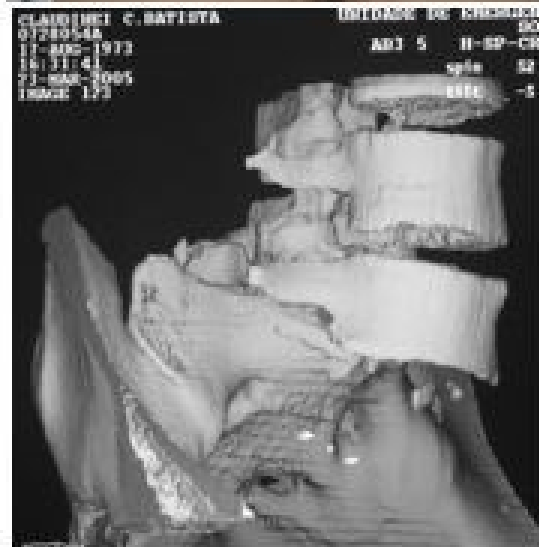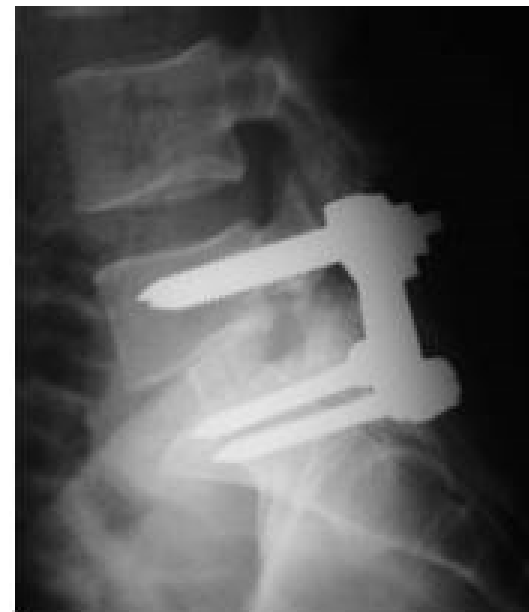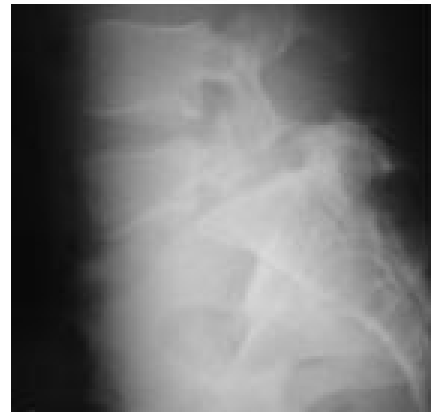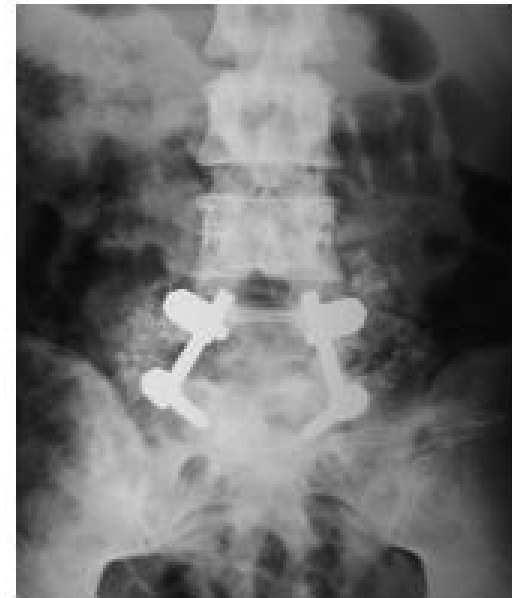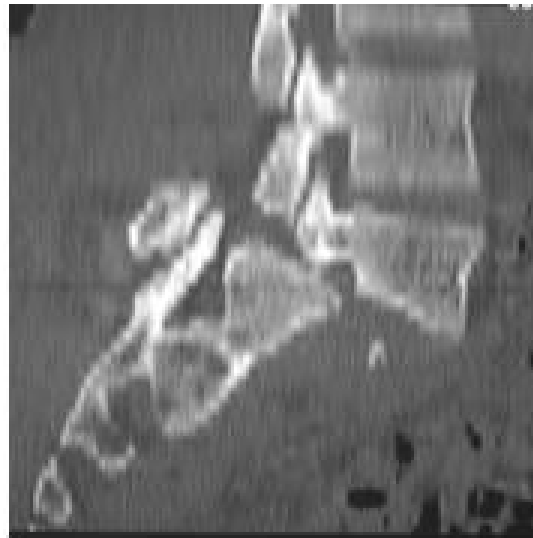


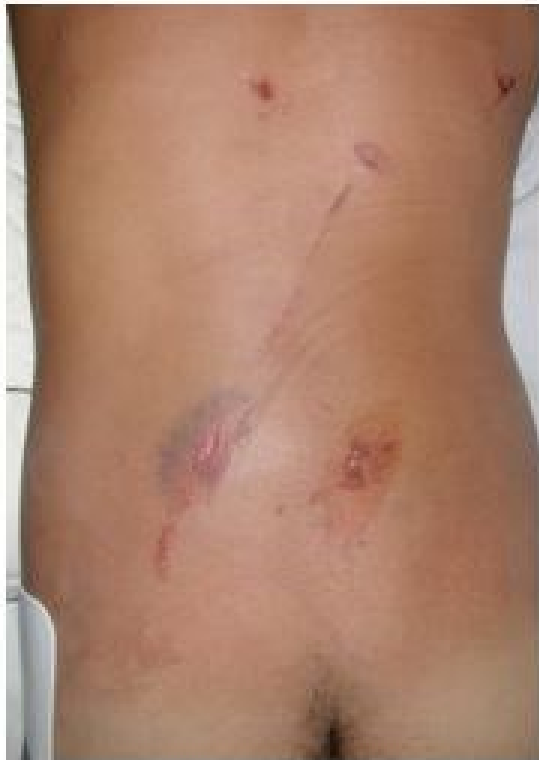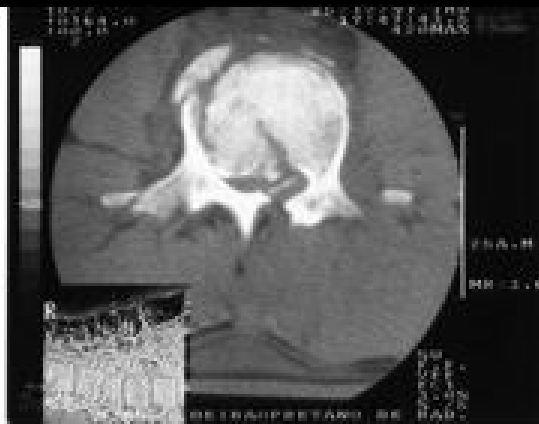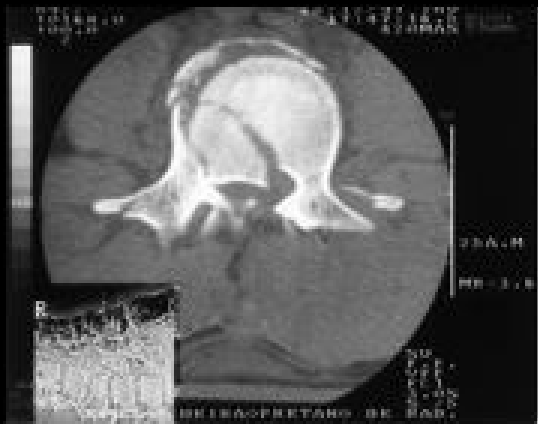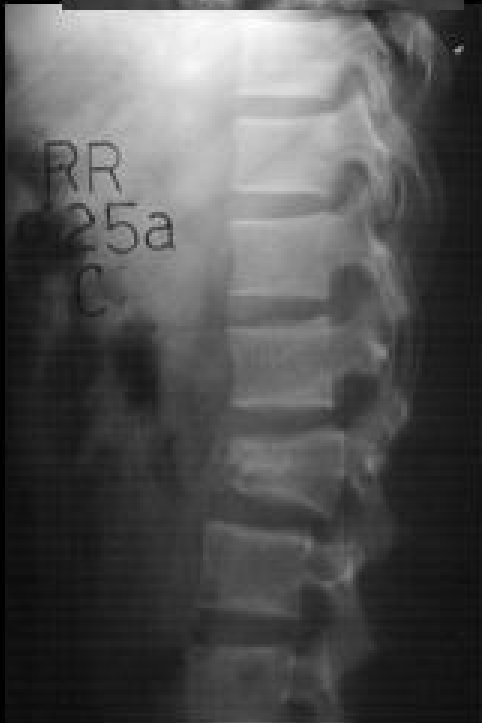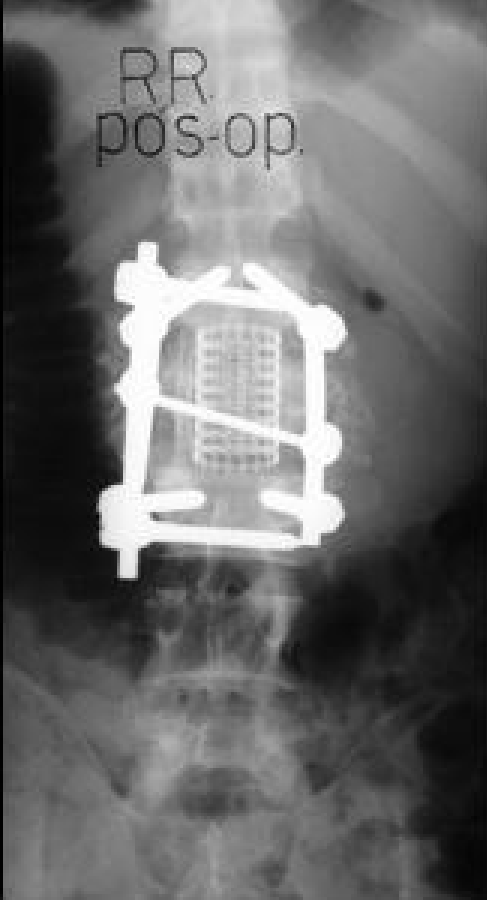
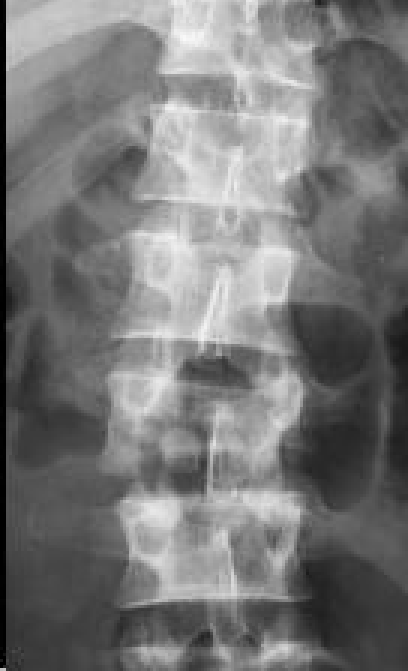TIPO C



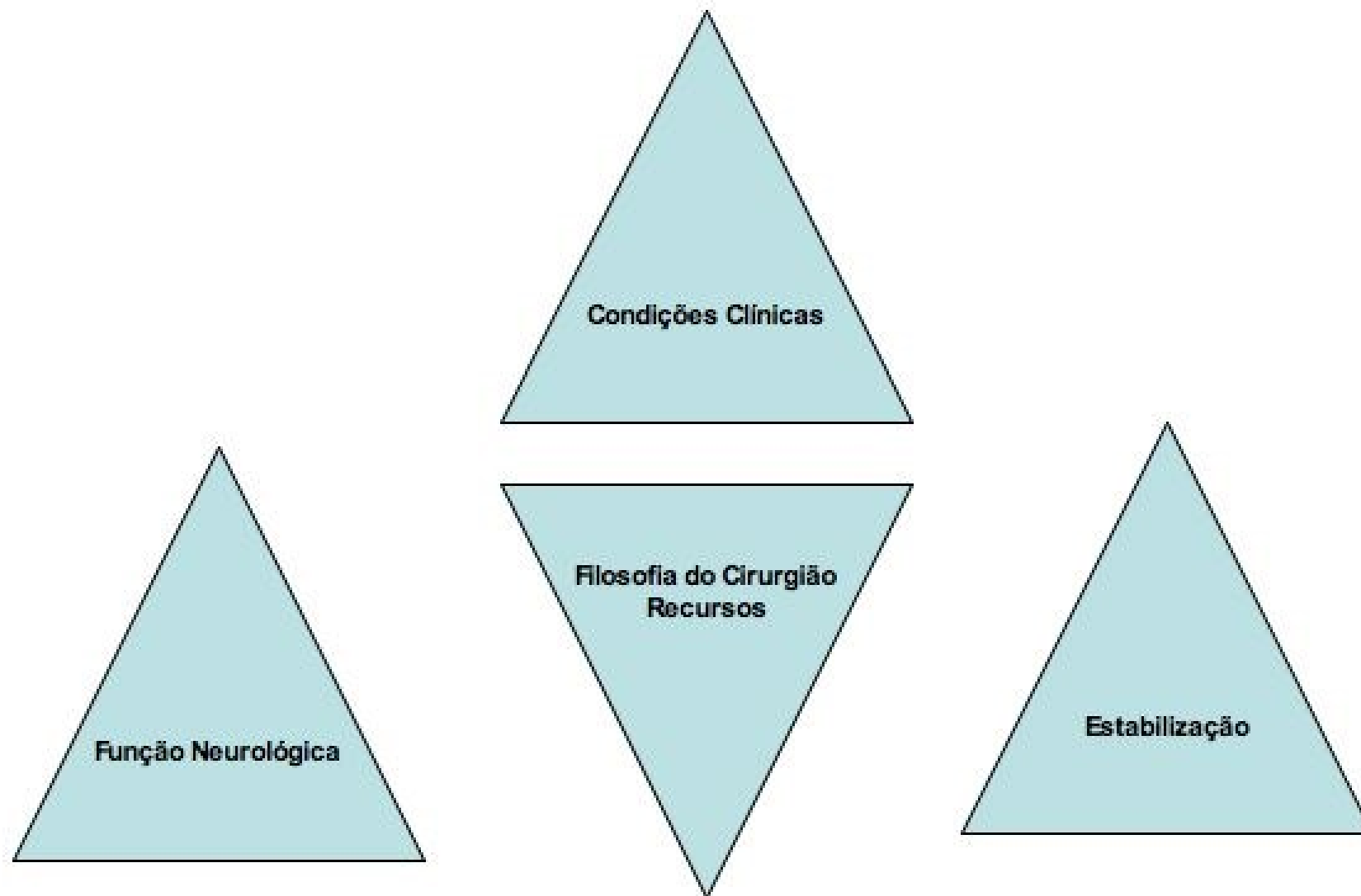








CONCLUSÃO



CONCLUSÃO

