


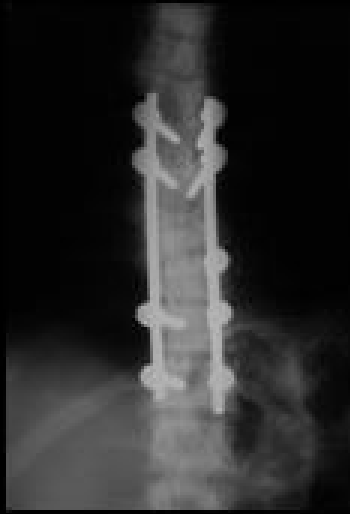
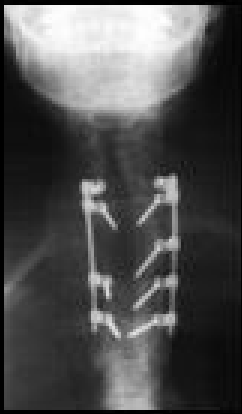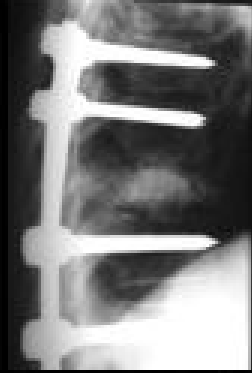
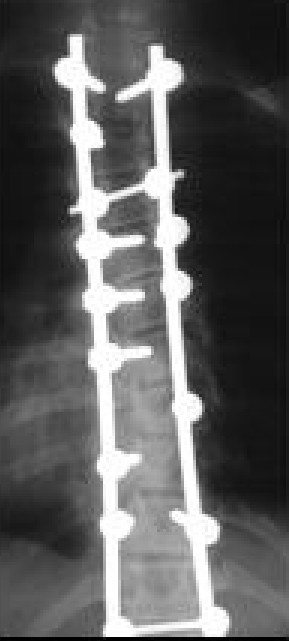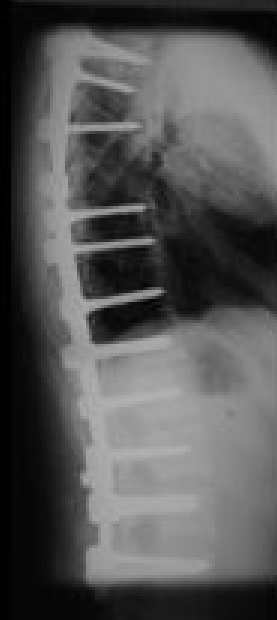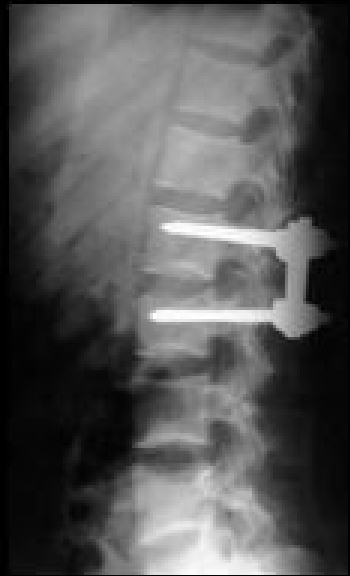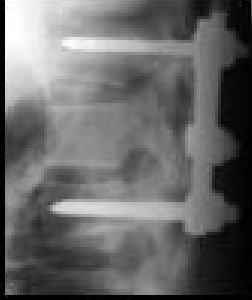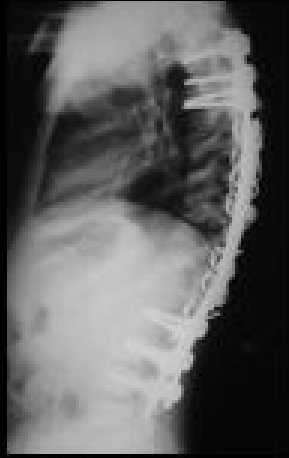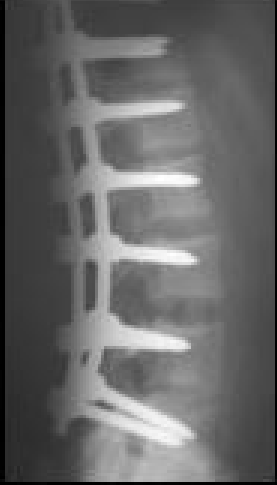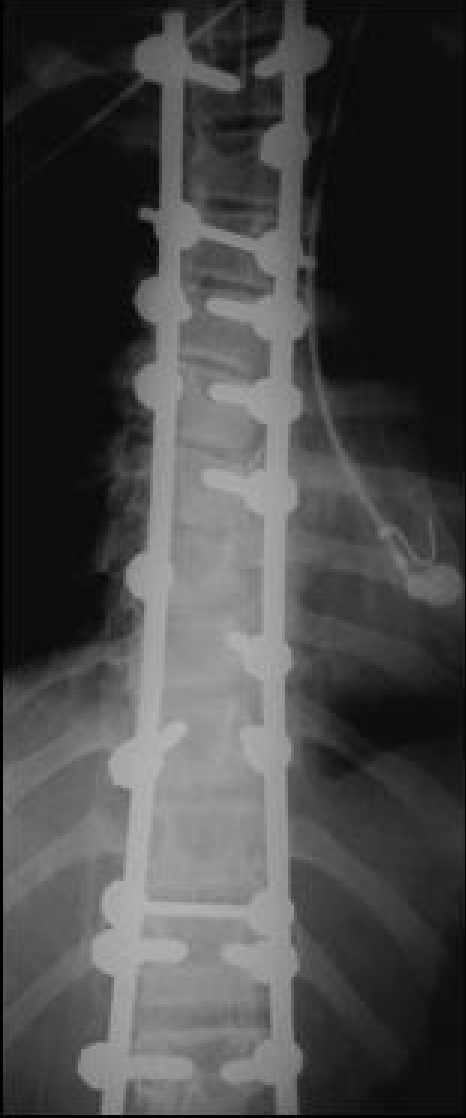**V CONGRESSO DE CIRURGIA
ESPINHAL DE SÃO PAULO**

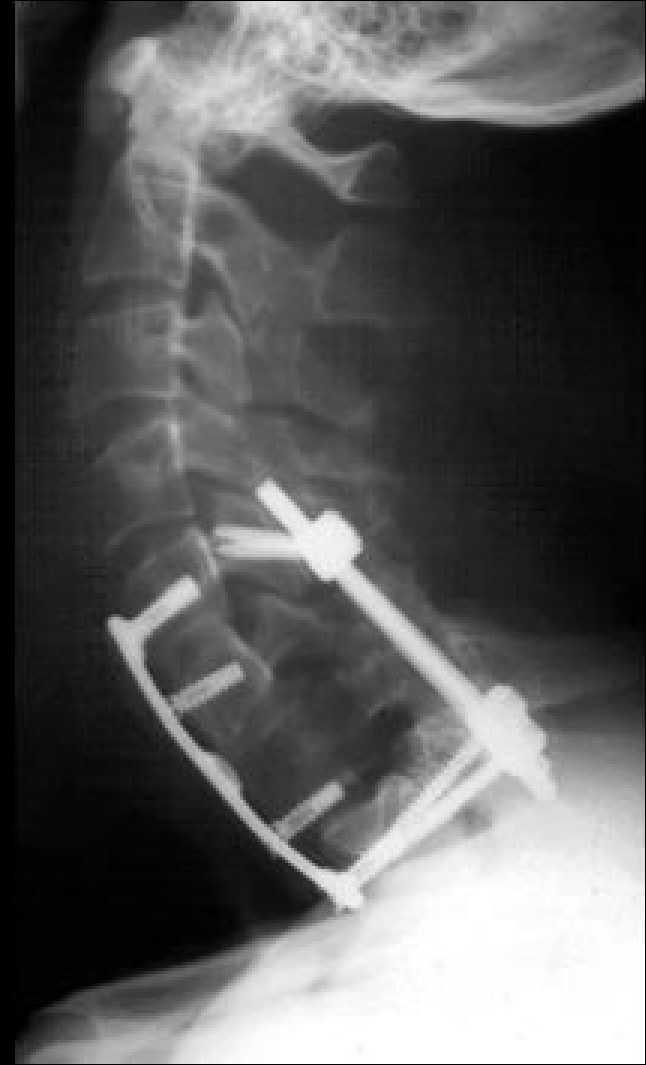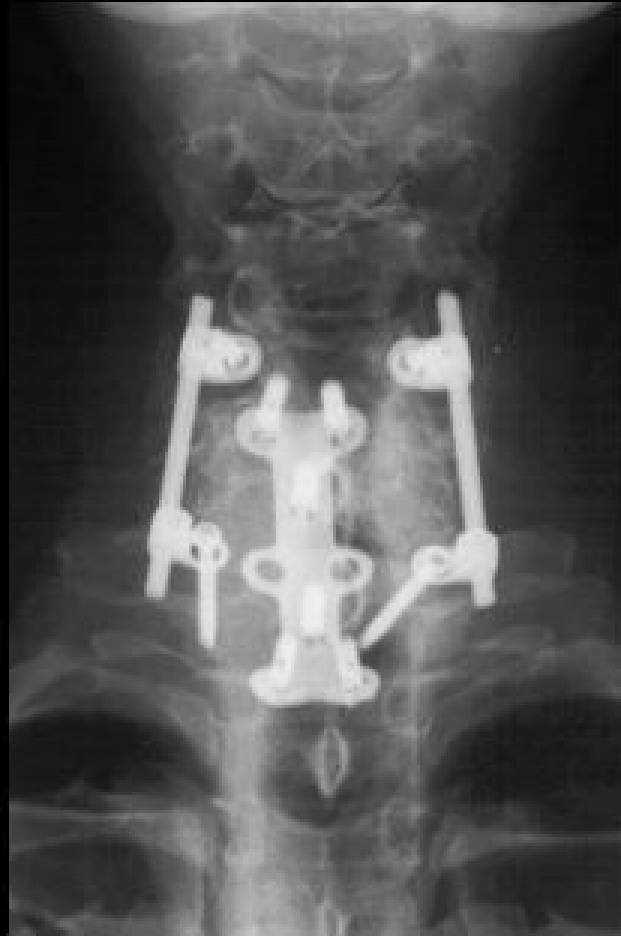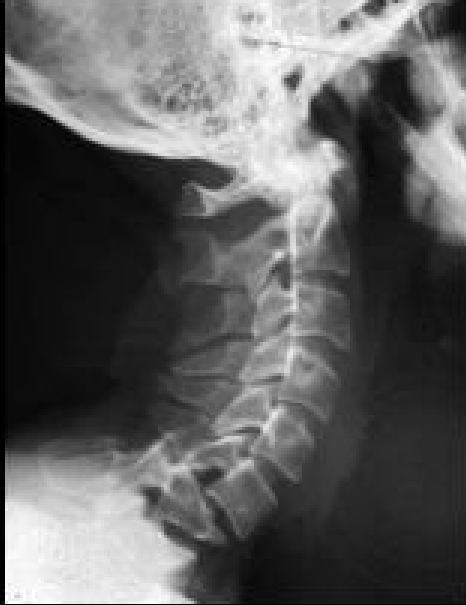**E VII JORNADA DE
CIRURGIA ESPINHAL**

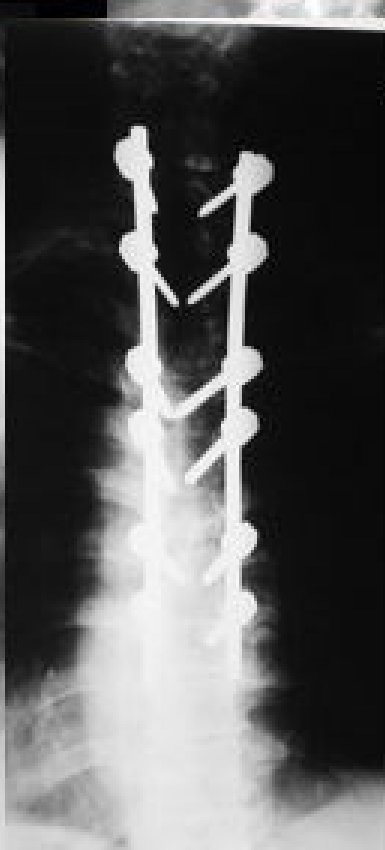
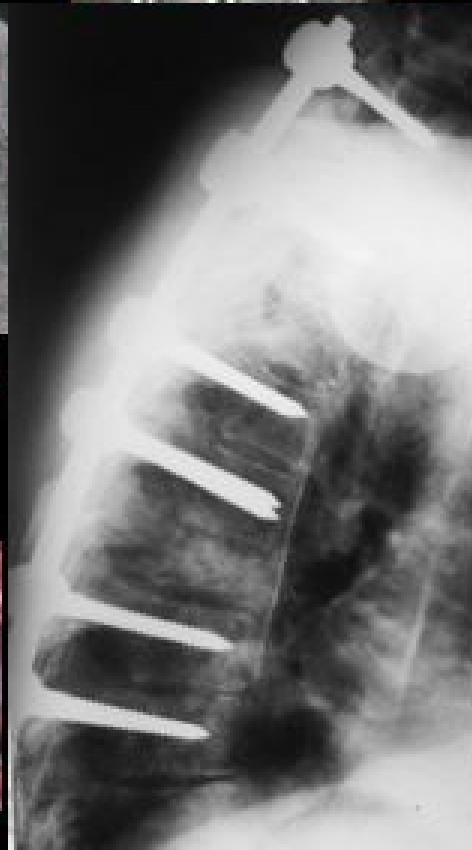
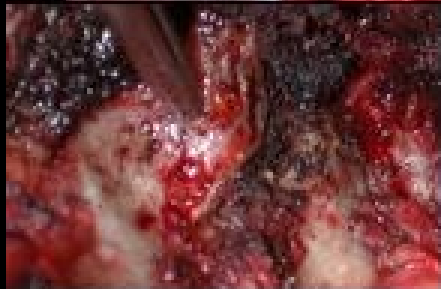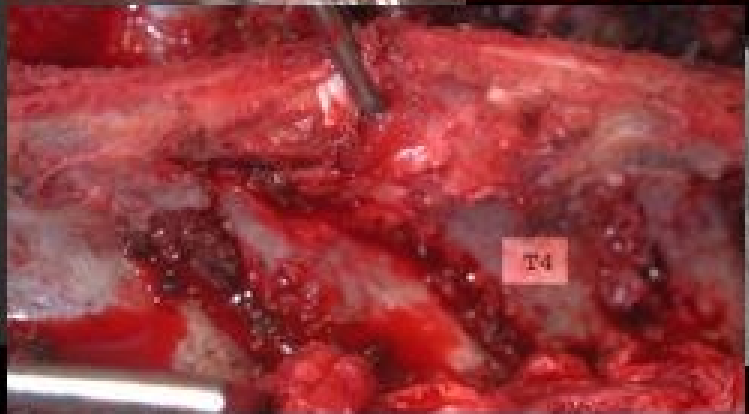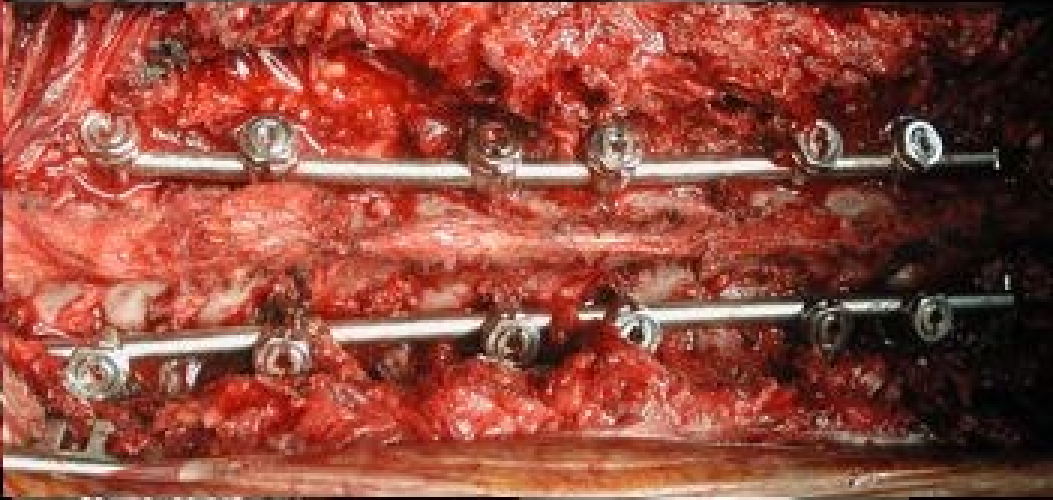
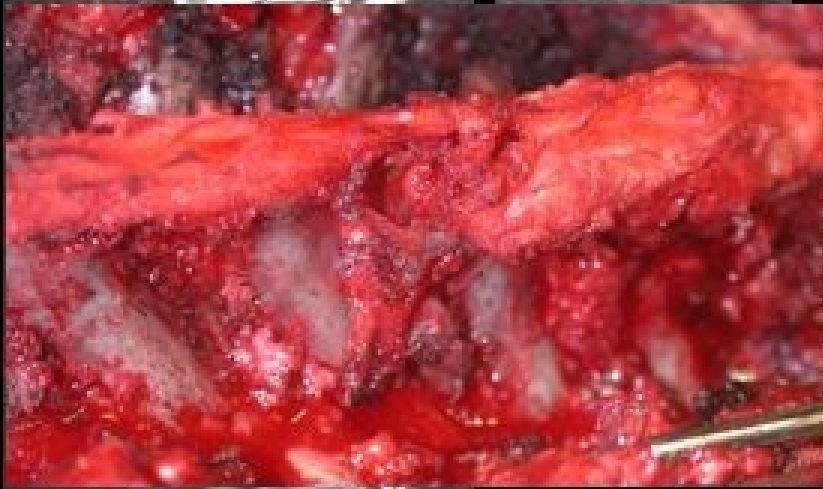**Parafuso Pedicular
Coluna Torácica**

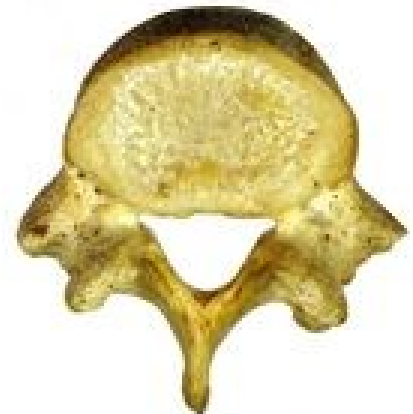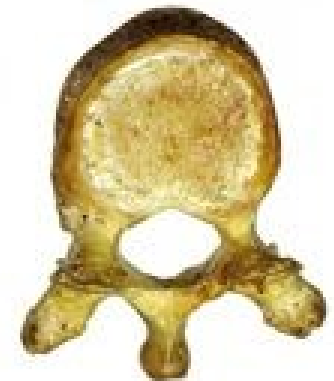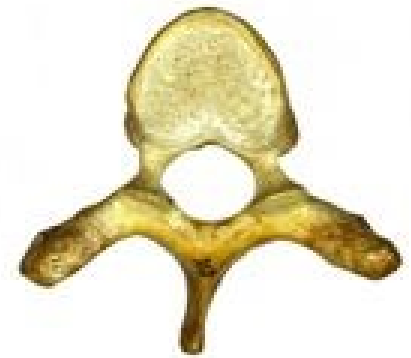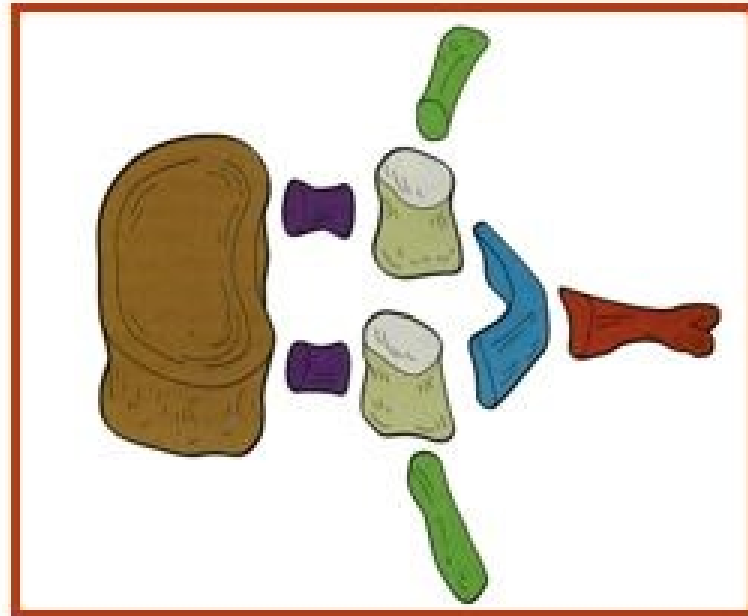
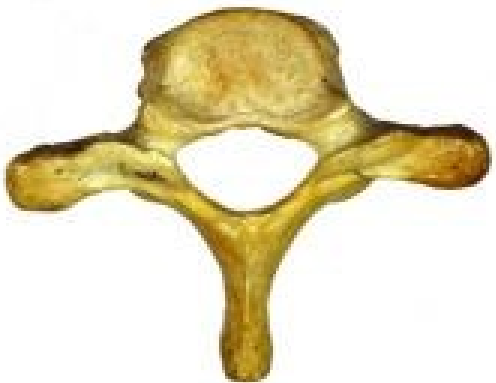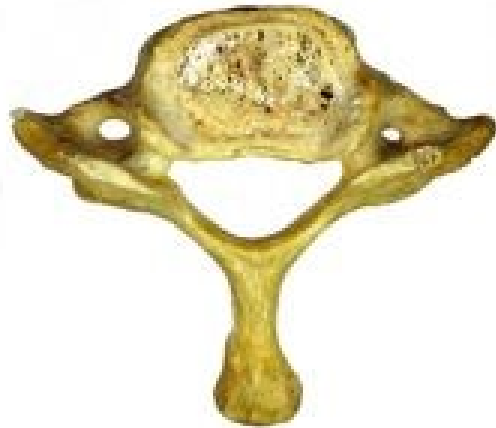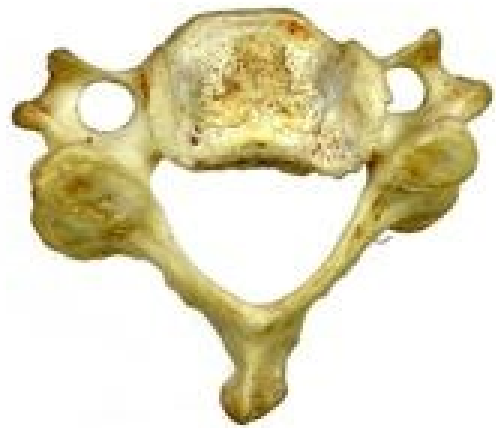Helton Defino
Faculdade de Medicina de Ribeirão Preto
USP

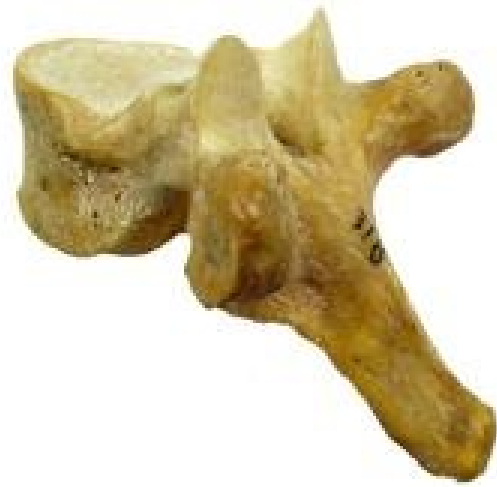

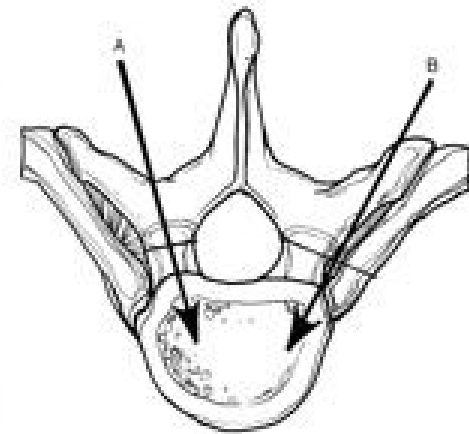
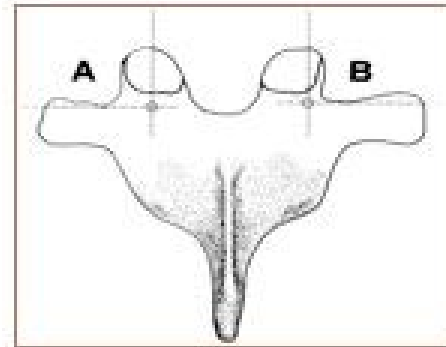
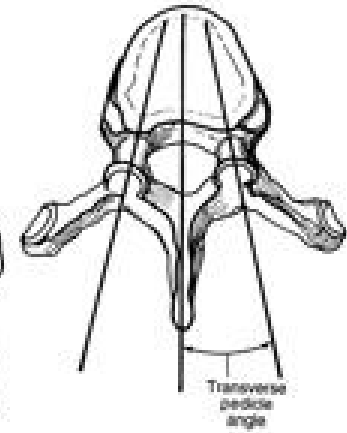
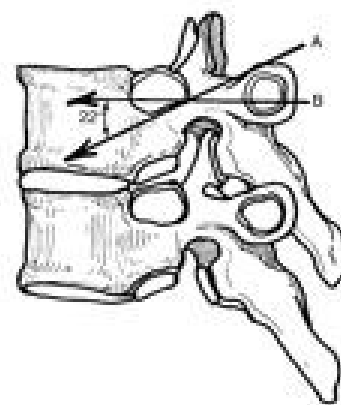
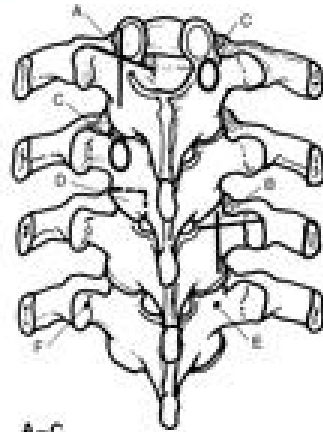
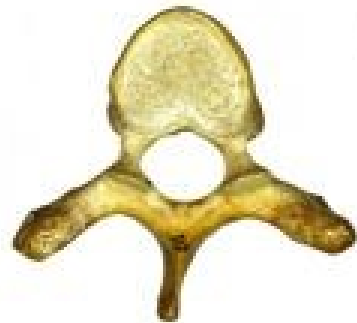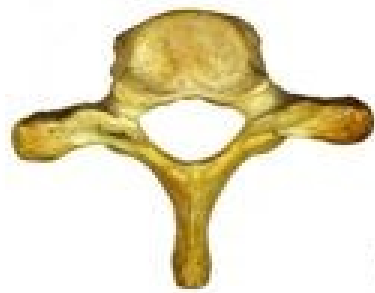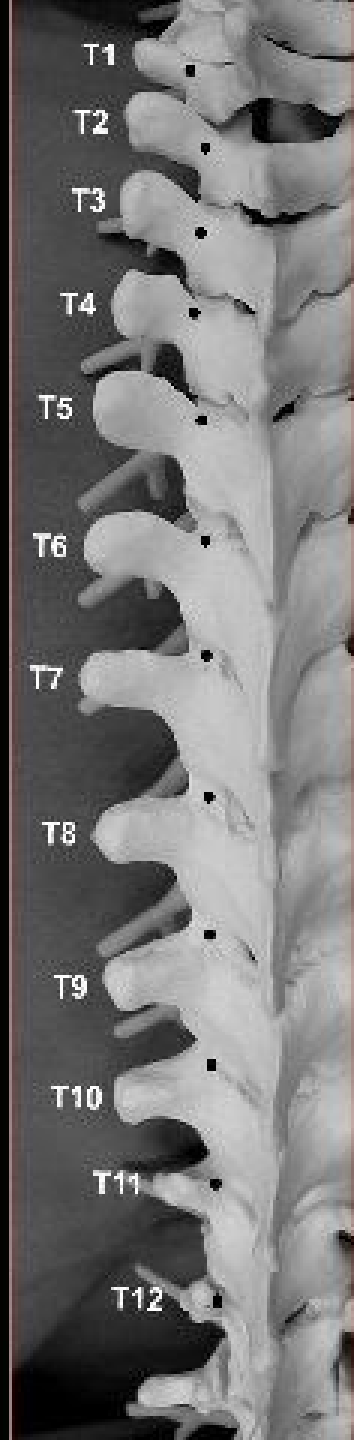




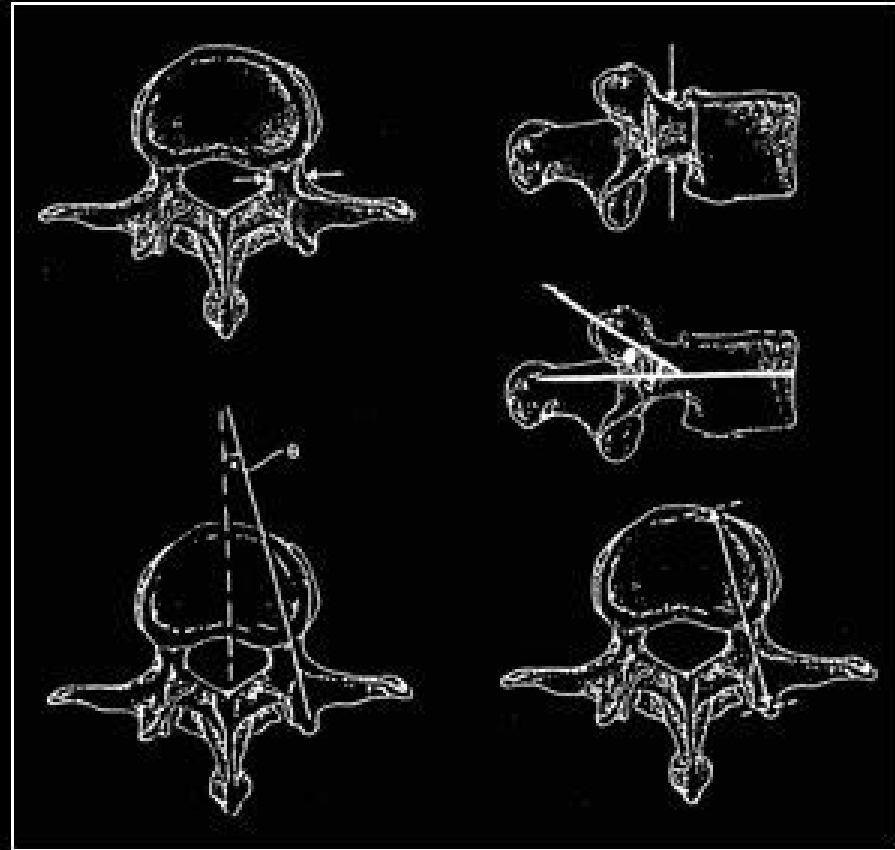



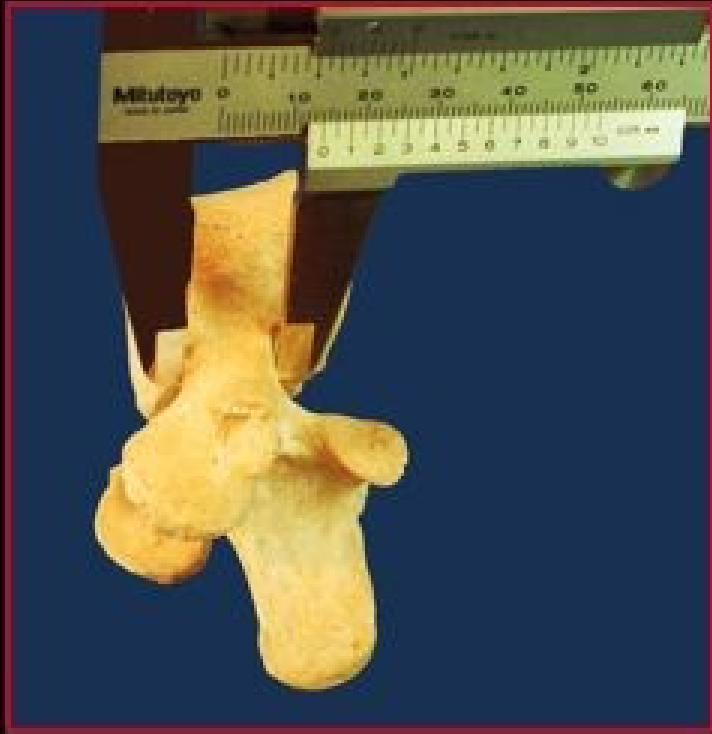
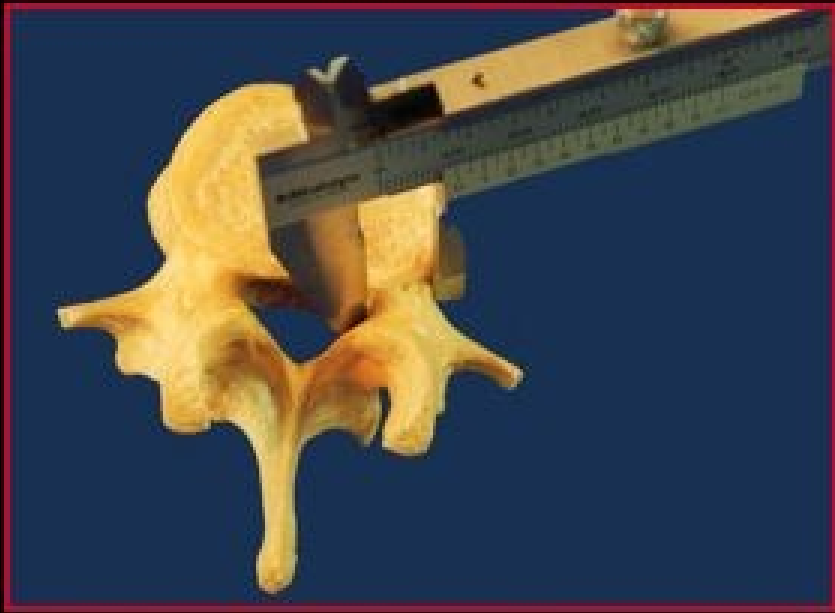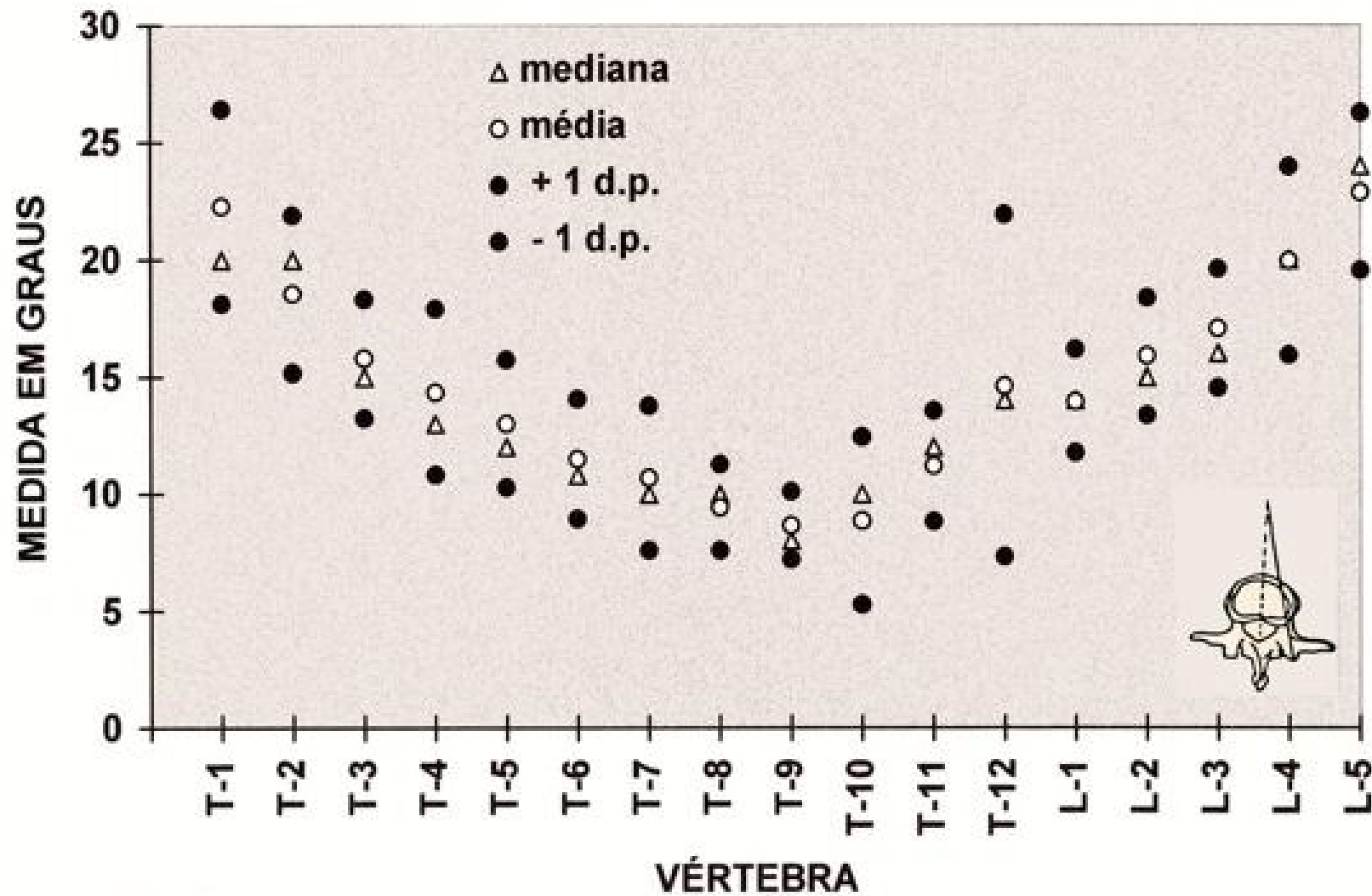




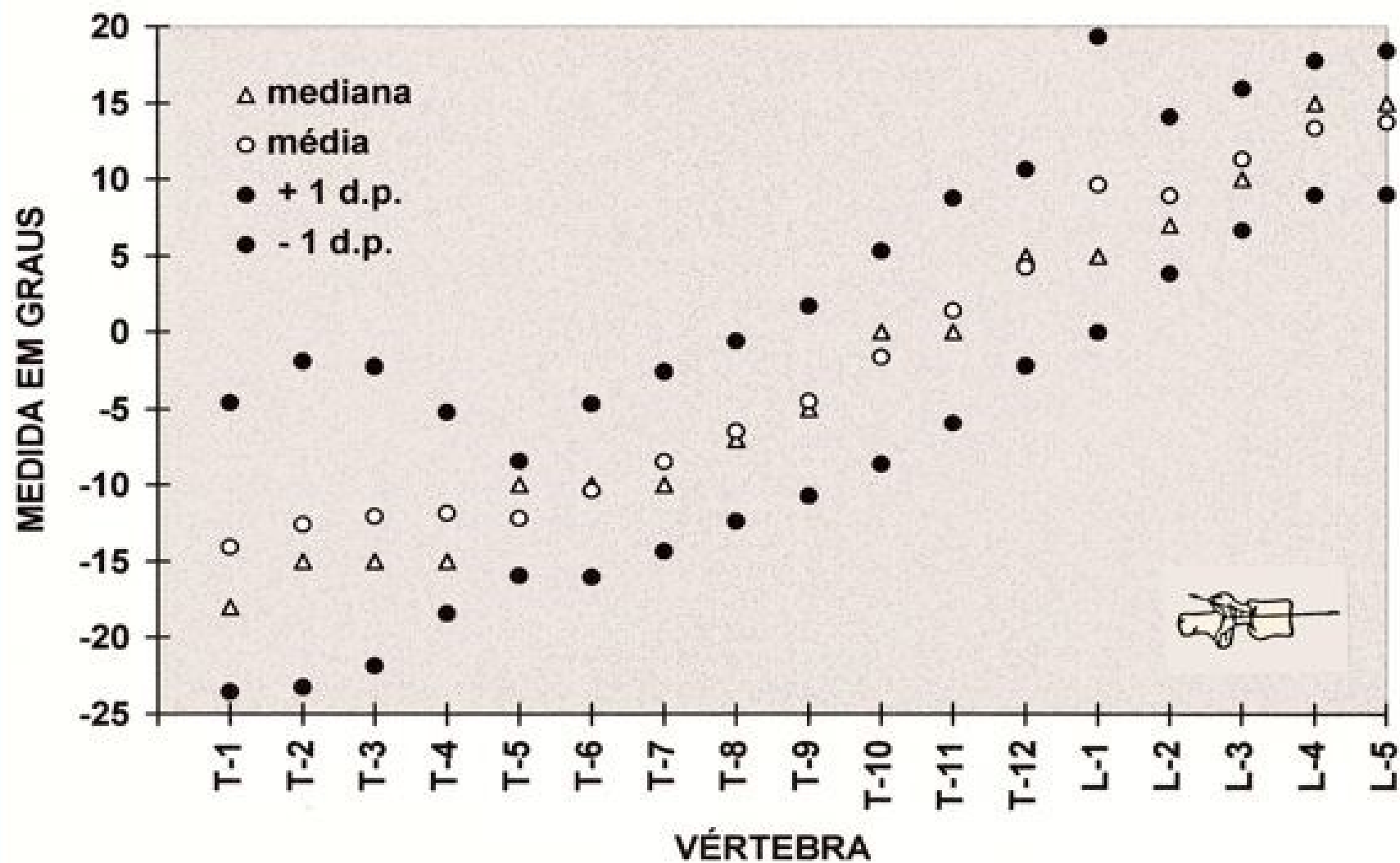
Morfometria



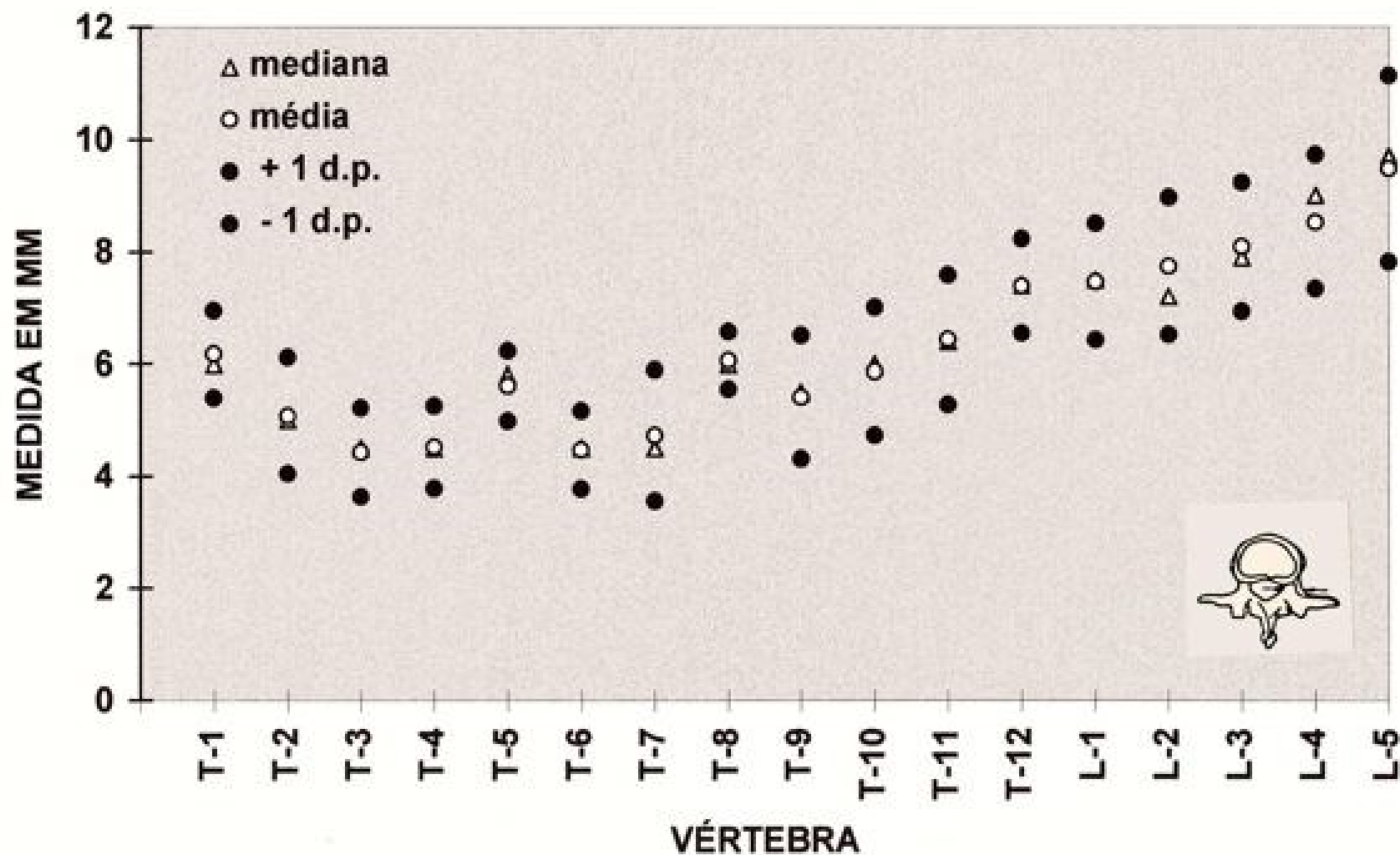
Ângulo transversal



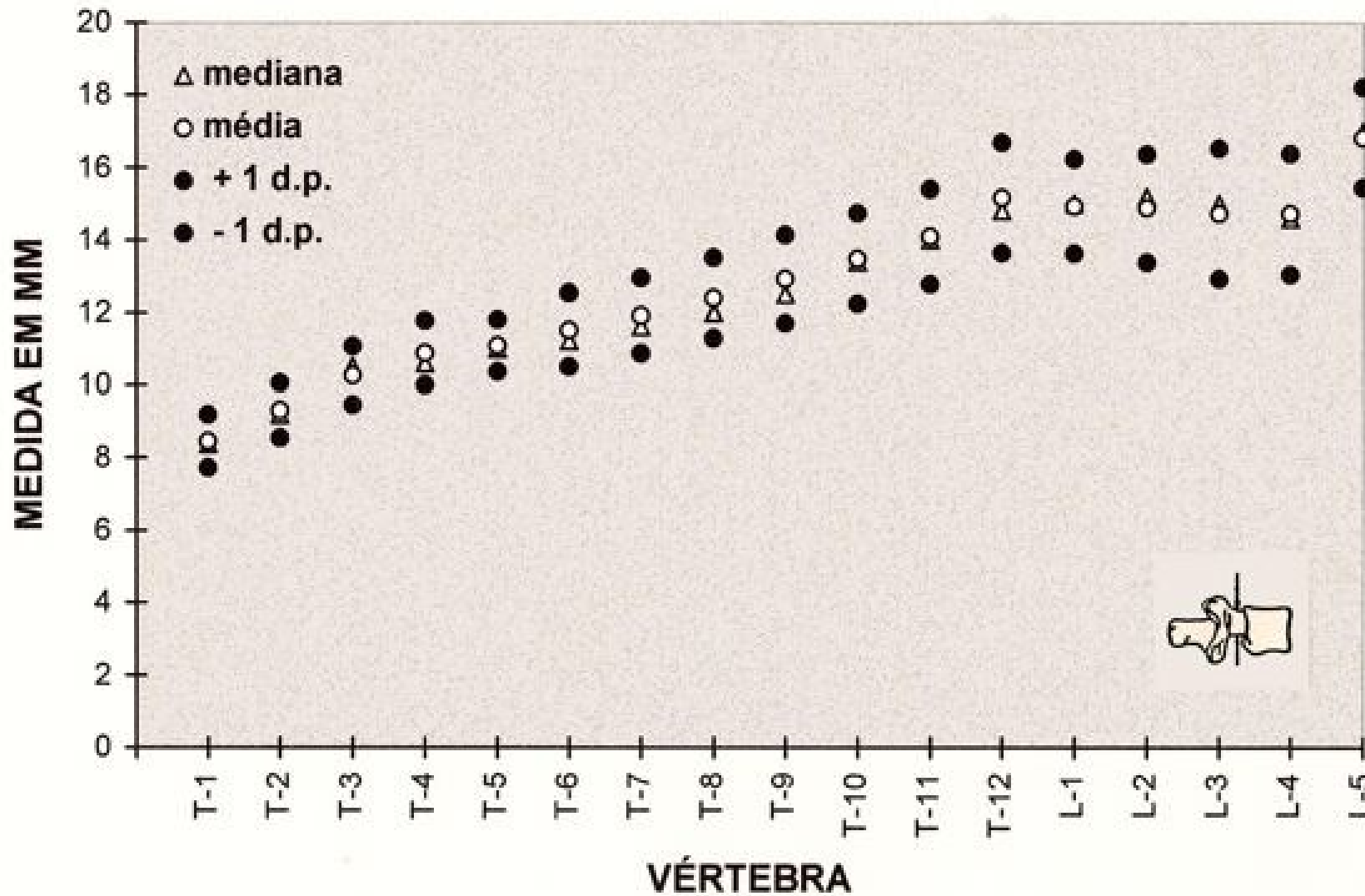
Ângulo sagital



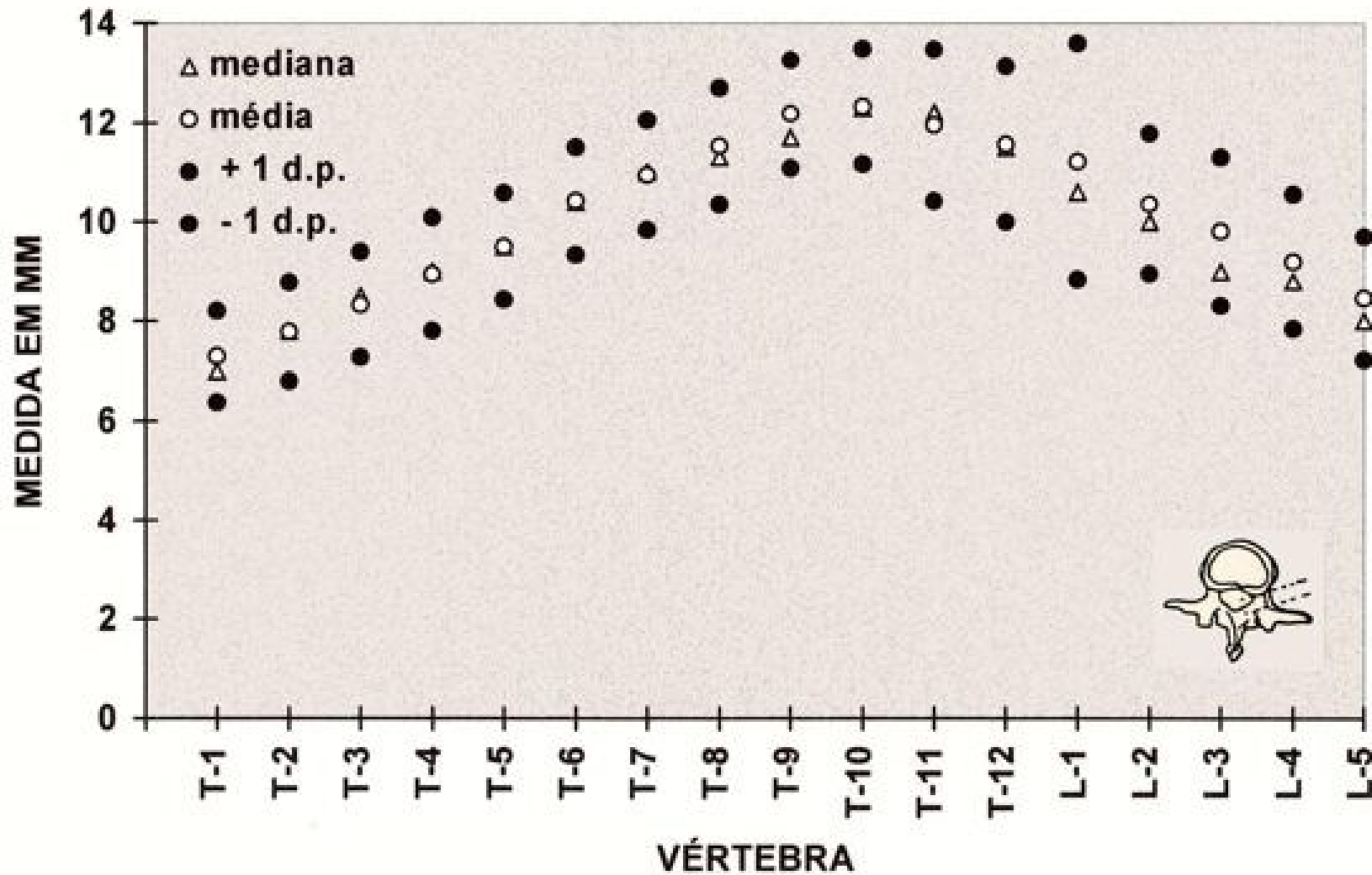
Diâmetro mínimo do pedículo



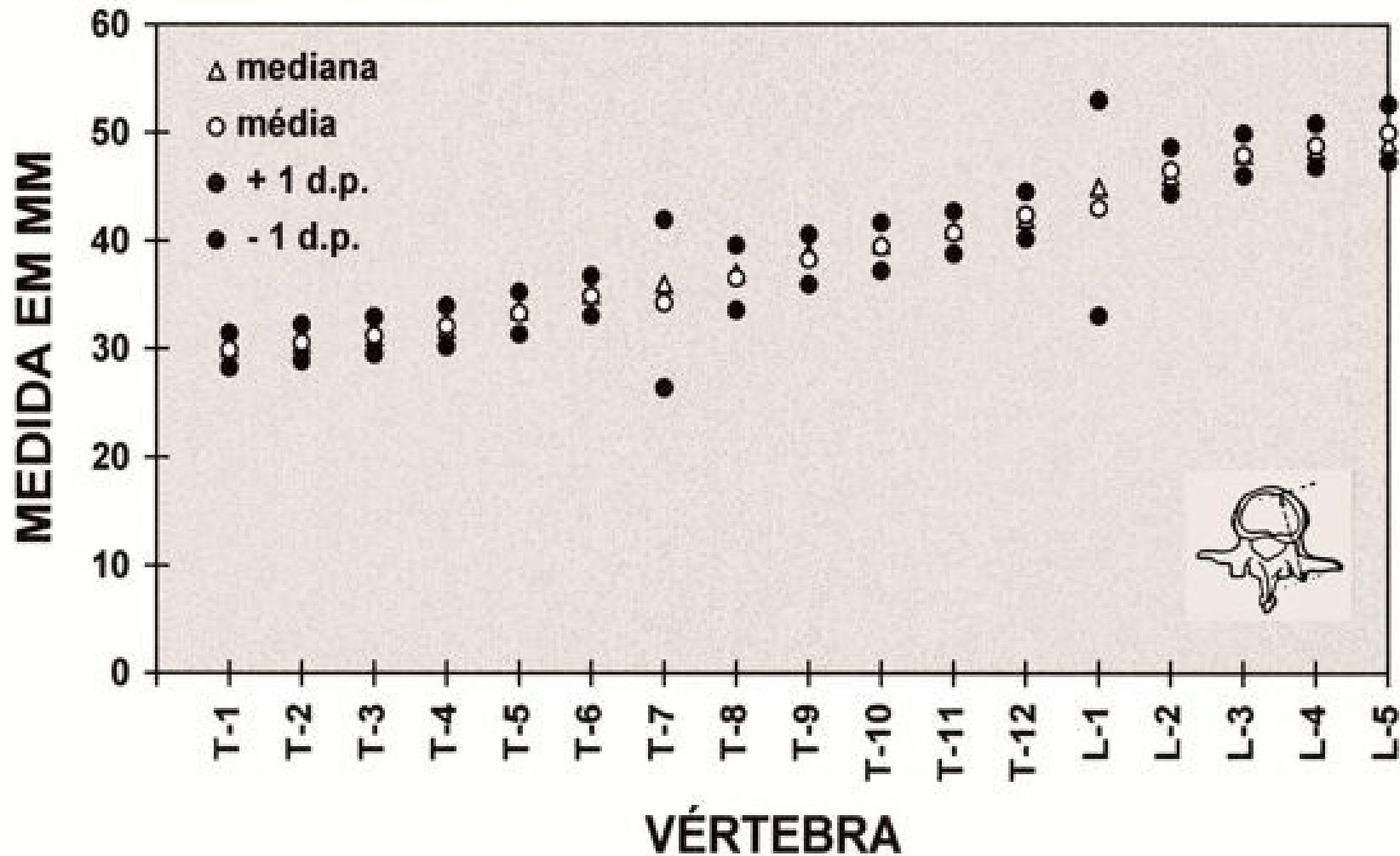
Diâmetro máximo do pedículo

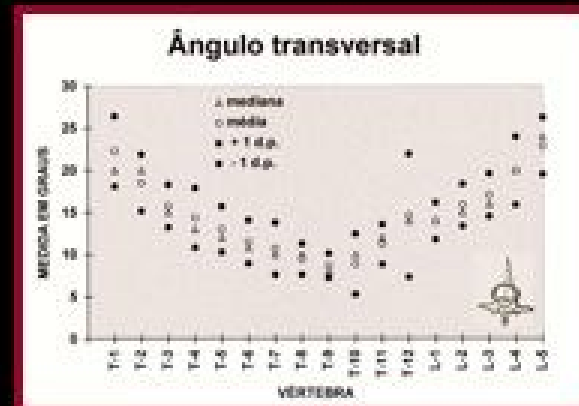
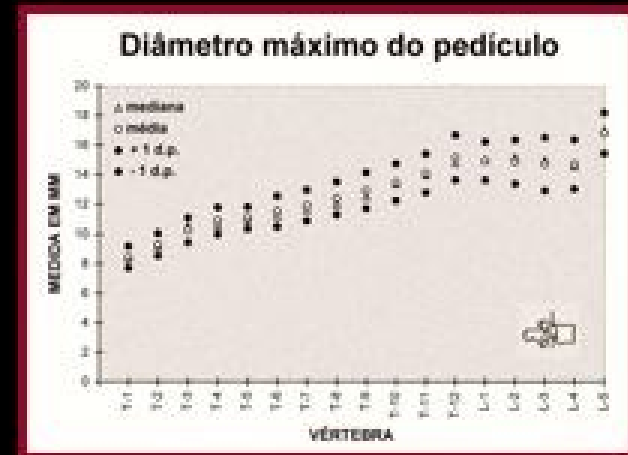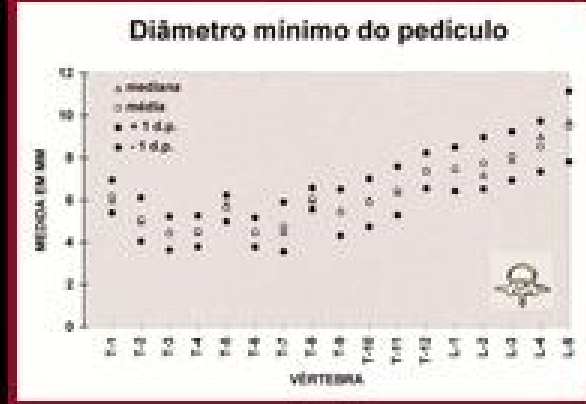
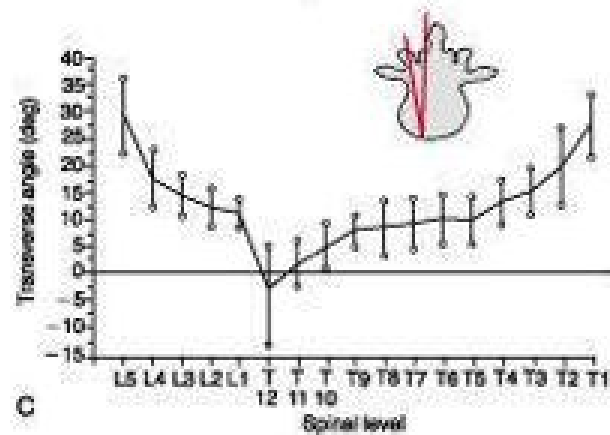
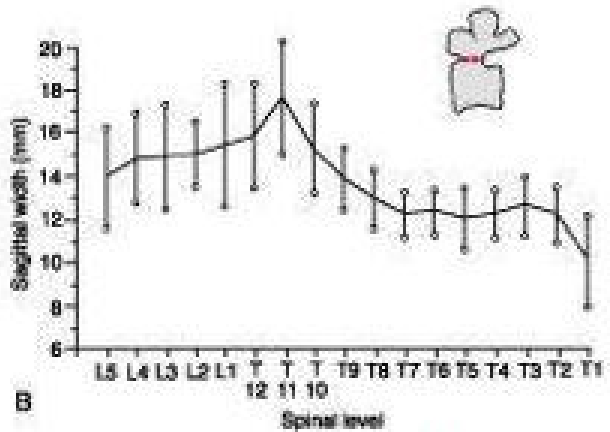
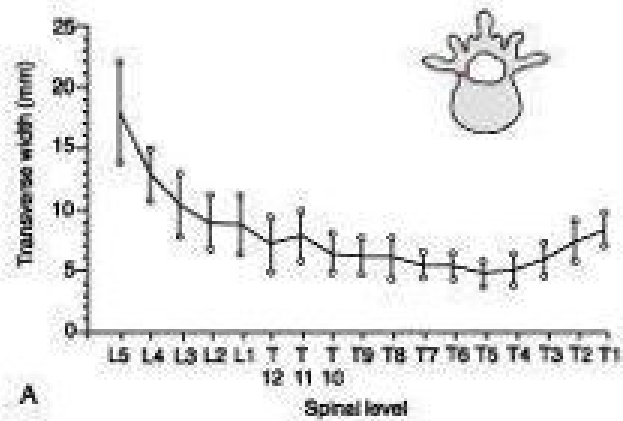


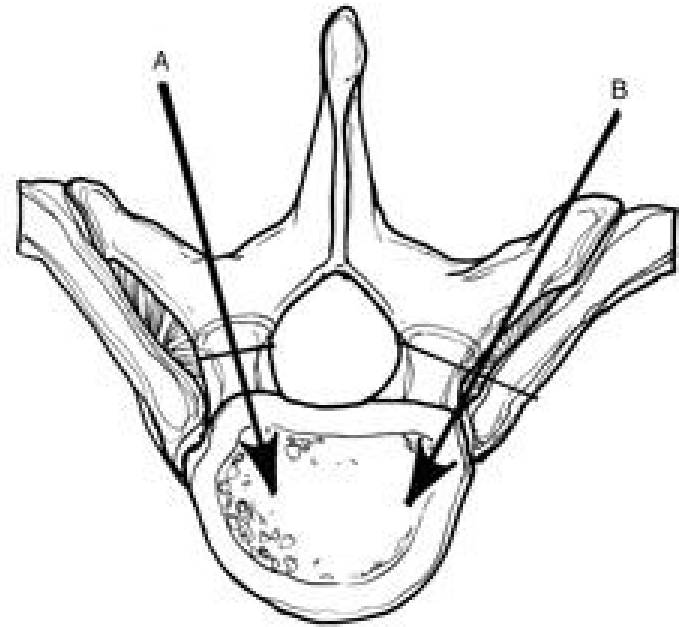
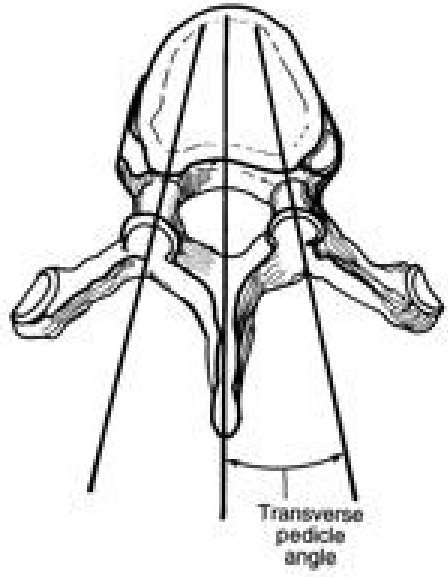
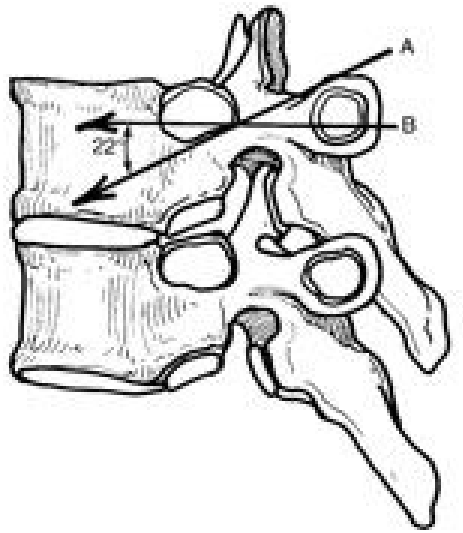
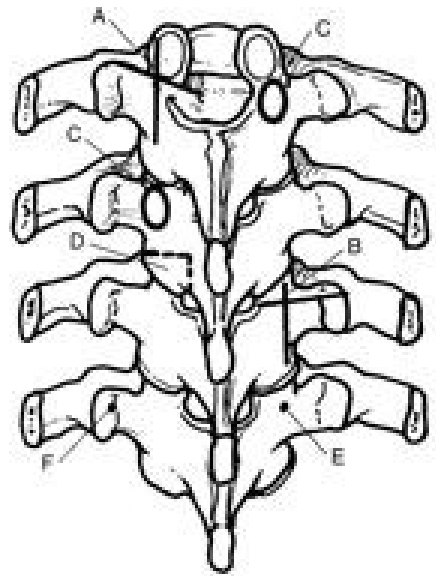
Comprimento do pedículo



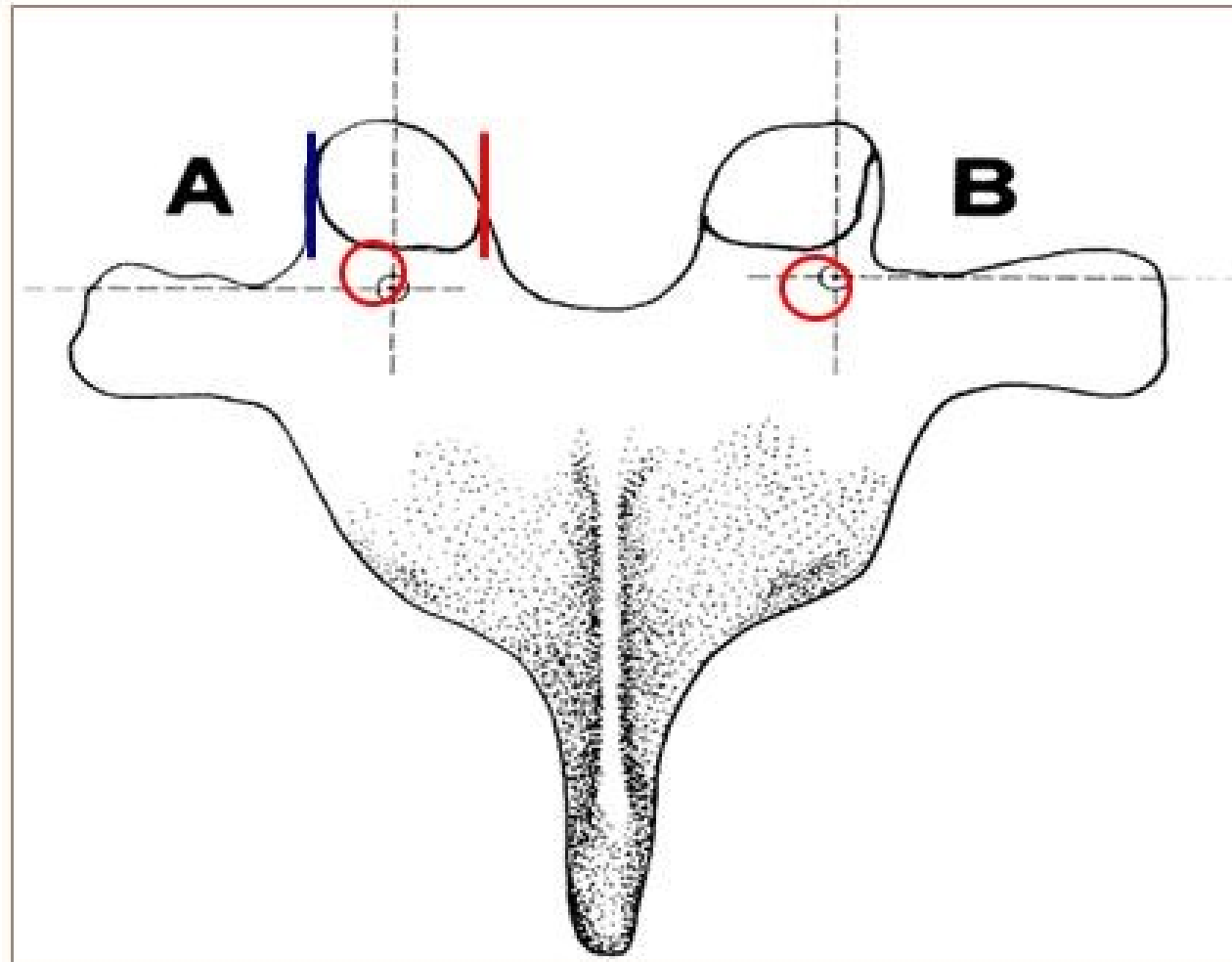
Comprimento eixo - pedículo

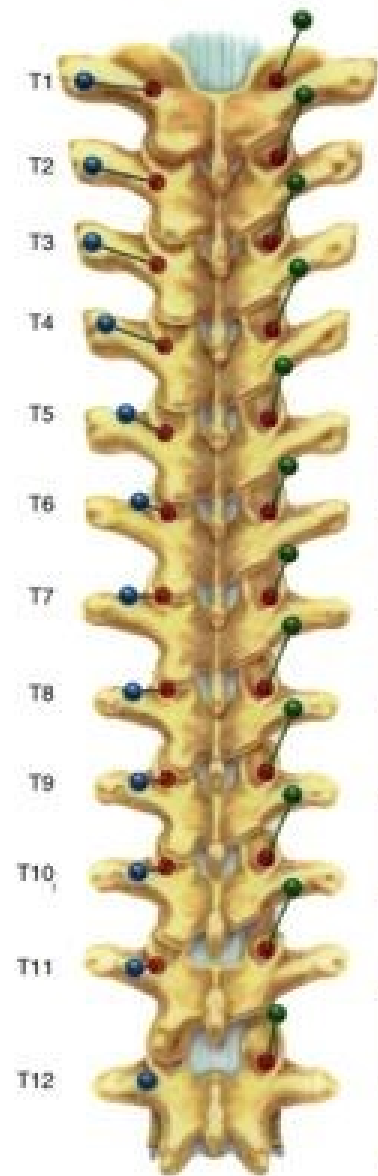




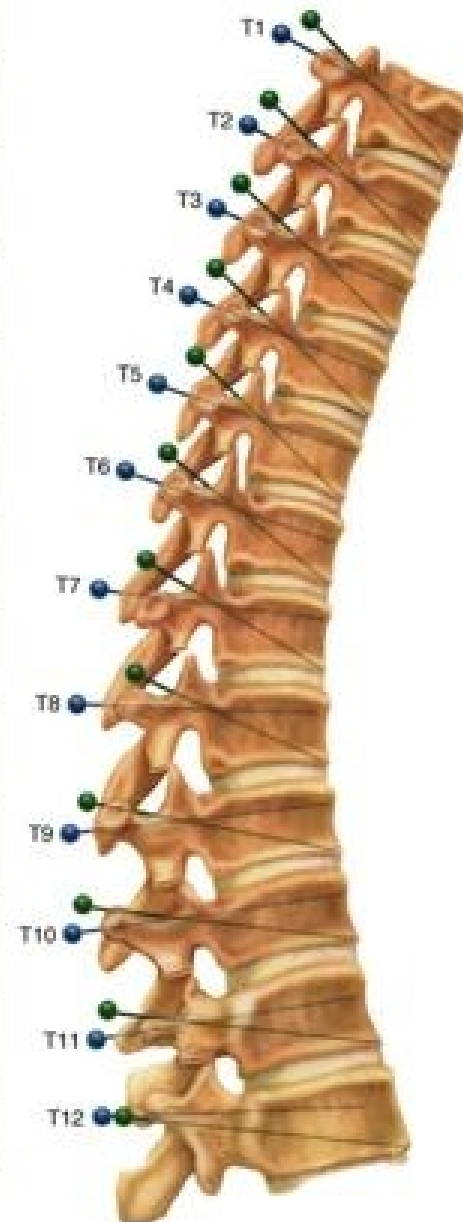


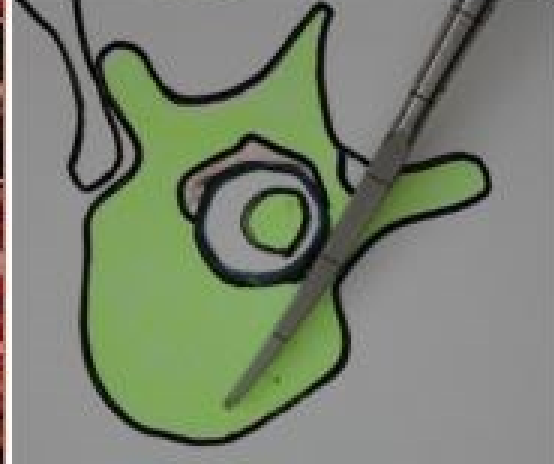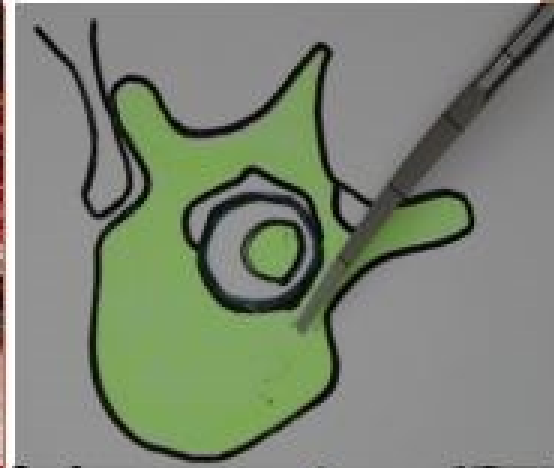
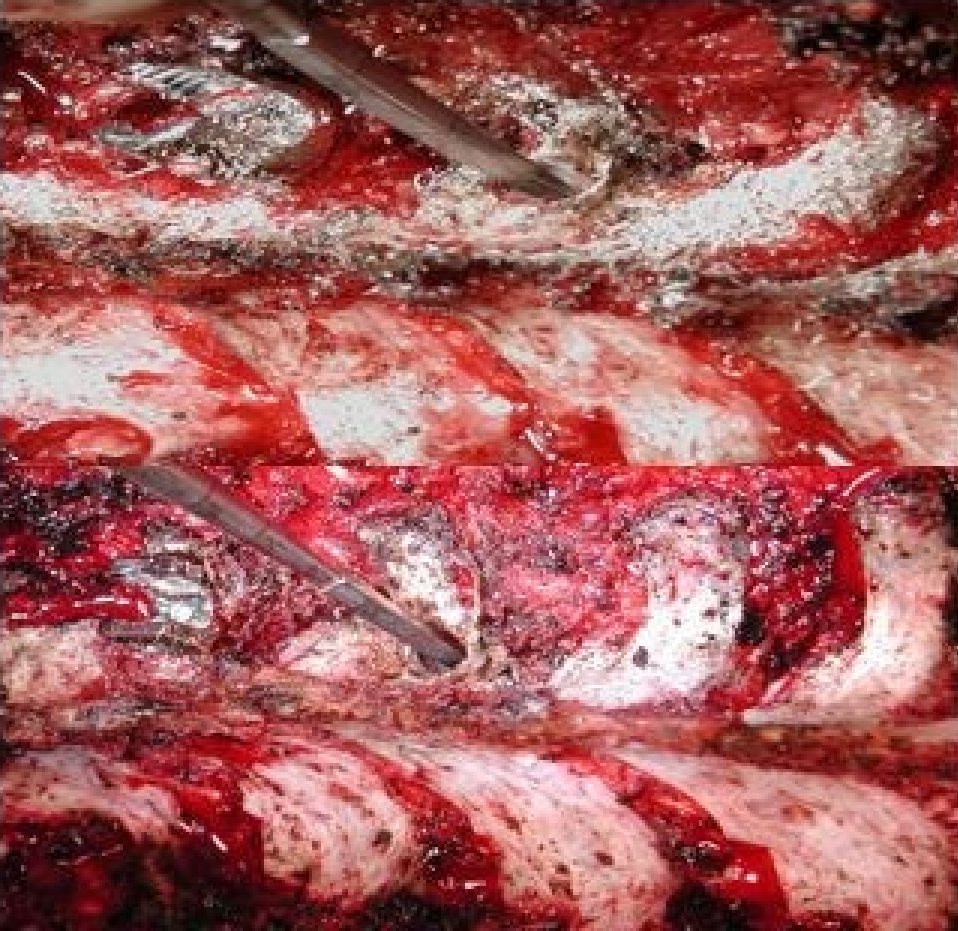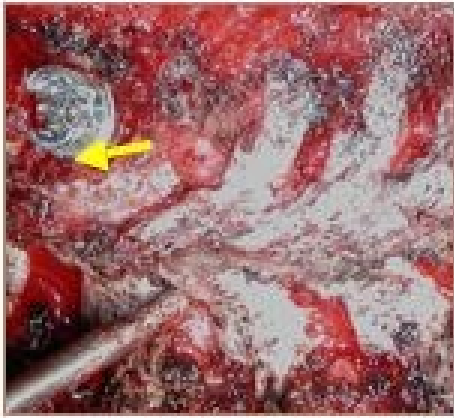
Ponto de Entrada



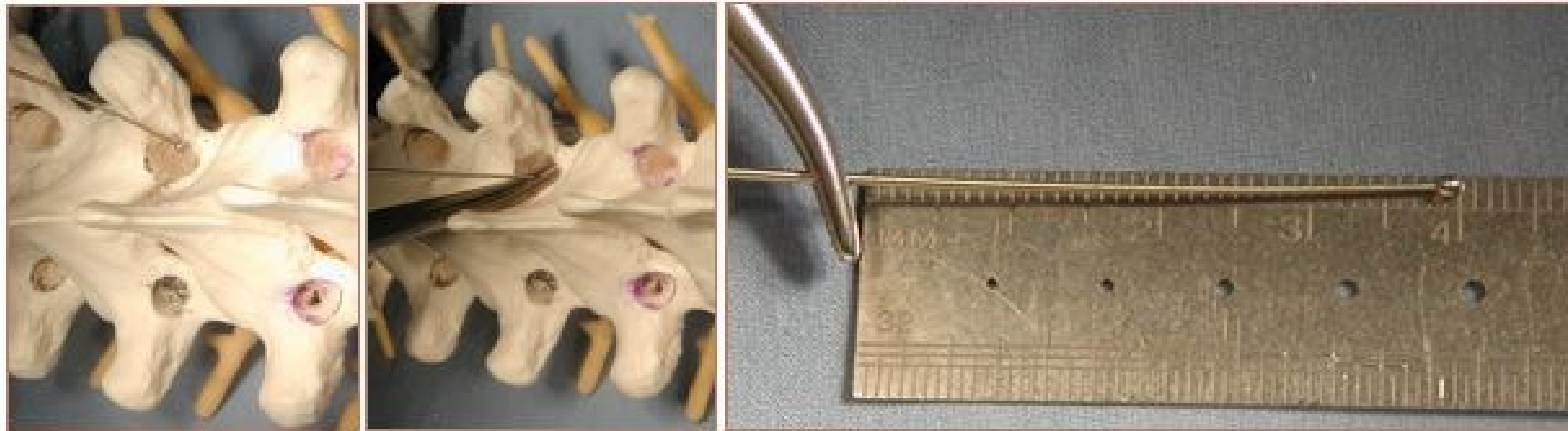

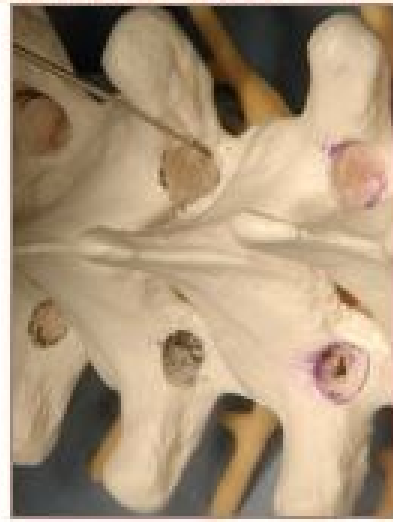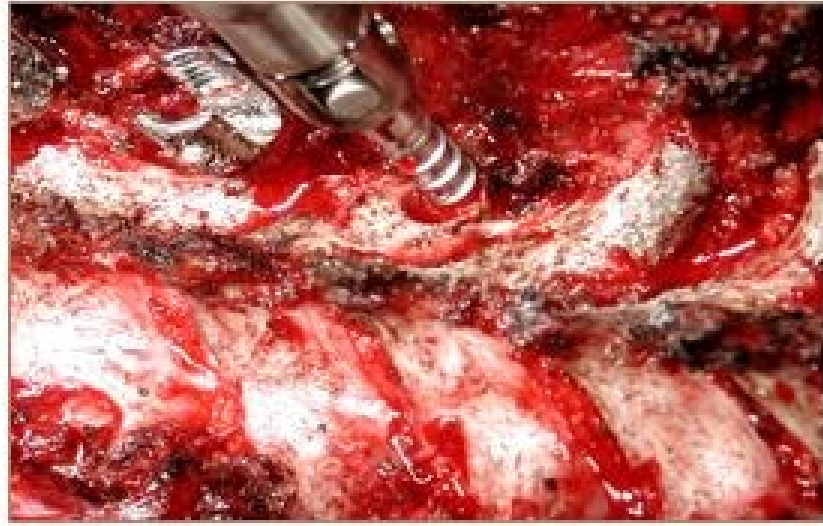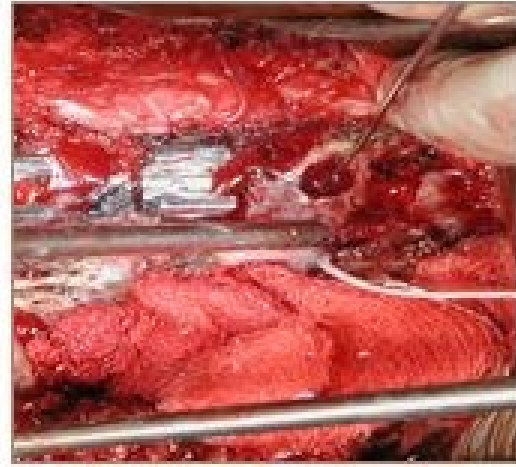
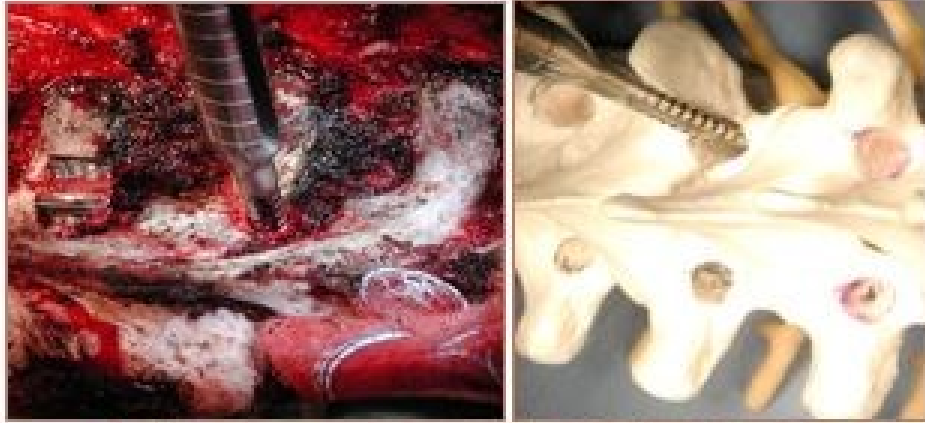
Level	Cephalad-caudad starting point	Medial-lateral starting point
T1	Midpoint TP	Junction: TP-lamina
T2	Midpoint TP	Junction: TP-lamina
T3	Midpoint TP	Junction: TP-lamina
T4	Junction: proximal third-midpoint TP	Junction: TP-lamina
T5	Proximal third TP	Junction: TP-lamina
T6	Junction: proximal edge-proximal third TP	Junction: TP-lamina-facet
T7	Proximal TP	Midpoint facet
T8	Proximal TP	Midpoint facet
T9	Proximal TP	Midpoint facet
T10	Junction: proximal edge-proximal third TP	Junction: TP-lamina-facet
T11	Proximal third TP	Just medial to lateral parts
T12	Midpoint TP	At the level of lateral parts

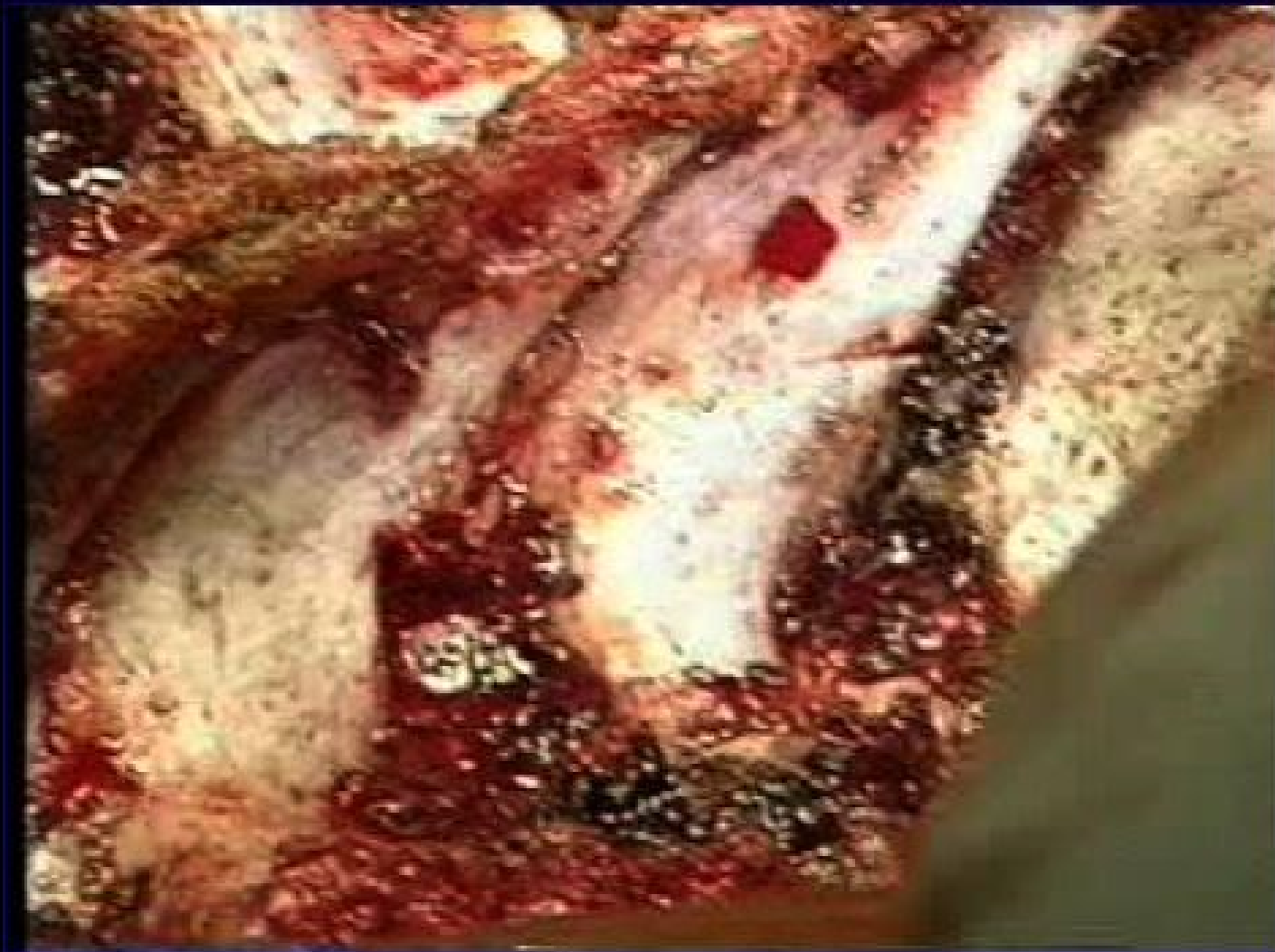


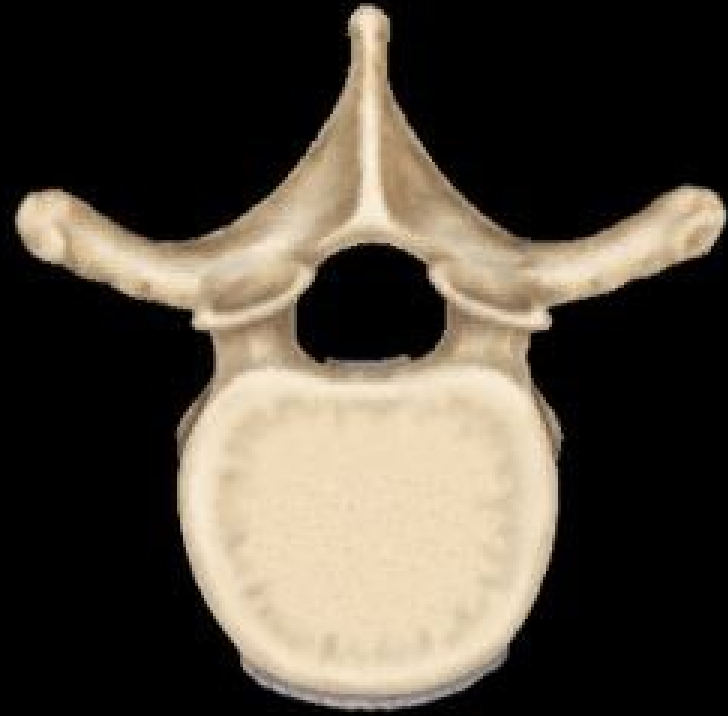
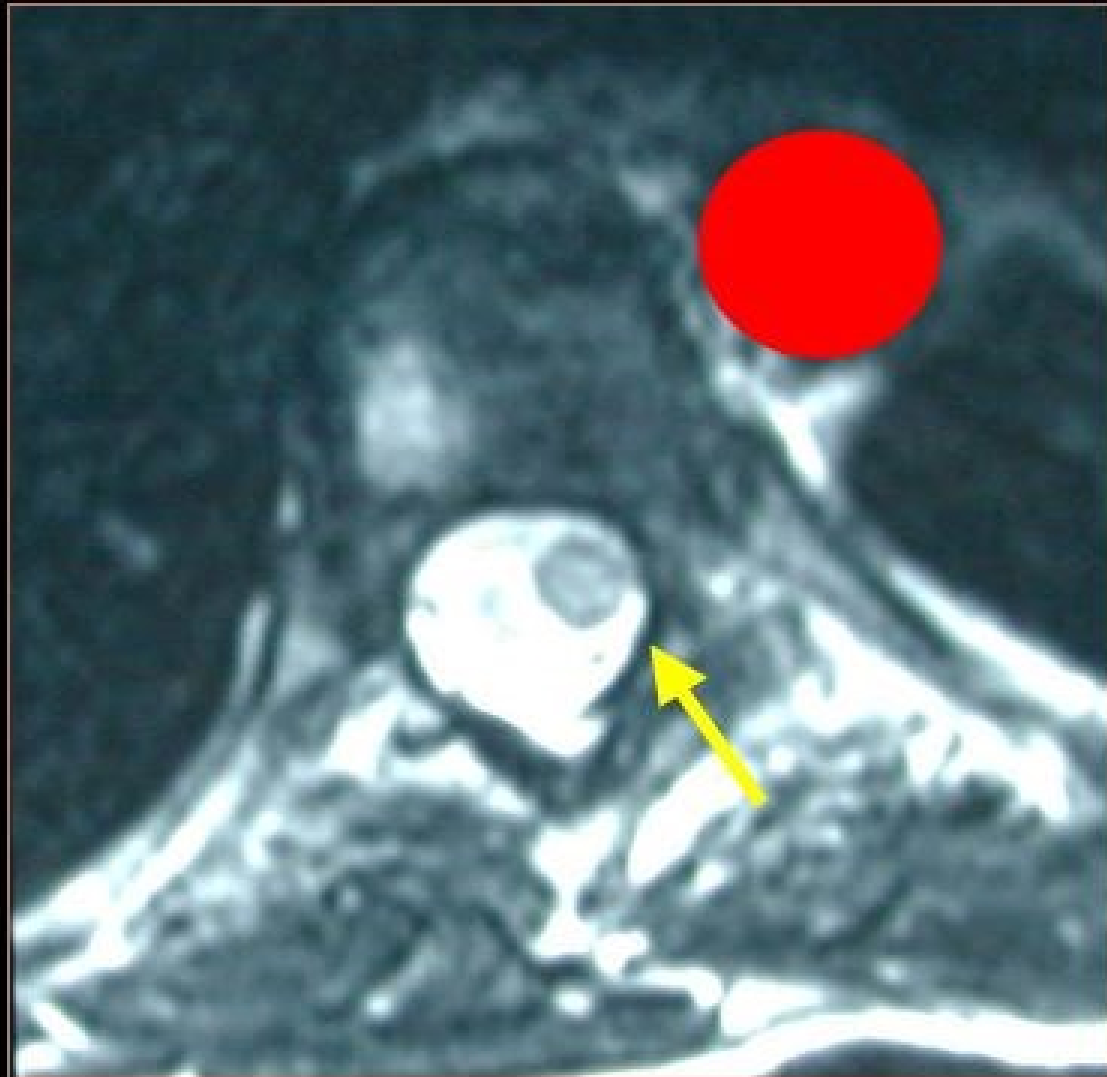
Palpação da Parede do Pedículo e Comprimento

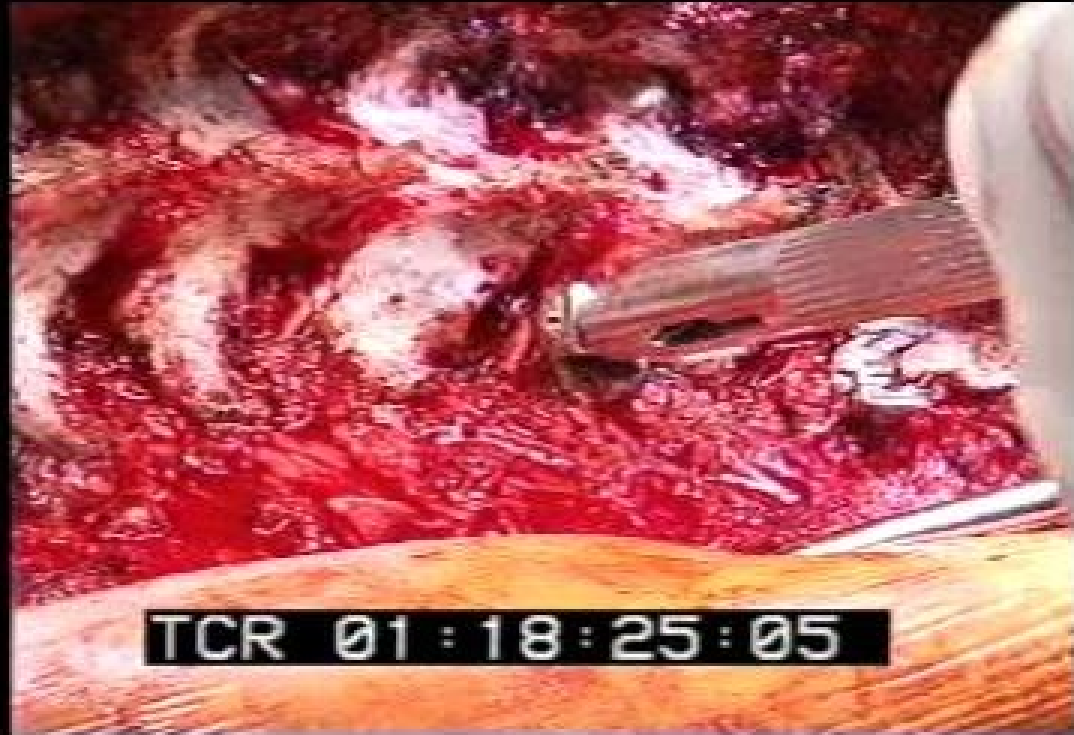

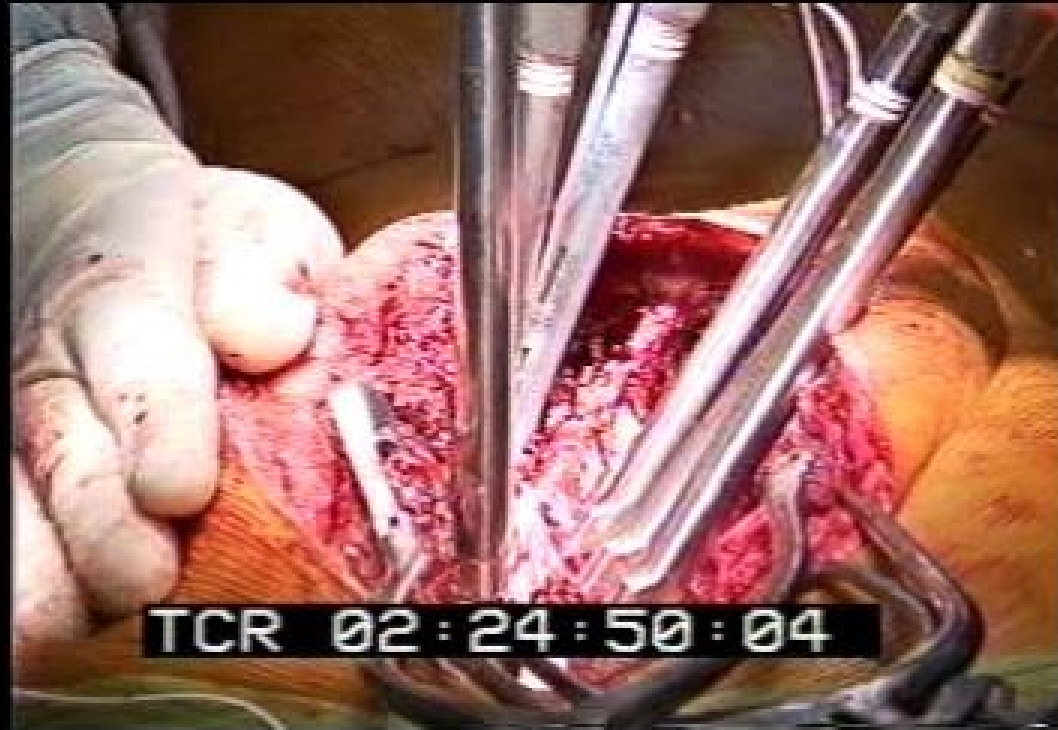




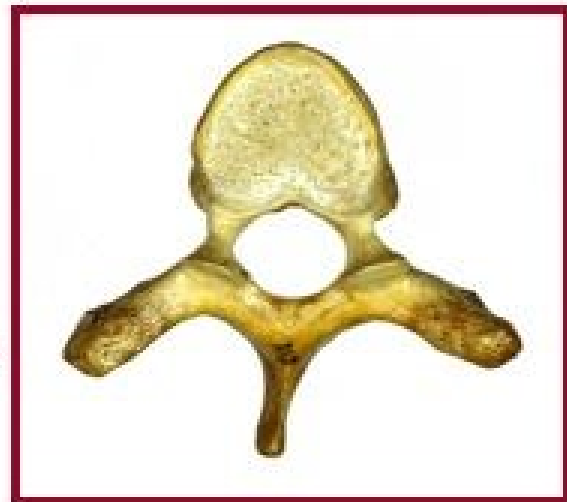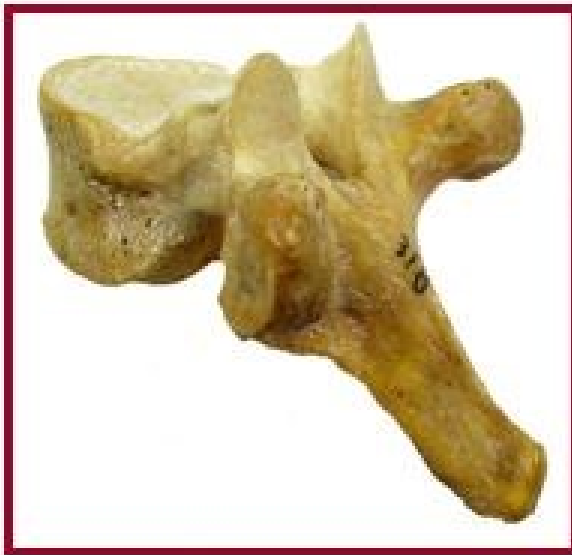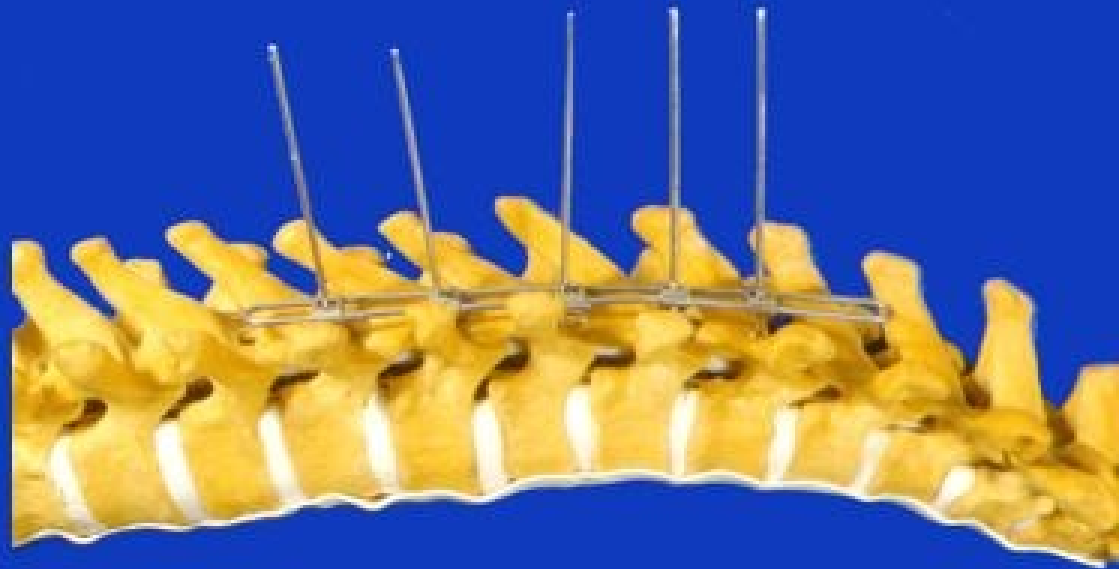



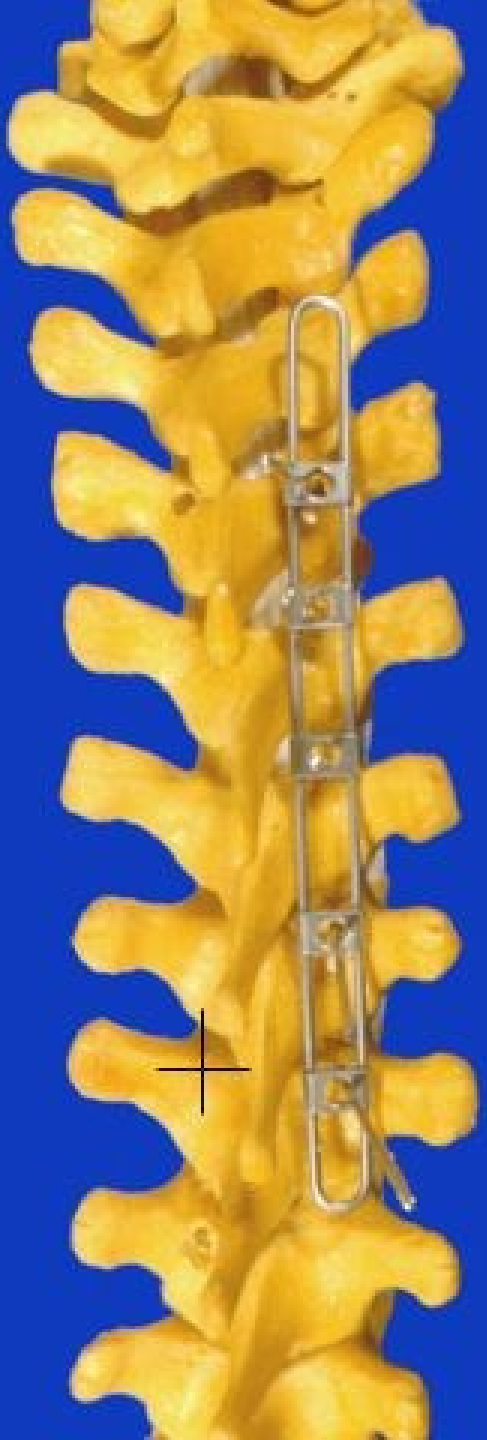








Conclusões